

Case Report

15 cm long impacted chewing wood stick in stomach: Endoscopic removal

Surender Sultania, Vidhyadhar Singh Nitar, Sandeep Nijhawan, Gaurav Gupta

Department of Gastroenterology, SMS Medical College, Jaipur, Rajasthan, India

Abstract

We report a case of long rigid radiolucent foreign body “chewing wood stick (datun)” impacted in the stomach of a 50-year-old man. He was literate, without any history of psychiatric illness and had been using “datun” to clean his teeth for last 15 years. He presented with a history of accidental ingestion of “datun” 3 months back, it was found impacted in the stomach on percutaneous ultrasonography and was removed with endoscopy using rat tooth forceps and snare.

Key words

Chewing wood stick, endoscopy, foreign body

Introduction

In adults, true foreign body ingestion (i.e., nonfood objects) occurs commonly in those with history of psychiatric disorders, developmental delay, alcohol intoxication and in incarcerated individuals seeking secondary gain through release to a medical facility.^[1-3] Edentulous adults are also at greater risk of ingesting foreign bodies, including an obstructing food bolus or their dental prosthesis.^[4] We hereby report a patient with radiolucent chewing wood stick (datun) inside stomach in a literate person without any psychiatric disease. It is rare to find “datun” as a foreign body. According to our knowledge, till now only two cases are reported one was extracted with endoscope^[5] and the other was treated by surgical intervention.^[6]

Case Report

A 50-year-old healthy man presented with complaint of pain in epigastric region for 15 days with history of accidental ingestion of “datun” 3 months back while cleaning his teeth.

Address for correspondence:

Dr. Surender Sultania, F-2, Plot No Kha-30, Shubh Mangal Apartment, Bhawani Nagar, Jaipur - 302 023, Rajasthan, India.
E-mail: dr.surendersultania@gmail.com

Access this article online

Website:

www.jdeonline.in

DOI:

10.4103/0976-5042.195765

Quick Response Code



General physical and abdominal examination was normal. He was carrying percutaneous ultrasonography abdomen report, showing a long echogenic structure in the stomach, one end of which appeared embedded in the stomach wall, suggestive of long foreign body [Figure 1]. An erect abdominal radiograph ruled out perforation. Due to financial constraint contrast enhanced computed tomography of abdomen was not done. Upper gastrointestinal endoscopy was performed after getting informed consent that revealed long wooden foreign body, one end of which was in the antrum and another end was embedded in wall of body of the stomach [Figure 2]. Wire loop of snare was put around the distal end of “datun”, as proximal end was impacted, but we could not disimpact it. Then with the help of Rat tooth forceps proximal end was disimpacted and “datun” was extracted by holding the tip of proximal end by rat tooth forceps. There was no complication following the procedure, contrast study of the stomach was not done because the patient did not give consent for any further investigations and he was discharged after 1 day of observation.

Discussion

Foreign body ingestion is a common problem encountered in emergency department. Management of foreign body

This is an open access article distributed under the terms of the Creative Commons Attribution-NonCommercial-ShareAlike 3.0 License, which allows others to remix, tweak, and build upon the work non-commercially, as long as the author is credited and the new creations are licensed under the identical terms.

For reprints contact: reprints@medknow.com

How to cite this article: Sultania S, Nitar VS, Nijhawan S, Gupta G. 15 cm long impacted chewing wood stick in stomach: Endoscopic removal. J Dig Endosc 2016;7:148-9.

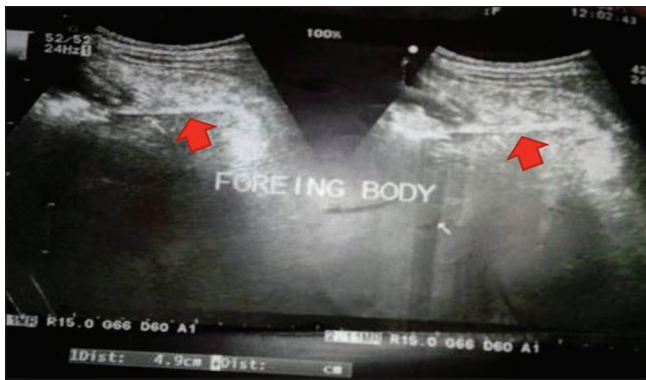

Figure 1: Ultrasonography upper abdomen - red arrows showing datun (wooden chewing stick) in stomach

depends on its chemical property, size, location, and sharpness. Ingestion of long foreign body is not common but not rare. Long foreign body may get impacted at three anatomical narrowings of esophagus and stomach, and it may lead to perforation. Due to its fixed retroperitoneal position of duodenum foreign body >5 cm in length and >2.5 cm in diameter has difficulty in passage through it.^[7]

X-ray of the chest and abdomen are the first investigations for a patient presenting with suspected foreign body ingestion, but fish or chicken bones, wood, plastic, glass, and thin metal objects are not readily seen on X-ray, as happened in our case. Computed tomography may be useful to detect foreign body and complications not seen on other modality.^[8] Stomach foreign body can be detected on percutaneous ultrasonography as was in our case. Diagnostic endoscopy is the most precise means to diagnose suspected foreign bodies within the reach of the endoscope.

During the endoscopic removal of any long object, the long axis should be aligned with the axis of the lumen and the endoscope. If alignment is not achieved as the object is withdrawn towards the cardioesophageal junction, the object will either penetrate the mucosa, or the grip will be lost.^[9] Foreign body forceps and polypectomy snare are the most commonly used devices to secure and remove long objects. “Datun” is a wooden stick which is taken fresh from the branch of a tree called Neem (*Azadirachta indica*) and used to clean teeth all over India.^[10] Neem has medicinal value in dental care.^[10] Previously only two cases are reported in the literature of “datun” as a foreign body and one was removed with help of an endoscope.^[5] In our case, “datun” was found in the stomach and it was embedded in the stomach wall, on clinical examination and investigations there was no suggestion of perforation and foreign body was there for 3 months, so we extracted it using endoscope and accessories. In this case, snare did not work because of its floppy shaft which did not transmit force to the impacted end of “datun”. Then “datun” was caught near the impacted end by rat tooth forceps and because of its metal shaft force could be transmitted during disimpaction. This present case did not develop any signs and

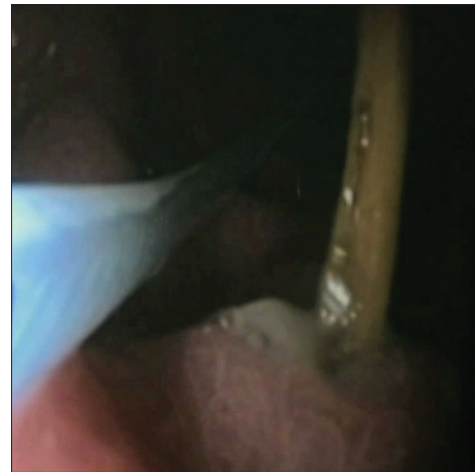


Figure 2: Datun (wooden chewing stick) seen impacted in stomach

symptoms of perforation after the removal of foreign body possibly because of sealing of perforation due to chronic inflammatory tissue. In conclusion long “datun” impaction in the stomach is rare, it can be diagnosed on percutaneous ultrasonography and can be retrieved with rat tooth forceps safely without risk of perforation.

Financial support and sponsorship

Nil.

Conflicts of interest

There are no conflicts of interest.

References

1. Palta R, Sahota A, Bemarki A, Salama P, Simpson N, Laine L. Foreign-body ingestion: Characteristics and outcomes in a lower socioeconomic population with predominantly intentional ingestion. *Gastrointest Endosc* 2009;69(3 Pt 1):426-33.
2. Weiland ST, Schurr MJ. Conservative management of ingested foreign bodies. *J Gastrointest Surg* 2002;6:496-500.
3. Webb WA. Management of foreign bodies of the upper gastrointestinal tract: Update. *Gastrointest Endosc* 1995;41:39-51.
4. Abdullah BJ, Teong LK, Mahadevan J, Jalaludin A. Dental prosthesis ingested and impacted in the esophagus and orolaryngopharynx. *J Otolaryngol* 1998;27:190-4.
5. Singhal SK, Arora V, Dass A. An unusual foreign body of esophagus. *Online J Health Allied Sci* 2010;9:14.
6. Pandya VK, Malik R, Lakhole M. Rigid 12 inches long impacted foreign body in upper gastro-intestinal-tract. *Indian J Radiol Imaging* 2006;16:495-7.
7. ASGE Standards of Practice Committee, Ikenberry SO, Jue TL, Anderson MA, Appalaneni V, Banerjee S, et al. Management of ingested foreign bodies and food impactions. *Gastrointest Endosc* 2011;73:1085-91.
8. Silva RG, Ahluwalia JP. Asymptomatic esophageal perforation after foreign body ingestion. *Gastrointest Endosc* 2005;61:615-9.
9. Yong PT, Teh CH, Look M, Wee SB, Tan JC, Chew SP, et al. Removal of a dinner fork from the stomach by double-snare endoscopic extraction. *Hong Kong Med J* 2000;6:319-21.
10. Lakshmi T, Krishnan V, Rajendran R, Madhusudhanan N. *Azadirachta indica*: A herbal panacea in dentistry – An update. *Pharmacogn Rev* 2015;9:41-4.