

Case Report

Removal of a partially covered stent by endoscopic substent dissection

Iyad Khamaysi, Alain Suissa, Ian M. Gralnek

Department of Gastroenterology and Hepatology, Rambam Health Care Campus, Rappaport Faculty of Medicine, Technion-Israel Institute of Technology, Haifa, Israel

Abstract

Herein we describe a new technical endoscopic removal of embedded partially covered esophageal stent that was inserted to treat a iatrogenic perforation of esophagus. Usually, partially covered stents can be removed by the stent-in-stent technique. In this case, the embedded stent could not be removed safely with this technique; so we performed a sub stent dissection to detach the stent from the esophageal wall.

Key words

Dissection, esophagus, perforation, stent

Introduction

An 81-year-old female suffering from progressive dysphagia underwent gastroscopy which showed a mid-esophageal stricture. Attempts at passing the endoscope through the stricture caused an esophageal perforation. The patient was transferred to our medical center for further evaluation and treatment. Upon arrival, a computed tomography (CT) scan of the chest showed a massive pneumomediastinum. Due to her comorbidities, conservative, supportive management was chosen; however, her medical condition deteriorated and the second chest CT scan now showed a mediastinal fluid collection and bilateral empyema [Figure 1]. Percutaneous drainage of the fluid collection proved to be inadequate and endoscopic therapy was attempted.

In the mid-esophagus (25 cm from the incisors), adjacent to a tight stricture (2–3 mm opening leading to the distal

esophagus), an esophagomediastinal fistula (15 mm wide) was noted leading to the mediastinal fluid collection seen on CT [Figure 2]. A copious amount of turbid fluid was suctioned from the collection, and a fully covered, through the scope, esophageal stent (Niti-S, Taewoong, 20 × 100 mm) was inserted through the esophageal stricture. One-week later, the stent migrated distally to the stomach (shown by chest X-ray) and was removed endoscopically [Figure 3]. A partially covered esophageal stent (Ultraflex, Boston Scientific, 20 × 100 mm) was then inserted.

Biopsies from the stricture were negative for malignancy.

The patient's medical situation gradually improved and she started oral intake. Resolution of the mediastinal fluid collection was demonstrated on follow-up CT scan.

Six weeks later, an initial attempt to remove the partially covered esophageal stent was performed. Both uncovered flanges of the stent were completely embedded by extensive, ingrowth and overgrowth of hyperplastic tissue. Using the

Address for correspondence:

Dr. Iyad Khamaysi, Department of Gastroenterology and Hepatology, Rambam Health Care Campus, Rappaport Faculty of Medicine, Technion-Israel Institute of Technology, POB 9602, Haifa 31096, Israel.
E-mail: k_iyad@rambam.health.gov.il

Access this article online

Website:

www.jdeonline.in

DOI:

10.4103/0976-5042.193744

Quick Response Code



This is an open access article distributed under the terms of the Creative Commons Attribution-NonCommercial-ShareAlike 3.0 License, which allows others to remix, tweak, and build upon the work non-commercially, as long as the author is credited and the new creations are licensed under the identical terms.

For reprints contact: reprints@medknow.com

How to cite this article: Khamaysi I, Suissa A, Gralnek IM. Removal of a partially covered stent by endoscopic substent dissection. *J Dig Endosc* 2016;7:120-2.

stent-in-stent technique, another fully covered stent (SX-Ella stent HV, 20 × 120 mm) was inserted within the partially covered stent [Figure 4].

Two-week later, the fully covered stent was removed easily but the partially covered stent remained embedded, particularly at the distal flange.

The proximal flange was detached from the esophageal wall using foreign body forceps and the tip of the therapeutic gastroscopy was carefully advanced in the substent space (the space between the esophageal wall and the stent) [Figure 5]. Multiple gentle circumferential dilatation (dissection) maneuvers were applied in order to slowly and gently detach the stent from the esophageal wall. Finally, the gastroscopy was successfully advanced into

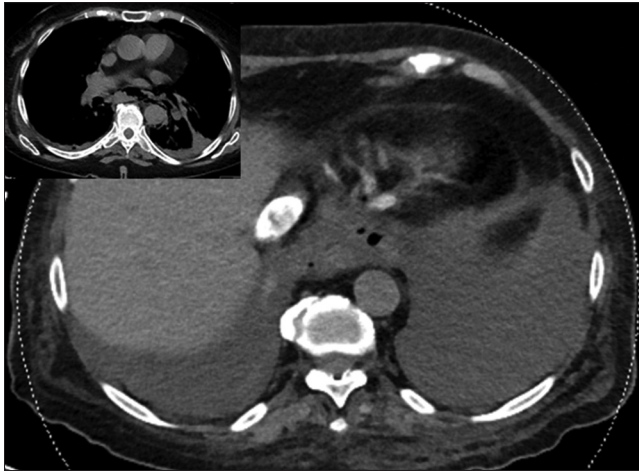

Figure 1: Pneumomediastinum, mediastinal fluid collection, and bilateral emphysema

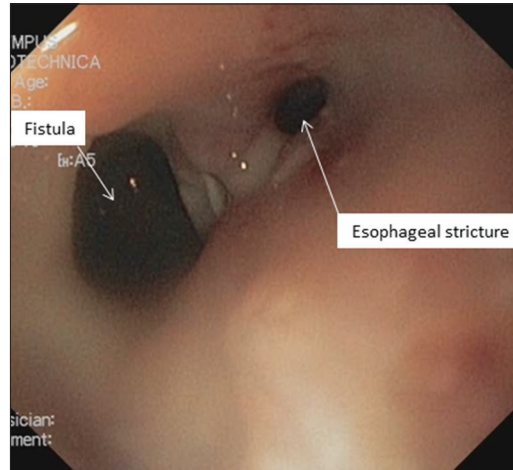


Figure 2: Esophagomediastinal fistula, mid-esophageal stricture

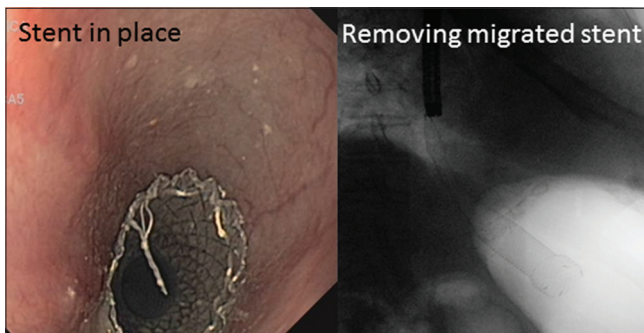


Figure 3: Migrated esophageal Niti-S stent removed endoscopically

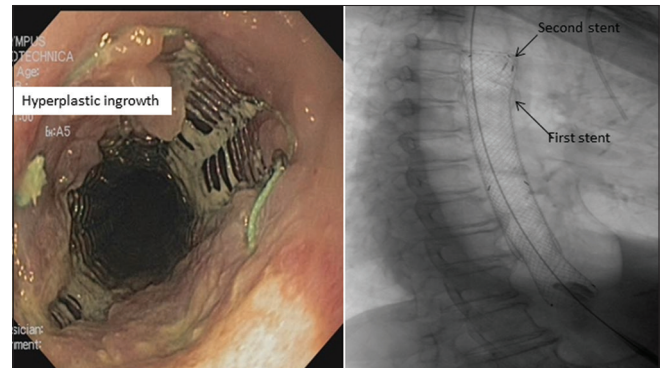


Figure 4: Hyperplastic tissue ingrowth, stent-in-stent insertion

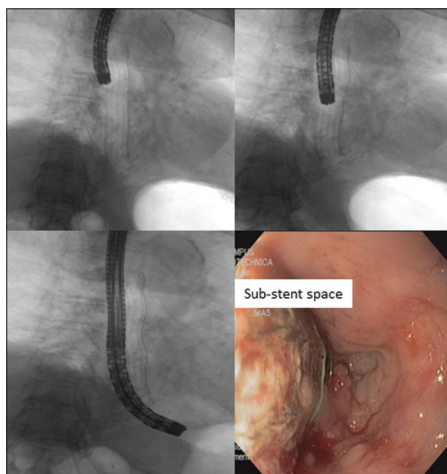


Figure 5: Advancing the endoscope within the substent space

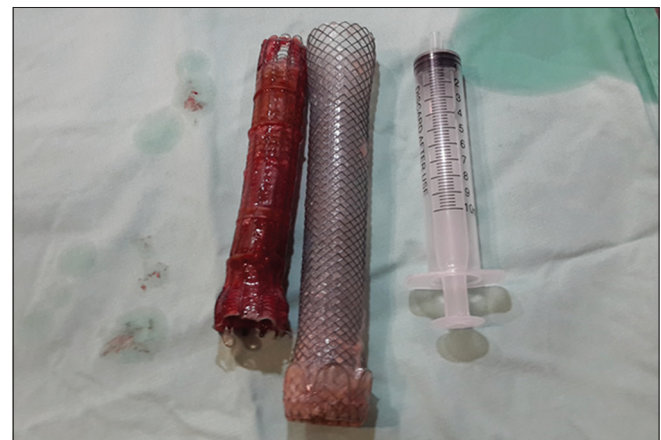

Figure 6: Two stents removed

the proximal stomach, completely separating the stent from the esophageal wall, and allowing uneventful stent removal [Figure 6]. Careful inspection of the esophagus demonstrated complete closure of the fistula and adequate dilatation of the stricture. The patient was discharged home the following day.

Financial support and sponsorship

Nil.

Conflicts of interest

There are no conflicts of interest.