

# Giant fibrovascular polyp of esophagus

Ramakanth Sannidi, Shraavan Kumar Porika, Umadevi Malladi, Ramanna Macherla

Department of Gastroenterology, Gandhi Medical College and Hospital, Secunderabad, Telangana, India

## Abstract

Benign tumors of esophagus are uncommon and account for only 3% of all esophageal neoplasms. Fibrovascular polyps (FVP) are rare intraluminal tumors of esophagus. They are composed of fibrous tissue, vascular structures and covered with normal Squamous epithelium. Here we present a case of a 45 yr old gentleman with progressive dysphagia since 3 months. UGI endoscopy showed a long, linear, compressible mass extending from cricoid area to gastro-esophageal junction (GEJ). Patient was operated, through cervical incision esophagectomy done and polyp of size 16 × 7 cm was removed. Histopathology of polyp was suggestive of fibrovascular polyp. Post surgery patient was asymptomatic and doing well.

## Key words

Asphyxia, dysphagia, fibrovascular polyp

## Introduction

Giant fibrovascular polyp (GFVP) of esophagus is a rare, intraluminal benign tumor, contains various degrees of fibrosis, vascular, and adipose tissue with normal overlying mucosa. GFVP often present with dysphagia and long pedunculated lesions can regurgitate into pharynx or mouth and can cause death from asphyxia if larynx is occluded. Here, we discuss a 45-year-old man with FVP causing severe dysphagia.

## Case Report

A 45-year-old male presented with dysphagia of 3 months duration. Dysphagia was more to solids than liquids and progressed for 1 month. No history of a cough or choking episodes or nasal regurgitation, no history of loss of appetite and weight, no significant family history, and no addictions. Clinical examination was normal.


Barium swallow showed dilated esophagus with long linear intraluminal filling defect involving entire length of esophagus. Upper gastrointestinal endoscopy showed a long, linear, lobular, firm, noncompressible mass extending from cricoid with thick pedicle extending up to 2 cm above gastroesophageal junction (GEJ) with surface ulceration in the lower region, covered with exudates [Figure 1]. Endoscopic ultrasound revealed a solid mixed echogenic lesion in the lumen of esophagus with little vascularity.

Computed tomography (CT) chest with oral and intravenous contrast demonstrated a single soft tissue density lesion extending from cricoid region up to GEJ, with oral contrast surrounding the lesions [Figure 1]. This patient underwent surgery through cervical incision esophagectomy and surgical extirpation of the entire polyp, which measured 16 × 7 cm was done [Figure 2], and transhiatal gastric pull through and cervical esophagus-gastric anastomosis was done. Histopathology of the polyp revealed a mixture of adipose tissue, fibrovascular tissue lined by stratified squamous epithelium with ulceration of focal areas, and confirming the diagnosis of FVP [Figure 2]. On follow-up of after 3 months, the patient is doing well and symptom-free.

### Address for correspondence:

Dr. Ramakanth Sannidi, # Flat No. 402, HIG Plot No. 5, HUDA Colony, Chandanagar, Hyderabad - 500 050, Telangana, India.  
E-mail: ramaakanth145@gmail.com

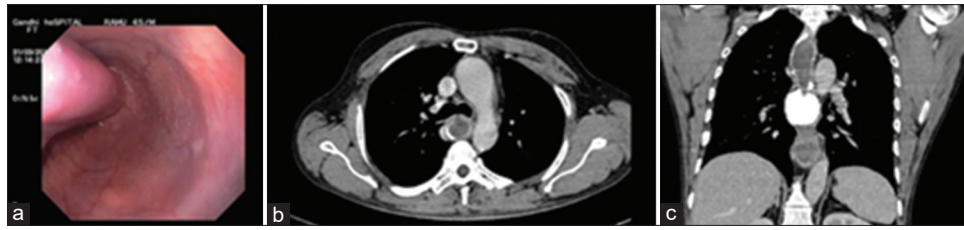
### Access this article online

<b>Website:</b> www.jdeonline.in	<b>Quick Response Code</b> 
<b>DOI:</b> 10.4103/0976-5042.193741	

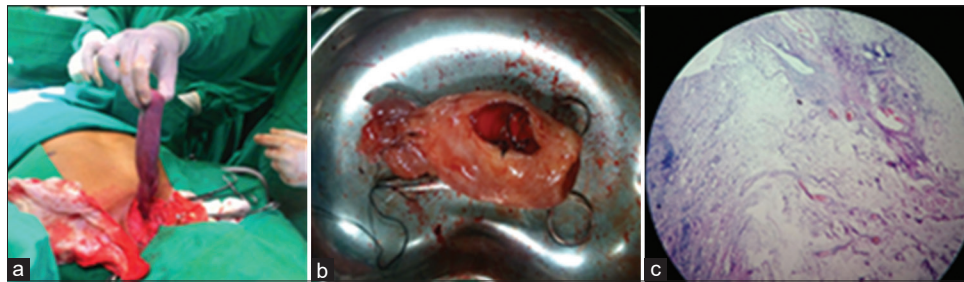This is an open access article distributed under the terms of the Creative Commons Attribution-NonCommercial-ShareAlike 3.0 License, which allows others to remix, tweak, and build upon the work non-commercially, as long as the author is credited and the new creations are licensed under the identical terms.

For reprints contact: reprints@medknow.com

**How to cite this article:** Sannidi R, Porika SK, Malladi U, Macherla R. Giant fibrovascular polyp of esophagus. J Dig Endosc 2016;7:112-4.



**Figure 1:** (a) Upper gastrointestinal endoscopy showing long, linear growth in esophagus. (b) Contrast-enhanced computed tomography chest with oral and intravenous contrast, transverse section showing intraluminal mass in esophagus surrounded by oral contrast. (c) Contrast-enhanced computed tomography chest with oral and intravenous contrast coronal section showing intraluminal mass in esophagus



**Figure 2:** (a) Image of the polypoid lesion extracted through cervical incision. (b) Gross image of polyp after excision measuring 15 × 7 cm. (c) Histopathology of polyp showing fibrous tissue, vascular structures with normal stratified squamous epithelium

## Discussion

FVPs of the esophagus are rare benign tumors, comprising about 1% of all benign esophageal tumors; however, they are the most common intraluminal benign tumors of the esophagus.<sup>[1]</sup> GFVPs are defined as polyps larger than 5 cm in maximum diameter. To date, there are just over 100 reported cases in the literature, and the largest single series consisted of 16 patients.<sup>[2,3]</sup>

The site of origin of the FVP within the esophagus is thought to be from the Laimer-Haeckemann area (or Laimer's triangle) an area between inferior cricopharyngeus muscle and the proximal end of the esophagus, which is a region of relative muscular deficiency just inferior to the cricopharyngeus.<sup>[4]</sup> These polyps are thought to originate from the loose and redundant submucosal tissue near the Laimer's triangle. This relatively mobile tissue due to the lack of muscular support, through years of esophageal peristalsis traction and swallowing, is dragged along, elongated, and enlarged intraluminally.<sup>[5]</sup>

FVPs are more common in the male patients, with peak incidence in the 6<sup>th</sup> and 7<sup>th</sup> decades.<sup>[3,6]</sup> However, cases were reported in children or infants.<sup>[7,8]</sup> The most common presenting symptom is dysphagia.<sup>[2]</sup> Other associated symptoms are chest pain, regurgitation, and weight loss. Bleeding from polyp and asphyxiation are the less common but more dangerous presentations of the polyps.<sup>[9]</sup>

In the series of Levine *et al.* 16 patients with GFVP, the most common symptom was dysphagia seen in 87% of patients; respiratory symptoms in 25%, regurgitation of

the polyp into the pharynx/mouth in 12% were observed.<sup>[3]</sup> Other series presented two patients with intermittent airway obstruction.<sup>[4]</sup>

The chest X-ray usually depicts mediastinal widening and anterior bowing of the trachea.<sup>[6]</sup> Endoscopy usually reveals a soft, polypoidal, compressible mass with intact normal mucosa. Barium swallow delineates multiple intraluminal filling defects; "Forking" of the column of contrast at the origin of the FVP is considered a characteristic finding.<sup>[3]</sup> CT is the preferred modality for delineation of the of the mass with objective demonstration of the vascular and lipid contents of the FVP. The presence of fat within an intraluminal esophageal mass lesion is considered diagnostic of FVP.<sup>[10]</sup> MRI thorax with T1-weighted coronal images is also diagnostic of FVP and offers a multiplanar imaging advantage as compared to CT.<sup>[10,11]</sup>

According to the predominant histological components, the lesion was termed as lipomas, fibromas, fibrolipomas, or fibroepithelial polyps; however, they have all been grouped and classified as FVPs after the recommendations of the WHO international classification of tumors.<sup>[3,12]</sup>

The treatment is surgical, and the approaches are transoral, transthoracic, and transcervical.<sup>[6]</sup> The preferred approach is transcervical, which accesses the stalk of the polyp, which almost invariably is in the postcricoid portion of the cervical esophagus. Recurrence of the tumor following surgery is rare.<sup>[5]</sup> Endoscopic removal is not favored as the large size of the polyp restricts the ability to snare the stalk and retrieve the polyp via endoscopy.<sup>[13]</sup>

## Conclusions

Despite the benign nature of FVP of the esophagus, they can cause significant discomfort with dysphagia because of their size and location. They have life-threatening complication of asphyxia and death, awareness, and an accurate preoperative diagnosis of FVP reduces the morbidity of needless thoracotomy.

## Financial support and sponsorship

Nil.

## Conflicts of interest

There are no conflicts of interest.

## References

- Sargent RL, Hood IC. Asphyxiation caused by giant fibrovascular polyp of the esophagus. *Arch Pathol Lab Med* 2006;130:725-7.
- Caceres M, Steeb G, Wilks SM, Garrett HE Jr. Large pedunculated polyps originating in the esophagus and hypopharynx. *Ann Thorac Surg* 2006;81:393-6.
- Levine MS, Buck JL, Pantongrag-Brown L, Buetow PC, Hallman JR, Sobin LH. Fibrovascular polyps of the esophagus: Clinical, radiographic, and pathologic findings in 16 patients. *AJR Am J Roentgenol* 1996;166:781-7.
- Owens JJ, Donovan DT, Alford EL, McKechnie JC, Franklin DJ, Stewart MG, *et al.* Life-threatening presentations of fibrovascular esophageal and hypopharyngeal polyps. *Ann Otol Rhinol Laryngol* 1994;103:838-42.
- Lee SY, Chan WH, Sivanandan R, Lim DT, Wong WK. Recurrent giant fibrovascular polyp of the esophagus. *World J Gastroenterol* 2009;15:3697-700.
- Belafsky P, Amedee R, Zimmerman J. Giant fibrovascular polyp of the esophagus. *South Med J* 1999;92:428-31.
- Paik HC, Han JW, Jung EK, Bae KM, Lee YH. Fibrovascular polyp of the esophagus in infant. *Yonsei Med J* 2001;42:264-6.
- Seshul MJ, Wiatrak BJ, Galliani CA, Odrezin GT. Pharyngeal fibrovascular polyp in a child. *Ann Otol Rhinol Laryngol* 1998;107(9 Pt 1):797-800.
- Fries MR, Galindo RL, Flint PW, Abraham SC. Giant fibrovascular polyp of the esophagus. A lesion causing upper airway obstruction and syncope. *Arch Pathol Lab Med* 2003;127:485-7.
- Borges A, Bikhazi H, Wensel JP. Giant fibrovascular polyp of the oropharynx. *AJNR Am J Neuroradiol* 1999;20:1979-82.
- Ascenti G, Racchiusa S, Mazziotti S, Bottari M, Scribano E. Giant fibrovascular polyp of the esophagus: CT and MR findings. *Abdom Imaging* 1999;24:109-10.
- Watanabe H. WHO classification of esophageal and gastric tumors. 2<sup>nd</sup> ed. Berlin: Springer-Verlag; 1990. p. 16.
- Jose P, Scott N, Sarela AI. Two-stage removal of giant fibrovascular polyp of the oesophagus. *BMJ Case Rep* 2010;2010. pii: Bcr0520103011.