

# Endoscopy in a rare presentation of worms

Mallikarjun Patil, Keyur A. Sheth, Harshad Devarbhavi

Departments of Gastroenterology, St. John's Medical College, Bengaluru, Karnataka, India

## Abstract

Upper gastrointestinal bleeding can be a life threatening complication. Hookworms infestation usually causes chronic blood loss resulting in anemia. A 52 year old male presented to us with massive gastrointestinal blood loss and hemodynamic instability. On examination he had anemia, which on evaluation was iron deficient microcytic hypochromic anemia with eosinophilia. On evaluation of small bowel mucosa showed multiple hookworms moving on the surface. He improved with anthelmintics, blood transfusion and supportive management. The repeat evaluation showed eradication of worms. Hookworms presenting as a massive gastrointestinal bleeding is a rare entity. Enteroscopy plays an important role in diagnosing hookworm infestation.

## Key words

Enteroscopy, gastrointestinal bleed, hookworms

## Introduction

Upper gastrointestinal bleed can be a life-threatening complication of many diseases. However, hookworm is never considered to be the cause of massive upper gastrointestinal bleed. Hookworm infestation is very common in India. A clinical manifestation of worm infestation depends on duration of infection and burden of worms. It usually causes chronic intestinal blood loss resulting in anaemia. Endoscopy plays an important role in diagnosis of worm infestation. We present a patient with hookworm infestation and massive upper gastrointestinal bleed diagnosed on enteroscopy.

## Case Report

A 52-year-old male patient presented to us with melena for 15 days, fatigue ability for 15 days. He had no hematemesis, jaundice or ascites. There was no history of any medications or addictions. He had tachycardia with pulse rate 110/min, hypotension with 80/50 mmHg

of blood pressure and tachypnea. Physical examination revealed pallor, slightly tender abdomen and bilateral crepitations on chest. Laboratory parameters revealed haemoglobin 3.9 g/dl (normal 13-18 g/dl), total leukocyte count 4600/mm<sup>3</sup> (normal 4000-11000/mm<sup>3</sup>). Differential count (38% neutrophils, 42% lymphocytes, 15% eosinophils and 3% monocytes), absolute eosinophil count was 680 cells/mm<sup>3</sup>, absolute lymphocyte count was 1932 cells/mm<sup>3</sup> and platelets 340,000/mm<sup>3</sup> (normal 150,000-450,000/mm<sup>3</sup>). Further investigations revealed mean corpuscular volume 73.6 fl (normal 76-96 fl), mean corpuscular haemoglobin 18.8 pg (normal 27-32 pg). Peripheral smear was showing microcytic hypochromic anaemia with eosinophilia. Serum iron levels were 15 mcg/dl (normal 35-150 mcg/dl), total iron binding capacity 386 mcg/dl (normal 250-450 mcg/dl), transferrin saturation was 15% (normal 15-35%), ferritin was 14 ng/ml (normal 23.9-336.2 ng/ml). serum vitamin B12 levels were 1061 pg/ml (normal 180-914 pg/ml), and erythrocyte sedimentation rate was 12 mm/h. Liver function tests and ultrasonography of the abdomen were normal. Gastroduodenoscopy and colonoscopy were also normal. Stool routine and microscopy examination was normal for 3 consecutive days. He was transfused packed red blood cells to maintain haemoglobin around 7 g/dl (normal 13-18 g/dl). He had persistent low haemoglobin despite transfusion; hence evaluation of small bowel was done with the enteroscopy [Figures 1-4]. It showed multiple reddish worms moving in the proximal jejunum, microscopy examination confirmed hookworms that was *Necator americanus* by a pair of ventral cutting plates and fused copulatory spicules.

### Access this article online

<b>Website:</b> www.jdeonline.in	<b>Quick Response Code</b> 
<b>DOI:</b> 10.4103/0976-5042.144836	

### Address for correspondence:

Dr. Mallikarjun Patil, Department of Gastroenterology, St. John's Medical College, Bengaluru, Karnataka, India. E-mail: drmalli\_arjun@yahoo.co.in

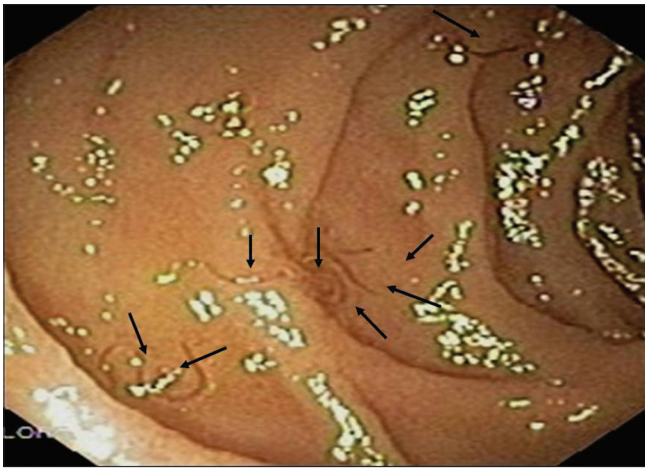


Figure 1: Enteroscopy shows multiple hookworms

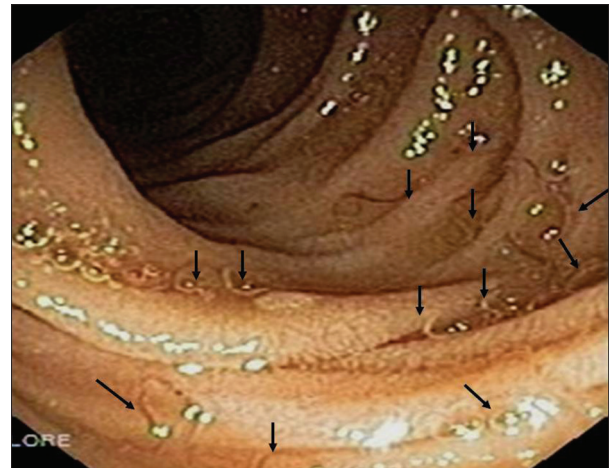


Figure 2: Enteroscopy shows multiple hookworms

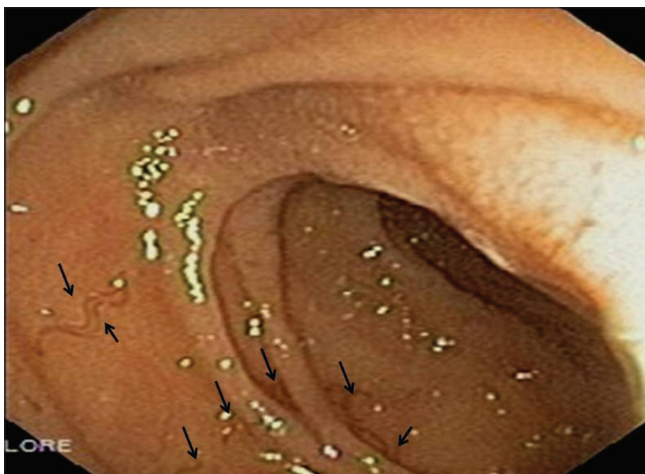


Figure 3: Enteroscopy shows multiple hookworms

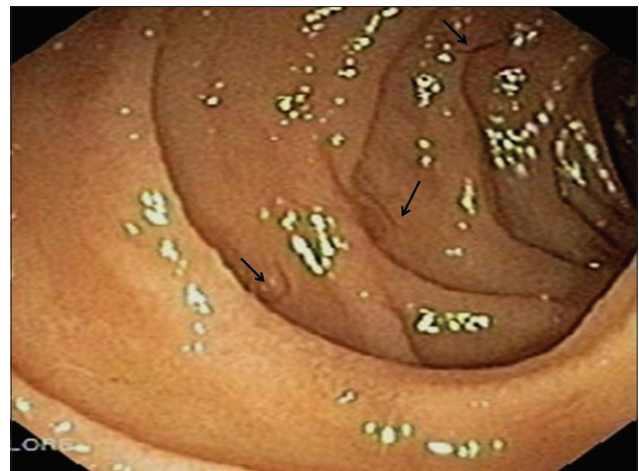


Figure 4: Enteroscopy shows multiple hookworms

Patient was treated with albendazole 400 mg 1 dose. The stool routine and microscopy examination after 1 week for 3 days showed no hookworm eggs. Stool microscopy did not show it even before treatment. However, enteroscopy, that diagnosed the worm before treatment was also repeated after 2 weeks that was unremarkable. Patient's haemoglobin gradually started increasing with oral iron supplements. After 12 months of follow up, he is asymptomatic with haemoglobin of 13.2 g/dl (normal 13–18 g/dl) and no episodes of any gastrointestinal bleeding.

## Discussion

Hookworm infestation is common in 740 million people worldwide.<sup>[1]</sup> In India, the prevalence of hookworm infestation varies from 5% to 76%.<sup>[2]</sup> In rural India, hookworm infestation causes anaemia in 70-90% of cases.<sup>[2]</sup> In humans, it is caused by *N. americanus* and *Ancylostoma duodenale*. *N. americanus* predominates in southern India whereas *A. duodenale* is more common in northern parts of the country.<sup>[1]</sup> It is usually acquired by soil contaminated with human waste.<sup>[1]</sup>

The manifestations of hookworm infestation can range from an asymptomatic presentation to symptoms such as abdominal pain, flatulence and diarrhoea. This varied clinical picture depends on parameters like the duration of infection, load of worms and iron stores in the body.<sup>[3]</sup> The distinctive picture of chronic infestation is iron deficiency anemia, due to chronic intestinal blood loss.<sup>[3]</sup> However, a massive gastrointestinal bleeding as a consequence of hookworm infestation is quite a rare entity. It is frequently seen in children, although not so common in adults. Acute heavy infestation may present as massive gastrointestinal bleed in form of melena. 0.1-0.4 ml of blood per day is taken up as a meal by each worm, leading to blood loss of nearly 250 ml/day in heavy infections.<sup>[3]</sup> Hookworm infestation is usually confined to the small intestine.<sup>[3]</sup>

Haematological investigation had revealed iron deficiency anemia and eosinophilia. Stool microscopy showing 40  $\mu\text{m}$   $\times$  60  $\mu\text{m}$  oval hookworm eggs help to clinch the diagnosis, but these are apparent after 1 week of commencement of bleeding. Once the worms lodge themselves in the wall of the small intestine, they start sucking blood. Their

reproductive system develops only after another 1 week. This explains the late appearance of the hookworm ova in the stool. Hence, fecal examination, both by simple and concentration methods should regularly be done.<sup>[4]</sup> It is advisable to repeat the stool examination on three separate samples, although stool examination may be normal in 40% of patients. The presence of mouth capsules, bursae, and spicules help to differentiate *A. duodenale* and *N. americanus* from each other on stool examination. The diagnosis is usually made on distinctive clinical grounds like eosinophilia and egg shape morphology on stool examination.<sup>[1]</sup> The stool examination shows eggs that are oval and ellipsoid measuring 60  $\mu$   $\times$  40  $\mu$ . Their shells are thin-walled, smooth and colorless. Their internal cleavages are well developed at the 4–8 cell stage, which pull away from the shell, leaving an empty space. *N. americanus* have smaller male (7–9 mm), smaller buccal capsule with two pairs of semilunar cutting plates, copulatory spicules are fused at ends to form a sharp tip, vulva opens a little in front of the middle one-third and anterior end bent in opposite direction of general curvature of body.<sup>[5]</sup> *A. duodenale* have longer male (8–11 mm), prominent buccal capsules with two pairs of teeth, copulatory spicules are not fused, vulva opens at junction of middle and posterior one-third, and anterior end bent in same direction of general curvature of body.<sup>[5]</sup>

Sometimes, hookworms may be picked up on endoscopy. These are seen as small, ambulatory worms on endoscopy, which may adhere to the mucosa of the small bowel. Surrounding the worms, erosions, blood or even hyperemia may be appreciated. Endoscopy scores over stool examination as it helps identify other causes of blood loss and one need not wait for the outcome of the 3-6 successive stool samples.

When worms are seen in the intestine by endoscopy, it is important to differentiate them to ascertain the diagnosis and thereby prescribe appropriate treatment. The worms can be differentiated according to their location of the infestation and their structure under microscopy. The intestinal worms commonly found are *Ascaris lumbricoides*, *A. duodenale*, *N. americanus*, *Trichuris trichiura*, *Enterobius vermicularis*, *Strongyloides stercoralis*, *Capillaria philippinensis*, and *Anisakis*. *Ascaris* is a large roundworm (15-40 cm in length) which resides in the small intestine, whereas *Strongyloides stercoralis* is small (2-3 mm in length) inhabiting the mucosa of duodenum or upper jejunum. Hookworm inhabits the upper portion

of a small intestine. Whipworm (30-50 mm in length) and pinworm (10 mm in length) usually reside in a large intestine mostly around the cecum. Hence they are not seen during esophagogastroduodenoscopy. The remaining parasites which inhabit the upper portion of small intestine need other modalities of investigations to identify them besides endoscopy.<sup>[1]</sup>

In a recent series by Ghoshal *et al.*,<sup>[6]</sup> hookworm infestation alone which were identified on capsule endoscopy, has been attributed as the cause of overt obscure gastrointestinal bleed in four patients. Gupta *et al.*,<sup>[7]</sup> have also diagnosed a single of hookworm infestation on capsule endoscopy among 154 patients with obscure gastrointestinal bleed. We too have experience in identifying hookworm infestation on enteroscopy. Treatment includes oral anthelmintics like albendazole (400 mg once) and mebendazole (100 mg twice daily for 3 days) for effective treatment. Oral iron supplements for iron-deficiency anemia and nutritional support for protein malnutrition may also be required in symptomatic disease.

## References

1. Feldman M, Friedman LS, Brandt LJ. Sleisenger and Fortran's Gastrointestinal and Liver Disease: Pathophysiology/Diagnosis/Management. 9<sup>th</sup> ed. Philadelphia: Saunders Elsevier Publisher; 2010. p. 1925-6.
2. Ananthakrishnan S, Nalini P, Pani SP. Intestinal geohelminthiasis in the developing world. Natl Med J India 1997;10:67-71.
3. Gambhir DS, Misra RC, Rao B, Chaturvedi AK, Ghosh BK, Gupta PS. Intestinal blood loss in hookworm infestation. J Assoc Physicians India 1978;26:887-90.
4. Kumar T, Jiwane AV, Kothari P, Kulkarni BK, Sane S, Sawant P. Massive gastrointestinal bleeding in a infant: A diagnostic dilemma. J Indian Assoc Pediatr Surg 2001;6:149-51.
5. Yoshida Y. Morphological differences between *Ancylostoma duodenale* and *Necator americanus* in the fourth larval stage. J Parasitol 1966;52:122-6.
6. Ghoshal UC, Lakshmi CP, Kumar S, Das K, Misra A, Rai P, *et al.* Capsule endoscopy for obscure gastrointestinal bleeding in the tropics: Report from India. Dig Endosc 2011;23:17-23.
7. Gupta R, Lakhtakia S, Tandan M, Banerjee R, Ramchandani M, Anuradha S, *et al.* Capsule endoscopy in obscure gastrointestinal bleeding – An Indian experience. Indian J Gastroenterol 2006;25:188-90.

**How to cite this article:** Patil M, Sheth KA, Devarbhavi H. Endoscopy in a rare presentation of worms. J Dig Endosc 2014;5:80-2.

**Source of Support:** Nil, **Conflict of Interest:** None declared.