

Case Report

An unusual experience with endoscopic retrograde cholangiopancreatography

Mallikarjun Patil, Keyur A. Sheth, C. K. Adarsh, B. Girisha

Department of Gastroenterology, St John's Medical College, Bangalore, Karnataka, India

Abstract

The endoscopic retrograde cholangiopancreatography (ERCP) is known for its varied diagnostic and therapeutic utility for a variety of disorders. However it has greater likelihood of procedure related complications among the endoscopic procedures of gastrointestinal tract. The extraluminal hemorrhagic complications following ERCP are potentially life threatening though relatively rare. We present a 50 year patient with choledocholithiasis and cholelithiasis developing rare complication of subcapsular hepatic hematoma, following ERCP due to guide wire injury.

Key words

Endoscopic retrograde cholangiopancreatography, subcapsular hematoma, guide wire

Introduction

The endoscopic retrograde cholangiopancreatography (ERCP) is a well-established procedure for diagnostic and therapeutic interventions for a wide variety of disorders. However, it is associated with a number of complications. In ERCP, extraluminal hemorrhagic complications are potentially life-threatening though relatively rare. Hence, these complications should be diagnosed early for treatment. We present a rare complication of subcapsular hepatic hematoma with ERCP due to guide wire injury.

Case Report

A 50-year-old male presented to us with right upper quadrant abdominal pain, moderate grade fever associated with chills, and jaundice for last 4 days. He had no history of weight loss, change in bowel habits, or alcohol intake. He was not on any medication. He was febrile with tachycardia of 120/min. He also had icterus with right upper quadrant tenderness. Laboratory

data showed leukocytosis with total count around 14,000/mm³. Liver biochemical tests showed cholestasis with serum total bilirubin of 3.8 mg/dL (normal less than 1.0 mg/dL) with conjugated bilirubin 3.0 mg/dL (normal less than 0.3 mg/dL), serum alkaline phosphatase of 320 U/L (normal 50-136), serum gamma glutamyl transferase 430 U/L (normal 15-85 U/L), serum aspartate aminotransferase 110 U/L (normal 15-37 U/L), and serum alanine aminotransferase 120 U/L (normal 30-65 U/L). Ultrasound (US) of abdomen showed gallstones, and dilated common bile duct (CBD) and intrahepatic biliary radicals. In view of cholangitis, ERCP was performed, which showed dilated CBD containing multiple calculi. Endoscopic sphincterotomy was performed over a 0.035 inch diameter straight tip guide wire with successful clearance of stones with balloon sweeps.

He was asymptomatic for next 48 h, when he suddenly complained of right upper quadrant abdominal pain which was not relieved with analgesics. His serum amylase, lipase, coagulation work-up, and plain radiograph of the abdomen were within normal limits. An urgent US and subsequent contrast-enhanced computed tomography [Figures 1 and 2] demonstrated 5 × 3 cm subcapsular hepatic hematoma on right lobe of liver with air foci in it. He was afebrile and hematocrit remained stable. On reviewing, ERCP fluoroscopy images [Figure 3], we found bile duct leak on cholangiogram probably due to guide wire injury. Hematoma [Figure 4] was aspirated percutaneously under US-guidance, which revealed blood. He was

Access this article online

Website: www.jdeonline.in	Quick Response Code 
DOI: 10.4103/0976-5042.132408	

Address for correspondence:

Dr. Mallikarjun Patil, Department of Gastroenterology, St. John's Medical College, Sarjapura Road, Bangalore - 560 034, Karnataka, India.
E-mail: drmalli_arjun@yahoo.co.in

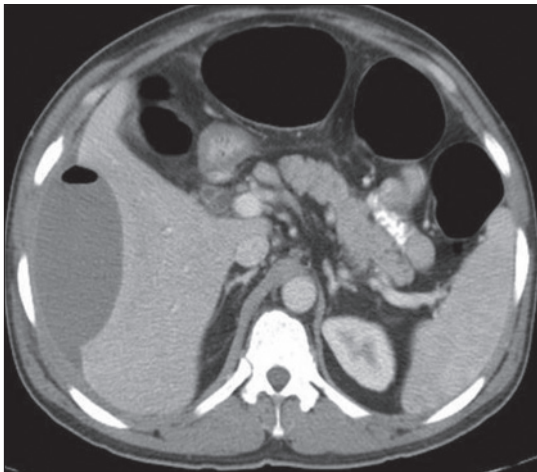


Figure 1: Contrast-enhanced computed tomography scan showing subcapsular hematoma with air foci

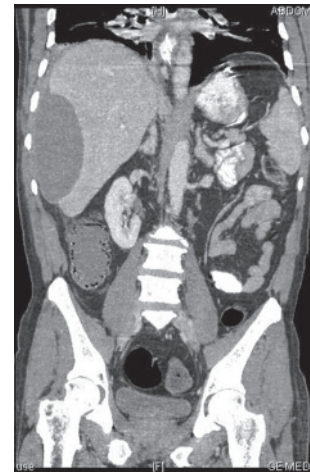


Figure 2: CECT scan showing subcapsular hepatic hematoma

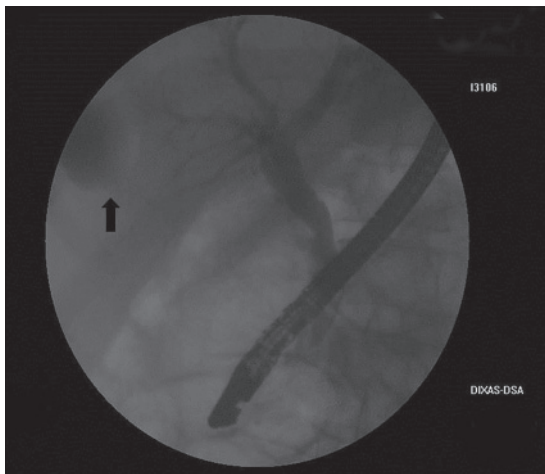


Figure 3: Endoscopic retrograde showing contrast leak from bile duct

managed conservatively with antibiotics and analgesics. He improved gradually and repeat US done after 6 weeks showed complete resolution of hematoma. He subsequently underwent an uneventful cholecystectomy.

Discussion

The ERCP offers unprecedented opportunities for therapeutic interventions for variety of pathologic disorders including the management of choledocholithiasis, diagnosis and management of biliary and pancreatic neoplasms, and postoperative management of biliary perioperative complications. The common complications of ERCP includes pancreatitis (2-25%), bleeding (1-2%), perforation (0.5%), and cholangitis (less than 1%).

Subcapsular hematoma as a complication of ERCP is rare. It most likely developed following guide wire trauma during ERCP. Patient had received no other trauma or intervention other than ERCP to cause hematoma. It is assumed that subcapsular hematoma formation occurs as an accidental

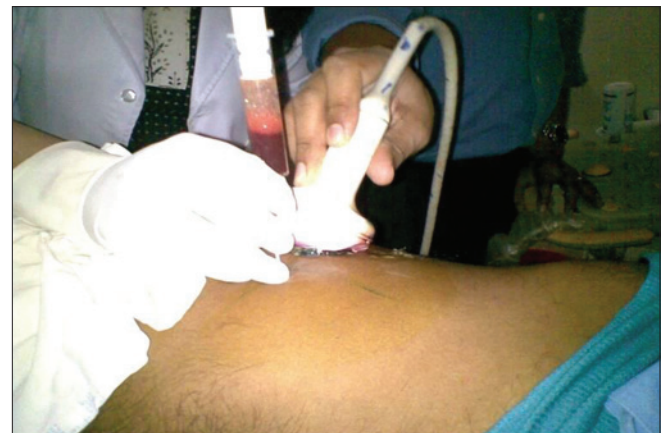

Figure 4: Ultrasound guided percutaneous aspiration of hematoma

rupture of intrahepatic bile duct followed by rupture of small blood vessels within the liver parenchyma.^[1] ERCP is not performed under strict sterile conditions, hence, there is always a risk of infection and abscess formation.^[1] Conservative treatment involving antibiotics and analgesics is quite enough in most cases. Hepatic artery embolization may be required in refractory cases, whereas, operative management may be required for refractory or ruptured subcapsular hematoma.^[2]

Ertugrul *et al.*,^[1] reported a 41-year-old man who underwent ERCP to replace a biliary stent for cholangiocarcinoma. He was seen 2 days later complaining of fever and right upper quadrant pain. A subcapsular hepatic hematoma was demonstrated on US and CT scanning. He was also managed conservatively with intravenous fluid replacement, antibiotics, and analgesics. A subsequent scan 29 days later confirmed complete resolution.

Horn and Pena^[2] reported a case of an 88-year-old woman who had jaundice due to cholangiocarcinoma and underwent emergency ERCP. She developed abdominal pain and a

falling hematocrit after the procedure. On imaging, large subcapsular hepatic hematoma was found. She was managed conservatively with transfusion of packed red blood cells, as well as intravenous administration of crystalloids and antibiotics.

McArthur and Mills^[3] reported a case of 71-year-old man with 4 weeks history of right upper quadrant abdominal pain, fever, jaundice, and itching. He underwent ERCP with sphincterotomy and biliary stenting for choledocholithiasis. After 12 h he had abdominal pain and later found to have subcapsular hepatic hematoma post ERCP. He was managed conservatively with antibiotics, analgesia, and intravenous crystalloids.

Chi and Waxman^[4] reported a case of 43-year-old woman who had obstructive jaundice as a result of metastatic cancer. She underwent ERCP as a palliative measure and unfortunately a subcapsular hepatic hematoma developed, which eventually ruptured. She was managed with emergency embolization of right hepatic artery due to falling hematocrit.

Conclusion

Fortunately, occurrence of subcapsular hepatic hematoma post ERCP is rare. However, it should be included in post ERCP complications because early recognition and conservative management is enough in most of the cases.

References

1. Ertuğrul I, Parlak E, Ibiş M, Altıparmak E, Şaşmaz N, Sahin B. An unusual complication of endoscopic retrograde cholangiopancreatography. *Dig Dis Sci* 2006;51:1167-8.
2. Horn TL, Pena LR. Subcapsular hepatic hematoma after ERCP: Case report and review. *Gastrointest Endosc* 2004;59:594-6.
3. McArthur KS, Mills PR. Subcapsular hepatic hematoma after ERCP. *Gastrointest Endosc* 2008;67:379-80.
4. Chi KD, Waxman I. Subcapsular hepatic hematoma after guide wire injury during endoscopic retrograde cholangiopancreatography: Management and review. *Endoscopy* 2004;36:1019-21.

How to cite this article: Patil M, Sheth KA, Adarsh CK, Girisha B. An unusual experience with endoscopic retrograde cholangiopancreatography. *J Dig Endosc* 2013;4:114-6.

Source of Support: Nil, **Conflict of Interest:** None declared.

Author Help: Online submission of the manuscripts

Articles can be submitted online from <http://www.journalonweb.com>. For online submission, the articles should be prepared in two files (first page file and article file). Images should be submitted separately.

- 1) **First Page File:**
Prepare the title page, covering letter, acknowledgement etc. using a word processor program. All information related to your identity should be included here. Use text/rtf/doc/pdf files. Do not zip the files.
- 2) **Article File:**
The main text of the article, beginning with the Abstract to References (including tables) should be in this file. Do not include any information (such as acknowledgement, your names in page headers etc.) in this file. Use text/rtf/doc/pdf files. Do not zip the files. Limit the file size to 1 MB. Do not incorporate images in the file. If file size is large, graphs can be submitted separately as images, without their being incorporated in the article file. This will reduce the size of the file.
- 3) **Images:**
Submit good quality color images. Each image should be less than 4096 kb (4 MB) in size. The size of the image can be reduced by decreasing the actual height and width of the images (keep up to about 6 inches and up to about 1800 x 1200 pixels). JPEG is the most suitable file format. The image quality should be good enough to judge the scientific value of the image. For the purpose of printing, always retain a good quality, high resolution image. This high resolution image should be sent to the editorial office at the time of sending a revised article.
- 4) **Legends:**
Legends for the figures/images should be included at the end of the article file.