

Calcinosis Cutis: Report of 4 Cases

Prakash Hulivahana Muddegowda, Jyothi Basavanahalli Lingegowda, Ramkumar Kurpad Ramachandrarao, Prasanna Guddappa Konapur

Department of Pathology, Vinayaka Missions Kirupananda Variyar Medical College, Salem, Tamil Nadu, India

Address for correspondence: Dr. Prakash H Muddegowda, E-mail; medicoprakash@gmail.com

ABSTRACT

Calcinosis cutis is a condition of accumulation of calcium salts within the dermis. We are presenting four cases of calcinosis cutis, with different clinical presentations, occurring in healthy individuals, with normal serum calcium and phosphorus levels. Histologically, all cases showed similar morphology, the lesions were composed of large and small deposits of calcium. Foreign-body giant cell reaction was seen in one case. Another case had intact and ruptured epidermal cysts and calcification within the cyst.

Keywords: Calcinosis cutis, dystrophic calcinosis, subepidermal calcified nodule, tumoral calcinosis

INTRODUCTION

Calcinosis cutis is characterized by deposition of calcium in the skin. Calcinosis cutis is of four types: dystrophic, idiopathic, metastatic and iatrogenic. Dystrophic calcinosis is calcification associated with infection, inflammatory processes, cutaneous neoplasm or connective tissue diseases.^[1,2] Idiopathic calcinosis cutis is cutaneous calcification of unknown cause with normal serum calcium. Subepidermal calcified nodule and tumoral calcinosis are idiopathic forms of calcification. Metastatic calcification results from elevated serum levels of calcium or phosphorus. Iatrogenic and traumatic calcinosis are those types which are associated with medical procedures.^[1,2]

CASE REPORTS

Case 1

30 year old male presented with multiple swelling in the scrotum of three months duration. A provisional diagnosis of sebaceous cysts of the scrotum was made. Excised lesion measured 0.4-1 cm on gross

examination, and (H and E stain, ×10) revealed multiple small cysts with basophilic deposits in the dermis [Figure 1]. Diagnosis of dystrophic scrotal calcinosis was made. Scrotal calcinosis is a rare benign process, characterized by multiple, painless, hard scrotal nodules in the absence of systemic metabolic disorder. Inflammation and rupture of epidermoid cysts is the pathogenetic mechanism of the disease.^[3-5]

Case 2

40 year old male presented with swelling around the knee. The lesion measured 4 × 2 × 1 cm, and upon excision was gritty to cut, and showed chalky white areas. (H and E stain, ×10) showed basophilic masses in the subcutaneous tissue. Histopathological diagnosis was of tumoral calcinosis.

Case 3

28 year old female presented with a mass in the lower left thorax. The excised lesion measured 5 × 3 × 1.5 cm, with chalky white areas. (H and E stain, ×10) revealed basophilic masses in fibrocollagenous tissue with foreign body giant cell reaction [Figure 2]. Diagnosis of tumoral calcinosis was made.

Tumoral calcinosis is a special form of idiopathic calcinosis cutis characterized by large periarticular deposits of calcium and found mainly around the hip, knee, shoulder and elbow joints. It is a rare benign lesion, however it may mimic malignancy. The basic defect is in the proximal renal tubular cell with an elevated renal

Access this article online	
Quick Response Code: 	Website: www.jlponline.org
	DOI: 10.4103/0974-2727.86849

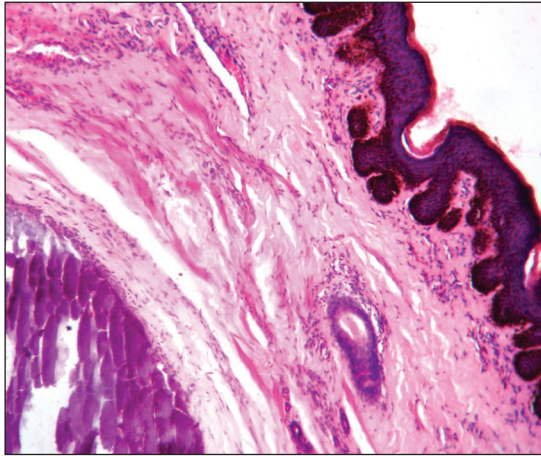


Figure 1: Calcification and basophilic deposits in the dermis with multiple small cysts in the sebaceous cyst of scrotum in Case 1 of the study

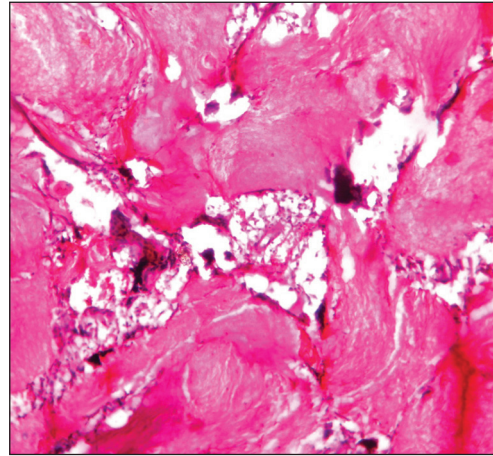


Figure 2: Tumoral calcinosis with foreign body giant cell reaction in Case 3 of the study

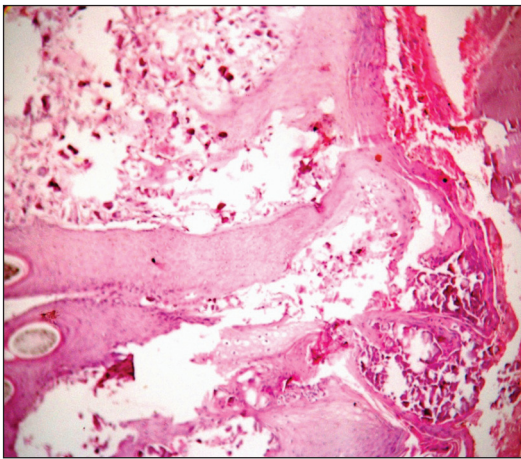


Figure 3: Calcinosis in the upper dermis in subepidermal calcified nodule in Case 4 of the study

phosphate reabsorption threshold and increased production of 1, 25-dihydroxyvitamin D. It is classified into- primary normo-phosphatemic tumoral calcinosis (NPTC), primary hyper-phosphatemic tumoral calcinosis and secondary tumoral calcinosis. This subtyping is closely related to the prognosis and response to treatment. The prognosis of NPTC is better than that of other subtypes.^[6-8] Case-2 and case-3 fit into the NPTC subtype characterized by lack of familial occurrence, solitary calcification, no history of antecedent trauma, no biochemical abnormalities and no recurrence after surgical removal.

Case 4

35 year old female presented with swelling in the right arm since 4 months, which was clinically diagnosed as pyogenic granuloma. The lesion measured 3 × 2 × 1 cm, and (H and E stain, ×10) revealed basophilic masses in the dermis [Figure 3]. Histopathological diagnosis of subepidermal calcified nodule was made.

Subepidermal calcified nodule, an uncommon but distinct type of idiopathic calcinosis is not associated with biochemical abnormalities or systemic illness. It occurs more commonly on the face and ear of children, and is asymptomatic.^[1,2,9,10] This case is presented due to its unusual clinical presentation.

CONCLUSION

After clinical diagnosis of calcinosis cutis, a laboratory workup to rule out abnormalities of calcium and phosphorus metabolism, malignant processes, collagen vascular diseases, renal insufficiency, excessive milk ingestion, vitamin D poisoning must be carried out to detect the underlying cause of the disease.

REFERENCES

1. Kayhan TC, Temiz P, Ermertcan AT. Calcinosis cutis on the face. *Indian J Dermatol Venereol Leprol* 2009;75:180-1.
2. James WD, Berger TG, Elston DM. *Andrews' Diseases of the Skin: Clinical Dermatology*. 11th ed. Philadelphia (PA): Elsevier/Saunders; 2011. p. 516-8
3. Dubey S, Sharma R, Maheshwari V. Scrotal calcinosis: Idiopathic or dystrophic? *Dermatology* 2010;16:5.
4. Bhat D, Parate S, Bobhate SK. Scrotal calcinosis presenting as nodular masses: A report of 4 cases. *Indian J Dermatol* 2003;48:112-3.
5. Polk P, McCutchen WT, Phillips JG, Biggs PJ. Polypoid scrotal calcinosis: An uncommon variant of scrotal calcinosis. *South Med J* 1996;89:896-7.
6. Datta C, Bandyopadhyay D, Bhattacharyya S, Ghosh S. Tumoral calcinosis. *Indian J Dermatol Venereol Leprol* 2005;71:293-4.
7. Jindal S, Surjushe A, Sao P, Saple DG. Tumoral calcinosis. *Indian J Dermatol Venereol Leprol* 2008;74:282-3.
8. Olsen KM, Chew FS. Tumoral calcinosis: Pearls, polemics, and alternative possibilities. *Radiographics* 2006;26:871-85.
9. Seo HS, Kang JJ, Jung E, James LH, William D. A case of subepidermal calcified nodule in auricle. *Korean J Otorhinolaryngol Head Neck Surg* 2007;50:947-9.
10. Carvounis PE, Santi M, Ster JB, Miller M. Subepidermal calcified nodules. *Ophthalmologica* 2005;219:112-4.

How to cite this article: Muddegowda PH, Lingegowda JB, Ramachandrarao RK, Konapur PG. Calcinosis cutis: Report of 4 cases. *J Lab Physicians* 2011;3:125-6.

Source of Support: Nil. **Conflict of Interest:** None declared.