

Two Cases of Eosinophilic Variant Chromophobe Renal Cell Carcinoma, with a Rare Association of Right Atrial Myxoma in One of them

Sunil Kumar Yeshvanth, Harish S Permi, Kishan Prasad Hosapatna Laxminarayana, Teerthanath Shrinivas, Jayaprakash K Shetty

Department of Pathology, K. S. Hegde Medical Academy of Nitte University, Deralakatte, Mangalore, India

Address for correspondence: Dr. Sunil Kumar Y, E-mail: drsunilkumary@rediffmail.com

ABSTRACT

Chromophobe renal cell carcinoma is a relatively uncommon variant of renal cell carcinoma. Eosinophilic variant of chromophobe renal cell carcinoma (EVCRC) is still less frequent and is composed predominantly of small to medium-sized cells with abundant granular eosinophilic cytoplasm. We report two cases of EVCRC, with one having a rare association of right atrial myxoma. We present these cases, due to the rarity of EVCRC and an unusual association of right atrial myxoma in one of them. Both patients recovered well after surgery, with no recurrence or metastasis after 2 years of follow-up.

Keywords: Atrial myxoma, chromophobe renal cell carcinoma, eosinophilic variant

INTRODUCTION

Chromophobe renal cell carcinoma (CRCC) comprise about 5% of all renal neoplasms, described in 1985 by Thoenes.^[1,2] Both sporadic and hereditary forms exist. The prognosis is good and the mortality rate is less than 10%.^[3-5] The typical variant is common and composed of cells with thick well-defined borders, raisinoid nuclei, and abundant pale granular cytoplasm. Eosinophilic variant of chromophobe renal cell carcinoma (EVCRC) is less frequent and is composed of small- to medium-sized cells with abundant granular eosinophilic cytoplasm.^[2] Atrial myxomas are rare benign tumors of the heart with incidence of 0.001--0.33%.^[6] The coexistence of both EVCRC and atrial myxoma in a single patient has never been reported in the world literature. One of our cases had EVCRC and right atrial myxoma which was clinically misdiagnosed as metastatic thrombus.

CASE REPORTS

Case 1

A 55-year-old male, presented with painless intermittent hematuria for 3 months and recent onset of breathlessness. On examination a vague mass was palpable in the right lumbar region. Urine analysis showed hematuria and biochemical examination revealed elevated levels of blood urea of 46 mg/dl and serum creatinine of 1.7 mg/dl. The hematological investigations were within normal limits. Computerized tomography (CT) of abdomen revealed a heterogeneously enhancing mass measuring 9 × 8 cm in the upper pole of the right kidney extending into the calyces and renal pelvis [Figure 1a]. CT thorax and transesophageal echo showed a 3 × 3 cm mass lesion in the right atrium, attached to the interatrial septum. Right radical nephrectomy with atrial mass excision was done in single setting. On gross examination, kidney revealed an ill-circumscribed tan gray tumor occupying the upper pole measuring 8 × 7 cm, extending into the renal medulla [Figure 1b]. The atrial mass was globular, circumscribed, dark brown gelatinous tissue measuring 4 × 3 cm [Figure 2a]. Microscopy of the atrial mass showed myxoid

Access this article online	
Quick Response Code: 	Website: www.jlponline.org
	DOI: 10.4103/0974-2727.86846

areas, stellate cells, multinucleate giant cells, proliferation of blood vessels, and areas of hemorrhage [Figure 2b]. Histologically, the renal tumor showed small- to medium-sized cells with abundant granular eosinophilic cytoplasm (type 1 cells) arranged in sheets and trabeculae [Figure 3a]. Few polygonal cells with distinct cell borders, pleomorphic nuclei with raisinoid appearance, perinuclear halo, and abundant pale granular eosinophilic cytoplasm (type 2 and 3 cells) were also seen. Renal vein, artery, capsule, and gerotas fascia were free from the tumor. Colloidal iron stain was positive with diffuse cytoplasmic reticular staining [Figure 3b]. Immunohistochemistry (IHC) showed positivity for cytokeratin (CK) 7 with peripheral cell accentuation and negativity for vimentin. The final diagnosis of EVCRCC (Furhman grade II, stage II) with right atrial myxoma was made.

Case 2

A 60-year-old female presented with intermittent painless hematuria since 1 month. Abdominal examination revealed a vague mass in the left lumbar region. Serum biochemical examination and hematological investigations were within normal limits. Urine examination revealed hematuria. CT abdomen showed a heterogenous mass lesion measuring 9 × 8.5 cm in the upper pole of the left kidney. Nephrectomy specimen showed a tan gray tumor involving the upper pole measuring 7 × 6.5 cm [Figure 1c]. Microscopy and IHC were similar to the previous case. The final diagnosis of EVCRCC (Furhman grade II, stage II) was done.

DISCUSSION

The EVCRCC occurs in the age group 27-86 years and are solid circumscribed tumors measuring from 1 to 30 cm. Multifocality and bilaterality are present in 8% and 3%, respectively. In unfixed specimens, the cut surface is homogeneously light brown or tan turning light gray after formalin fixation.^[3] Tumors with large size, necrosis, and sarcomatoid change are known to have worse prognosis.^[3,5] Hence, a thorough search for any evidence of sarcomatoid transformation and areas of tumor necrosis is warranted when a diagnosis of CRCC is made.^[2,5] Our both cases were free from necrosis and sarcomatoid transformation. Osseous metaplasia, neuroendocrine, and rhabdoid differentiation can rarely coexist with EVCRCC.^[3,5,7-9] Thoenes *et al.* reported 32 cases of CRCC, out of which 10 were EVCRCC.^[7] Amin *et al.* studied 145 cases of CRCC, out of which 60 were eosinophilic variant.^[4] In both these studies, all were isolated cases of EVCRCC. However, one of our case had rare coexistence of EVCRCC with

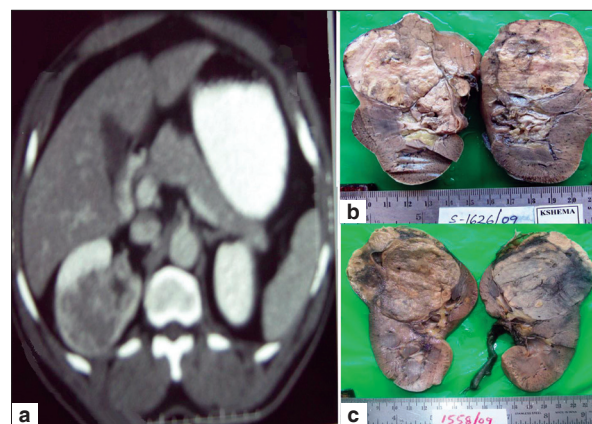


Figure 1: (a) CT scan of the abdomen showing a heterogeneously enhancing mass lesion in the right kidney. (b) Gross specimen of the right kidney (case 1) showing an ill-circumscribed tan gray tumor occupying the upper pole extending into the renal pelvis. (c) Gross specimen of the left kidney (case 2) showing a gray tan tumor occupying the upper pole

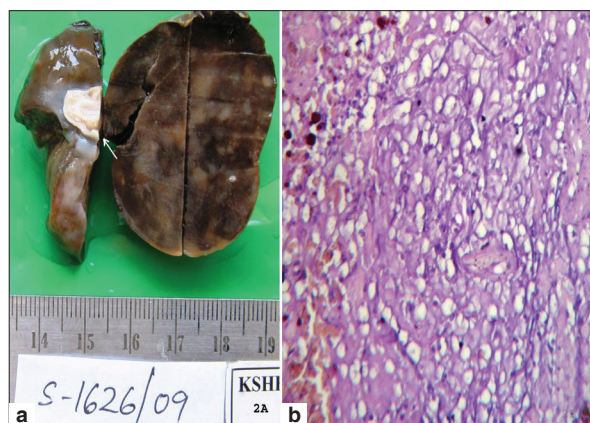


Figure 2: (a) Gross specimen of the right atrial myxoma comprising globular circumscribed, dark brown gelatinous mass with the attachment area to the endocardium (arrow). (b) Microphotograph of the right atrial myxoma showing myxoid areas, stellate cells, proliferation of blood vessels, and areas of hemorrhage. (Hematoxylin and Eosin stain, ×10)

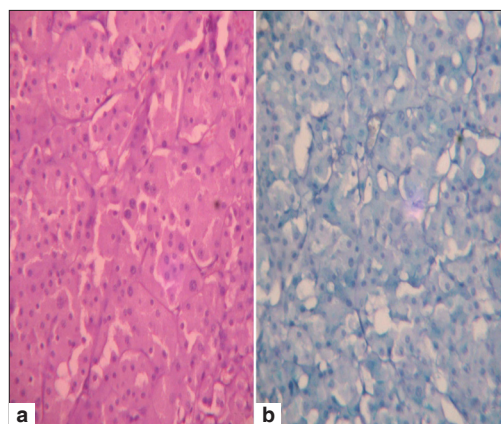


Figure 3: (a) Microphotograph of EVCRCC composed predominantly of small to medium-sized cells with abundant granular eosinophilic cytoplasm (type 1 cells) arranged in trabeculae and nests (×10, Hematoxylin and Eosin stain). (b) Colloidal iron special stain showing diffuse cytoplasmic reticular positivity (×10)

right atrial myxoma, which is the first case reported in the world literature. IHC of EVCRCR shows positivity for CK 7 and negativity for vimentin. Ultrastructurally, the cytoplasm is crowded with numerous 150-300 nm invaginated vesicles. EVCRCR is likely to be mistaken for oncocytoma because of the predominance of type 1 cells. The points helping in differentiating include the following: EVCRCR have tumor cells arranged in sheets, as opposed to nested and tubular pattern in oncocytoma, the wrinkled or raisinoid nuclear morphology in EVCRCR as opposed to the round, hyperchromatic nuclei in oncocytoma, well-defined cell borders with the presence of type 2 and type 3 cells in EVCRCR contrast to only type 1 cells in oncocytoma, Hale's colloidal iron stain showing diffuse reticular cytoplasmic positivity in EVCRCR, whereas oncocytomas displaying focal positive staining confined to the luminal borders. Our both cases showed diffuse reticular cytoplasmic colloidal iron staining and positivity for CK 7, hence ruling out oncocytoma. A literature search reveals that many immunomarkers were used to differentiate EVCRCR and oncocytoma like caveolin 1, kidney-specific cadherin, and parvalbumin, but CK7 was potentially the most efficient one.^[10-12] Ultrastructurally, the oncocytoma cells are packed with mitochondria and the cells in EVCRCR have numerous microvesicles in the cytoplasm. Most literature suggests that EVCRCR is a tumor of low malignant potential with reported 5-year and 10-year survival rates of 78-100% and 80-90%, respectively.^[2] Both of our cases are doing well 2 years following surgery.

Myxomas usually occur between third to sixth decades and are common in women. They usually occur sporadically, but 7% are associated with autosomal dominant syndromes. Arising from the endocardium, myxomas usually extend into a cardiac chamber and are common in left atria. The common complications include embolism, intracardiac obstruction, and constitutional symptoms.^[13] In our first case, since the right atrial mass was diagnosed as myxoma, the staging of EVCRCR was reduced from stage III to stage II.

The pathogenesis of both EVCRCR and cardiac myxomas are entirely different.^[13] Both occurring in one patient has

never been reported. We hereby conclude that in a known case of renal cell carcinoma, even though organized thrombi or degenerating metastatic deposits in atrium is common, however, a remote possibility of myxoma needs to be thought off so that staging can be correctly done and treated accordingly.

REFERENCES

1. Billis A, Carvalho RB, Magrini E, Mattos AC, Negretti F, Niero VR, *et al.* Chromophobe renal cell carcinoma: clinicopathological study of 7 cases. *Ultrastruct Pathol* 1998;22:19-26.
2. Manipadam MT, Korula A, Chandrasingh J, Devasia A. Chromophobe renal cell carcinoma: A report of two cases with unusual histological features. *Indian J Urol* 2008;24:123-5.
3. Mostofi FK, Davis CJ. Histological typing of kidney tumors. World Health Organization international histological classification of tumors. 2nd ed. Berlin: Springer; 1997.
4. Amin MB, Paner GP, Alvarado-Cabrero I, Young AN, Stricker HJ, Lyles RH, *et al.* Chromophobe renal cell carcinoma: histomorphologic characteristics and evaluation of conventional pathologic prognostic parameters in 145 cases. *Am J Surg Pathol* 2008;32:1822-34.
5. Parada DD, Pena KB. Chromophobe renal cell carcinoma with neuroendocrine differentiation. *APMIS* 2008;116:859-65.
6. Banerjee A, Davenport A. Ascitis due to right atrial myxoma in a haemodialysis patient. *BMC Nephrol* 2006;7:4.
7. Thoenes W, Störkel S, Rumpelt HJ, Moll R, Baum HP, Werner S. Chromophobe cell renal carcinoma and its variants - A report of 32 cases. *J Pathol* 1988;155:277-87.
8. Murugan P, Basu D, Manikandan R, Dorairajan LN, Kumar S. Osseous metaplasia in renal cell carcinoma: report of a rare case. *Indian J Pathol Microbiol* 2008;51:399-401.
9. Shannon BA, Cohen RJ. Rhabdoid differentiation of chromophobe renal cell carcinoma. *Pathology* 2003;35:228-30.
10. Leroy X, Moukassa D, Copin MC, Saint F, Mazeman E, Gosselin B. Utility of cytokeratin 7 for distinguishing chromophobe renal cell carcinoma from renal oncocytoma. *Eur Urol* 2000;37:484-7.
11. Geramizadeh B, Ravanshad M, Rahsaz M. Useful markers for differential diagnosis of oncocytoma, chromophobe renal cell carcinoma and conventional renal cell carcinoma. *Indian J Pathol Microbiol* 2008;51:167-71.
12. Mathers ME, Pollock AM, Marsh C, O'Donnell M. Cytokeratin 7: a useful adjunct in the diagnosis of chromophobe renal cell carcinoma. *Histopathology* 2002;40:563-7.
13. Al-Mateen M, Hood M, Trippel D, Insalaco SJ, Otto RK, Vitikainen KJ. Cerebral embolism from atrial myxoma in pediatric patients. *Pediatrics* 2003;112:e162-7.

How to cite this article: Yeshvanth SK, Permi HS, Laxminarayana KH, Shrinivas T, Shetty JK. Two cases of eosinophilic variant chromophobe renal cell carcinoma, with a rare association of right atrial myxoma in one of them. *J Lab Physicians* 2011;3:116-8.

Source of Support: Nil. **Conflict of Interest:** None declared.