

Unusual Cause of Childhood Anemia: Imerslund Grasbeck Syndrome

Kishan Prasad Hosapatna Laxminarayana, Sunil Kumar Yeshvanth, Jayaprakash K Shetty, Harish S Permi, Chandrika Rao

Department of Pathology, K S Hegde Medical Academy of Nitte University, Mangalore, India

Address for correspondence: Dr. Kishan Prasad H L, E-mail; dr_kishanpath@yahoo.com

ABSTRACT

Imerslund Grasbeck syndrome (IGS) is a rare autosomal recessive childhood disorder characterized by selective Vitamin (vit) B 12 malabsorption with asymptomatic proteinuria without any structural renal pathology. The patients stay healthy for decades with life-long parenteral vit B12. We report a case of young female who presented with pancytopenia and proteinuria, evaluated in local hospitals as chronic hemolytic anemia (autoimmune cause), finally diagnosed as IGS on complete evaluation. She was treated with injectable vit B12 (1000 µg cyanocobalamin) and showed drastic recovery. IGS should be considered in patients with megaloblastic anemia not responding to oral vit B12 and associated proteinuria.

Keywords: Childhood anemia, megaloblastic anemia, Imerslund Grasbeck

INTRODUCTION

Megaloblastic anemia is an important morbidity in children and adolescents especially in developing countries and with poor socioeconomic status.^[1] Imerslund Grasbeck syndrome (IGS) is a rare autosomal recessive megaloblastic anemia characterized by selective Vitamin (vit) B12 deficiency and asymptomatic proteinuria.^[2,3] It is the most common cause of cobalamin deficiency in certain communities like Lapps in Scandinavia, North African Jews, few families in Norway and Finland.^[4,5] About 300 cases have been reported worldwide with new cases appearing in Eastern Mediterranean countries.^[3] It has varying manifestations like failure to thrive, insidious onset of infections, hematological and neurological symptoms.^[3] IGS is resistant for oral vit B12 supplements, but responds very well for parenteral therapy.^[2-7] We report a case of young female who presented with pancytopenia and proteinuria,

evaluated in local hospitals as chronic hemolytic anemia (autoimmune cause), finally diagnosed as IGS on complete evaluation. She was treated with injectable vit B12 and showed drastic recovery. Her hemogram and reticulocyte count showed good response with symptomatic improvement.

CASE REPORT

An 18-year-old unmarried female hailing from North Karnataka, came with history of generalized weakness and easy fatigability since 1 month. Generalized weakness was gradually progressive and associated with exertional dyspnea. There was no history of pain abdomen, melaena, hematemesis, hematuria, chest pain or cough. Past history revealed that she had similar complaints since childhood and was evaluated in local hospitals as chronic hemolytic anemia (Autoimmune etiology) and treated with oral vitamin supplements (vit B12 of 150 µg) and multiple blood transfusions. Family history and menstrual history were unremarkable. She was moderately built and moderately nourished on mixed diet had severe pallor (+++) and mild icterus (+). Abdomen on palpation revealed mild splenomegaly. Cardiovascular system/Respiratory system/Central nervous system examination was normal. Complete hemogram at

Access this article online	
Quick Response Code: 	Website: www.jlponline.org
	DOI: 10.4103/0974-2727.86845

the time of admission showed hemoglobin of 4 g/dl, erythrocyte count of 2.4 millions/dl, total leucocyte count of 3700 cells/mm³, platelet count of 1,17,000 cells/mm³, mean corpuscular volume of 114 fl, mean corpuscular hemoglobin of 33 pg, mean corpuscular hemoglobin concentration of 30%, reticulocyte count of 1.2% and erythrocyte sedimentation rate of 45 mm at the end of 1 hour. Her total protein was 7 g/dl, albumin was 4.8 g/dl, globulin was 2.2 g/dl, total bilirubin of 2.5 g/dl, direct of 0.6 g/dl and indirect was 1.9 g/dl. Blood urea, serum creatinine and uric acid were within normal limits. Urine analysis showed moderate proteinuria (++) with 24-hour urine protein of 0.9 g/dl (non-nephrotic range). Peripheral smear showed predominantly macrocytic erythrocytes, few elliptocytes, tear drop cells and macroovalocytes. Leucocytes and platelets were decreased.

Few hypersegmented neutrophils were seen. Stool for occult blood was negative. Serum lactate dehydrogenase was 12,500 units (normal range < 440 units). Serum vit B12 was 42.14 pg/ml (normal range 211-946pg/ml). Serum ferritin, iron, folate and total iron binding capacity were within normal limits. Ultrasound abdomen showed mild splenomegaly with no structural renal changes. Coombs test was negative. Gastric and ileal biopsy were normal. Intrinsic factor antibody was absent and transcobalamin levels were within normal limits. On reviewing previous records, she had similar complaints since childhood and was evaluated in various local hospitals as chronic hemolytic anemia (autoimmune etiology) and proteinuria with suspicious of vasculitic disorder. Twenty-four-hour urine protein was 1.8g/dl. Ham test, sucrose lysis test, sickling test, urine porphyrin and antinuclear antibodies were negative. Hemoglobin electrophoresis showed slight increase in Hb A2. G6PD and pyruvate kinase enzyme levels were within normal limits.

Bone marrow was hypercellular with Myeloid:Erythroid ratio of 1:2. Erythropoiesis was hyperplastic and showed megaloblastic change with many binucleated forms and frequent mitotic figures[Figure 1]. Myelopoiesis showed few giant metamyelocytes. Megakaryocytes were decreased. Perl's stain showed grade 1 iron store. In view of the above findings, possibilities of megaloblastic anemia and congenital dyserythropoietic anemia (CDA) were considered. Schilling test revealed low levels of urinary radioactive vit B12 excretion. Oral administration of intrinsic factor also failed to show improvement in radioactive vit B12 excretion. Patient was treated with loading dose of vit B12 1000 µg (cyanocobalamin) IM and 100 µg IM weekly for 3 months, showed good response with reticulocyte count (9%), hemoglobin raised to 9.2

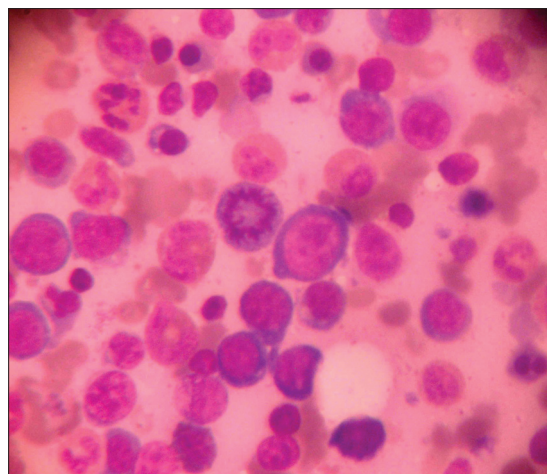


Figure 1: Bone marrow aspiration showing megaloblasts with dyserythropoiesis (Leishman, x400)

g/dl and erythrocyte count of 3.8 millions/dl. Drastic recovery with parenteral vit B12 and asymptomatic proteinuria ruled out the possibility of CDA. Hence, an adolescent female with pancytopenia, persisting asymptomatic proteinuria, bone marrow showing megaloblastic anemia with defective absorption of vit B12 in Schilling test, intact intrinsic factor and good response to parenteral vit B12, a final diagnosis of IGS was made. Patient symptomatically improved with regular parenteral vit B12 therapy and was followed up for 8 months. At her last follow-up hemoglobin was 10.8 g/dl and erythrocyte count of 4.1 millions/dl.

DISCUSSION

IGS, also termed as familial selective malabsorption of vit B12 associated with proteinuria was first described by Imerslund and Grasbeck *et al.*,^[2-4,6] Estimated prevalence of this disorder is <6:1,000,000 people.^[2] The diagnosis of IGS should be considered when three typical features are present like macrocytic anemia, decreased serum vit B12 level and proteinuria in absence structural renal pathology. IGS is caused by selective incapacity to transport the vit B12 across the intestinal wall. In most cases, the molecular basis of the selective malabsorption and proteinuria involves mutation in one or both of the two genes, cubulin on chromosome 10 or amnionless on chromosome 14.^[2-5,7,8] Both the proteins are components of the intestinal receptor for the vit B12-intrinsic factor complex and receptor mediating the tubular reabsorption of protein from the urine. The diagnosis of IGS is made by detecting the presence of cobalamin deficiency, then demonstrating it is poorly absorbed, then excluding other causes of vit B12 malabsorption and finally by

showing the response to parenteral vit B12.^[2,5,8] In our case, serum vit B12 was low (42.14 pg/ml) and Schilling test revealed low urinary radioactive vit B12 excretion. Patient was treated with loading dose of vit B12 1000 µg (cyanocobalamin) IM and 100 µg IM weekly for 3 months. After therapy, repeat Hb improved to 9.2 g/dl, reticulocyte count to 9% and erythrocyte count to 3.8 millions/dl. On regular follow-up, patient is doing well. However, proteinuria is mild and still is persisting. Few cases may be managed with 1 mg of vitamin B12 oral therapy administered at 2-week interval with varied clinical outcome.^[2] Although Schilling test was the gold standard method for detecting cobalamin absorption, it is now outdated due to constraints like reduced availability of test components, cost, radioactive waste disposal and concern about the animal derived tissues for human use (intrinsic factor).^[5] It is done in only few centers across the world. Replacement for it is under development like measurement of change in holotranscobalamin following oral administration of non-radio-labeled cobalamin and accelerated mass spectrometry.^[5] Both these methods show promise but not yet in routine practice.

This disease is transmitted as an autosomal recessive trait; hence, early detection of this disorder would enable screening and genetic counselling for asymptomatic family members. The patient should be warned not to stop the treatment eventhough symptoms seen not to reappear immediately following cessation of therapy.^[2,3]

ACKNOWLEDGMENT

We are thankful to Dr Nagaraj, Professor of Medicine, K S Hegde Medical Academy and Dr Urmila Khadilkar, Professor of Pathology, Kasturba Medical College, Mangalore for their valuable suggestions and guidance.

REFERENCES

1. Gomber S, Kela K, Dhingra N. In brief reports, Clinico-hematological profile of megaloblastic anemia. *Indian Pediatr* 1998;35:55-8.
2. Grasbeck R. Imlerslund-Grasbeck syndrome (selective vitamin B12 malabsorption with proteinuria). *Orphanet J Rare Dis* 2006;1:17.
3. Lin SH, Sourial NA, Lu KC, Hsueh EJ. Imlerslund-Grasbeck syndrome in a Chinese family with distinct skin lesions refractory to vitamin B12. *J Clin Pathol* 1994;47:956-8.
4. SH Lin, Sourial NA, Lu KC, Hsueh EJ. Imlerslund-Grasbeck syndrome in a Chinese family with distinct skin lesions refractory to vitamin B12. *J Clin Pathol* 1994;47:956-8.
5. Ralph Green in chapter 41, Folate, cobalamin and megaloblastic Anemias. In: Kaushansky K, Litchman MA, Beutler E, Kipps TJ, Seligsohn U, editors. *Williams Hematology*. 8th ed. New Delhi: Mc Graw-Hill Publication; 2010. p. 533-63.
6. Ayub T, Khan FU. Prevalence of megaloblastic anaemia in a paediatric unit. *Gomal J Med Sci* 2009;7:62-4.
7. Broch H, Imlerslund O, Monn E, Hovig T, Seip M. Imlerslund Grasbeck anemia. A long-term follow-up study. *Acta Paediatr Scand* 1984;73:248-53.
8. Wickramasange SN in chapter 12, Macrocytic anemia. In Wickramasinghe SN's *Blood and Bone Marrow Pathology*. London: Churchill Livingstone; 2003. p. 229-47.

How to cite this article: Laxminarayana KH, Yeshvanth SK, Shetty JK, Permi HS, Rao C. Unusual cause of childhood anemia: Imlerslund grasbeck syndrome. *J Lab Physicians* 2011;3:113-5.

Source of Support: Nil. **Conflict of Interest:** None declared.

Announcement

Android App



Download
**Android
application**

FREE

A free application to browse and search the journal's content is now available for Android based mobiles and devices. The application provides "Table of Contents" of the latest issues, which are stored on the device for future offline browsing. Internet connection is required to access the back issues and search facility. The application is compatible with all the versions of Android. The application can be downloaded from <https://market.android.com/details?id=comm.app.medknow>. For suggestions and comments do write back to us.