Article published online: 2020-04-19

Case Report

Renal Abscess Caused by *Salmonella Typhi*

Amarjeet Kaur, Smita Sarma, Navin Kumar, Sharmila Sengupta

Department of Microbiology, Medanta - The Medicity, Gurgaon, Haryana, India

Address for correspondence: Dr. Amarjeet Kaur, E-mail: amar.k.kanjan@gmail.com

ABSTRACT

Salmonella typhi is a true pathogen, which is capable of causing both intestinal and extraintestinal infections. Unusual presentations of *Salmonella* should always be kept in mind as this organism can cause disease in almost any organ of the body. *S. typhi* has been reported to cause the life-threatening infections such as meningitis, endocarditis, myocarditis, empyema, and hepatic abscess. Renal involvement by *S. typhi* is a relatively rare presentation. We report a case of renal abscess caused by *S. typhi* in an afebrile, 10-year-old child who did not have any clinical history of enteric fever. To our knowledge, this is the first reported case of isolation of *S. typhi* from the renal abscess, and interestingly this isolate was found to be resistant to quinolones.

Key words: Fluoroquinolones, renal abscess, *Salmonella typhi*

INTRODUCTION

Typhoid fever caused by *Salmonella typhi* is endemic in many parts of India. Less commonly, extraintestinal infections can occur with *S. typhi*. These extraintestinal infections can involve liver, spleen, lung, bones, joints, endocardium, or central nervous system.[1-9] Genitourinary infections by *S. typhi* are relatively rare. A renal abscess is commonly caused by *Staphylococci, Escherichia coli*, *Klebsiella*, and *Proteus*. There are documented reports of renal abscess caused by *Salmonella virchow*, *Salmonella enteritidis*, *Salmonella Typhimurium*, and *Salmonella paratyphi* A.[10-13] We report a case of renal abscess caused by *S. typhi*. In a PubMed/PubMed Central search of reported cases, there is no case of isolation of *S. typhi* from renal abscess so far. Interestingly, the isolate was found to be resistant to ciprofloxacin (minimum inhibitory concentration [MIC] ≥1 μg/ml).

Access this article online

Quick Response Code:

Website: www.jlponline.org

DOI: 10.4103/0974-2727.163132

CASE REPORT

A 10-year-old male child, a known case of congenital atrophy of left kidney presented with complaints of mild pain in the right lumbar area of 3 days. He did not have any urinary symptoms, vomiting, jaundice, bladder, or bowel disturbance. The patient was afebrile and hemodynamically stable. General physical and systemic examinations were unremarkable except for flank tenderness on the right side. Laboratory investigations revealed hemoglobin: 11.1 g/dl and a total leukocyte count: 16.51 × 10^3/μl. Renal function tests were normal with blood urea: 33 mg/dl and serum creatinine: 0.7 mg/dl. Ultrasound kidney, ureter, bladder regions on the right side showed enlarged kidney (11.7 × 5.6) with hydronephrosis of the mid and lower poles with hydroureter. A cystic lesion was seen in mid pole with sedimenting hyperechoic

This is an open access article distributed under the terms of the Creative Commons Attribution-NonCommercial-ShareAlike 3.0 License, which allows others to remix, tweak, and build upon the work non-commercially, as long as the author is credited and the new creations are licensed under the identical terms.

For reprints contact: reprints@medknow.com

How to cite this article: Kaur A, Sarma S, Kumar N, Sengupta S. Renal abscess caused by *Salmonella Typhi*. J Lab Physicians 2015;7:121-3.

contents. An ill-defined hypoechoic area was seen in the upper pole measuring 4.2 cm × 3.1 cm, causing capsular bulge with upper pole hypertrophy, with a possible diagnosis of lobar nephronia. On the left side, it showed a small kidney (5.3 cm × 2.3 cm) with dilated ureter in its entire length. Computed tomography urography revealed enlarged right kidney (11.2 cm × 6 cm) with the irregular contour. There was decreased nephrographic density in the anterior-mid and lower parenchyma probably due to focal nephronia. Calyceal cut off and hydronephrosis were noted in the anterior-mid and lower pole calyces on the right side with no excretion of contrast even on delayed scans. Two of the cut off calyces in the anterior mid pole and one in the lower pole showed a high density contents and mild wall thickening on delayed scans, which was likely due to exudative fluid or pus. On the left side, it showed atrophic kidney [Figure 1]. No organism was isolated from urine culture. Based on these investigations, the patient was planned for ultrasound guided aspiration of the right renal abscess under local anesthesia. He underwent the procedure well, and the aspirate was sent to the microbiology lab for culture and sensitivity. Postprocedure, he was started empirically on cefoperazone-sulbactam 1g intravenous (IV) 3 times a day. Aspirate culture grew nonlactose fermenting Gram-negative *Bacilli,* which was identified as *S. typhi* by VITEK 2 compact. Serotyping was done to confirm the isolate. This isolate was found to be sensitive to ceftriaxone (MIC ≤ 1 μg/ml), cefoperazone-sulbactam (MIC ≤ 8 μg/ml), trimethoprim/sulfamethoxazole (MIC ≤ 20 μg/ml) but resistant to ciprofloxacin (MIC ≥ 1 μg/ml). As the patient was afebrile and clinically there was no suspicion of enteric fever at presentation, his blood culture was not sent. However, we managed to do the Widal test on his serum sample, which was stored in the lab following renal function tests. Widal came out to be positive for *S. typhi* (O and H antigens in the titer of 1:320). Treatment was continued with IV cefoperazone-sulbactam till the 4th day of his hospitalization as the isolate was sensitive to third generation cephalosporins. Pain and flank tenderness subsided, and the patient was discharged with an advice to take cefixime 200 mg twice daily for 7 days. The patient was asymptomatic on subsequent follow-up visits.

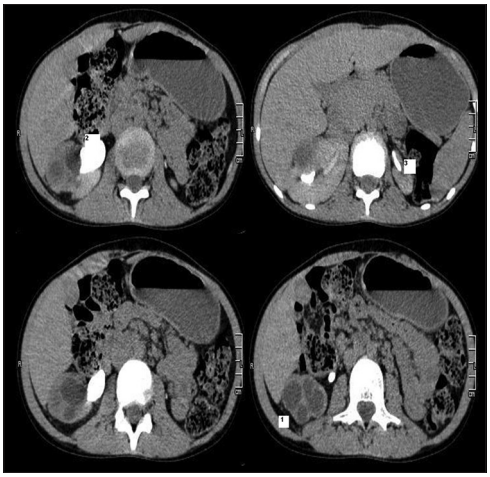

Figure 1: Computed tomography urography showing: (1) Enlarged right kidney with multiple round hypodense lesions (2) Right sided dilated ureter (3) Small left kidney

DISCUSSION

Typhoid is a major health problem, especially in developing countries with poor sanitation where fecal contamination of food and water is common. The most common infections caused by *S. typhi* in humans are gastrointestinal infections, but it is also capable of causing the extra-intestinal infections. It can involve almost any organ in the body producing different manifestations. *Salmonella* can affect the central nervous system, cardiovascular system, pulmonary system, bone, joints, hepatobiliary system, and genitourinary system. There are few reported cases from India on these extra-intestinal infections. In a study by Gokul *et al*., 27 cases of central nervous system infection by *Salmonella* were reported.[9] This organism can also cause myocarditis, endocarditis, and less commonly pericarditis.[8] It has also been reported to cause pleural empyema in an 83-year-old male diabetic patient who presented with fever, productive cough, and difficulty in swallowing.[4] *S. typhi* can cause osteomyelitis by hematogenous spread, contiguous source, or as a result of vascular insufficiency. An association between *S. typhi* osteomyelitis and sickle cell anemia has been seen.[6] *S. typhi* can involve a hepatobiliary system and cases of *S. typhi* liver abscess have been reported in the literature.[1,2]

Genitourinary infection by *S. typhi* is a relatively rare event, even in endemic areas. Predisposing factors for genitourinary involvement include underlying structural or functional abnormalities, calculi, pyelonephritis, dermoid cyst, and renal transplant. *S. typhi* has never been implicated in renal abscess, although renal involvement has been reported.[14] Diagnosis is confirmed by culture of the aspirated pus from the abscess.

Empiric treatment of renal abscess is started with anti-staphylococcal drugs as it is the most common causative agent. Once the culture and sensitivity reports are available, treatment is modified accordingly.[13] *S. typhi*, usually shows good sensitivity to fluoroquinolones, but quinolone resistance has emerged in developing

countries due to the widespread availability of inexpensive fluoroquinolones. Our isolate was also resistant to ciprofloxacin. Third generation cephalosporins can be used in cases showing resistance to fluoroquinolones. Other antibiotics that have been reported to be used successfully are chloramphenicol, co-trimoxazole, and azithromycin. Chloramphenicol should be reserved for the infections caused by *S. typhi* when less toxic antimicrobials are ineffective or contraindicated. In case of perinephric abscess drainage procedure is also required in addition to antibiotics.[15,16] Salmonellosis continues to be a major public health problem in developing countries, therefore, unusual clinical presentations of *Salmonella* should be kept in mind.

Financial support and sponsorship

Nil.

Conflicts of interest

There are no conflicts of interest.

REFERENCES

1. Jorge JF, Costa AB, Rodrigues JL, Girão ES, Luiz RS, Sousa AQ, *et al*. *Salmonella typhi* liver abscess overlying a metastatic melanoma. Am J Trop Med Hyg 2014;90:716-8.
2. Soni PN, Hoosen AA, Pillay DG. Hepatic abscess caused by *Salmonella typhi*. A case report and review of the literature. Dig Dis Sci 1994;39:1694-6.
3. Piplani S, Krishna R, Nandi B, Ganjoo RK, Madan R, Chander BN. Two cases of *Salmonella* splenic abscess. MJAFI 2006;62:77-8.
4. Afridi FI, Farooqi BJ, Hussain A. Pleural empyema due to *Salmonella typhi*. J Coll Physicians Surg Pak 2012;22:803-5.
5. Aslam F, Bhaila I, Nadeem N, Fadoo Z. *Salmonella typhi*-infected lung hydatid cyst. Pediatr Infect Dis J 2005;24:270-2.
6. Declercq J, Verhaegen J, Verbist L, Lammens J, Stuyck J, Fabry G. *Salmonella typhi* osteomyelitis. Arch Orthop Trauma Surg 1994;113:232-4.
7. Shanthi M, Sekar U, Sridharan KS. Septic arthritis of hip caused by *Salmonella typhi*: A case report. Case Rep Infect Dis 2012;2012:464527.
8. Singh VP, Jain V, Sharma A, Agarwal AK. *Salmonella typhi* endocarditis. J Indian Acad Clin Med 2010;11:49-50.
9. Gokul N, Chandramuki A, Ravikumar R, Khanna N. *Salmonella* infections of central nervous system. NIMHANS J 1988;6:115-9.
10. Olson ES, Asmussen T, Vicca AF, Osborn DE. A case report of renal abscess caused by *Salmonella virchow* phage type 1 associated with a papillary renal cell carcinoma. J Infect 1999;38:56-7.
11. Hashino S, Imamura M, Tanaka J, Noto S, Kobayashi S, Kasai M, *et al*. Renal *Salmonella enteritidis* abscess in a patient with severe aplastic anemia after allogeneic stem cell transplantation. Bone Marrow Transplant 1996;18:807-8.
12. Dravid M, Joshi BN. Renal abscess due to *Salmonella typhimurium*. Indian J Pediatr 1990;57:586-8.
13. D'Cruz S, Kochhar S, Chauhan S, Gupta V. Isolation of *Salmonella paratyphi* a from renal abscess. Indian J Pathol Microbiol 2009;52:117-9.
14. Duncan ME, Perine PL, Krause DW. Pelvic infection caused by *Salmonella typhi*. Two unusual cases. East Afr Med J 1981;58:703-7.
15. Renuka K, Kapil A, Kabra SK, Wig N, Das BK, Prasad VV, *et al*. Reduced susceptibility to ciprofloxacin and gyra gene mutation in North Indian strains of *Salmonella enterica* serotype typhi and serotype paratyphi A. Microb Drug Resist 2004;10:146-53.
16. Chinh NT, Parry CM, Ly NT, Ha HD, Thong MX, Diep TS, *et al*. A randomized controlled comparison of azithromycin and ofloxacin for treatment of multidrug-resistant or nalidixic acid-resistant enteric fever. Antimicrob Agents Chemother 2000;44:1855-9.