

# Subcutaneous Mercury Injection by a Child: A Histopathology Case Report

Deepti Sukheeja, Pankaj Kumar<sup>1</sup>, Maneesh Singhal<sup>1</sup>, Arulselvi Subramanian

Departments of Laboratory Medicine, and <sup>1</sup>Surgery, Jai Prakash Narayan Apex Trauma Centre, All India Institute of Medical Sciences, New Delhi, India

**Address for correspondence:** Dr. Arulselvi Subramanian, E-mail: arulselvi.jpncat@gmail.com

## ABSTRACT

Intentional subcutaneous injection of mercury by mentally healthy children is rare. Usually, it is seen as a part of suicidal attempt in severely depressed patients or by athletes to enhance their performance. We report a case of a 15-year-old child, inspired by a movie, who deliberately self-injected mercury subcutaneously into his forearm that led to the formation of a non-healing ulcer. Histopathology of the biopsy confirmed the diagnosis. A surgical procedure was thereby performed to treat the ulcer and reduce the blood and urinary levels of mercury. However, the patient did not develop clinical signs of chronic poisoning, proving that subcutaneous mercury injection has a low risk of systemic toxicity, and that histopathology plays an important role in diagnosis.

**Key words:** Injection, mercury, subcutaneous

## INTRODUCTION

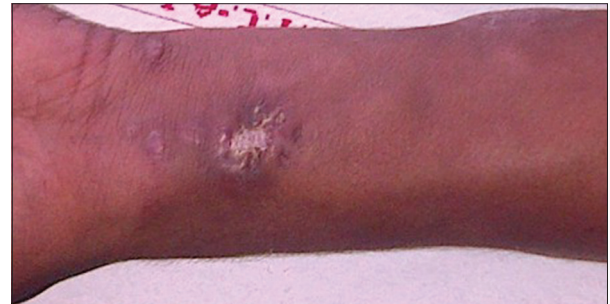Mercury toxicity can occur in various ways depending on the forms of mercury, the amount of exposure and the route of entry into the body. There has been an abundance of published data regarding its toxicity. Toxicity from contaminated fish in Minamata, Japan, has been widely reported, wherein poisoning from methyl mercury has been referred to as Minamata disease.<sup>[1]</sup> Self subcutaneous injection of elemental mercury is rare but well described, mainly used by those who are in suicidal depression or who seek to improve sexual or athletic performance. Although it generally does not lead to systemic Effects,<sup>[2]</sup> exceptions can occur when it inadvertently gets absorbed intravenously, leading to systemic toxicity.

We hereby report and discuss the histopathology of a case of intentional subcutaneous mercury injection

by a child leading to multiple ulcers and nodules formation in the wrist. Because injecting mercury locally does not lead to signs and symptoms of toxicity, adequate history from the patients is required, in the absence of which histopathology plays an important role in diagnosis.

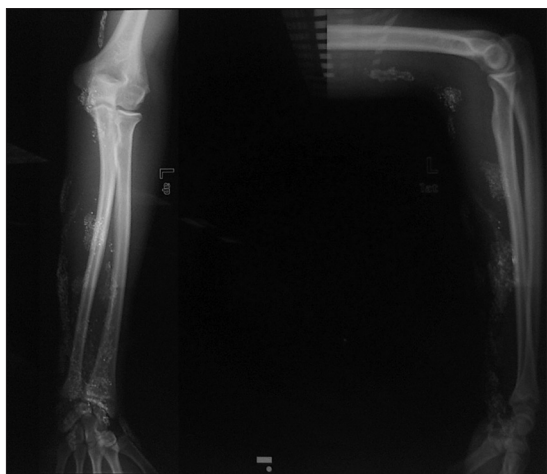## CASE REPORT

A 15-year-old male child presented to our tertiary care trauma center with multiple non-healing ulcers on the left forearm since 2 months following trauma by a sharp object [Figure 1]. His general physical examination was unremarkable with stable vital



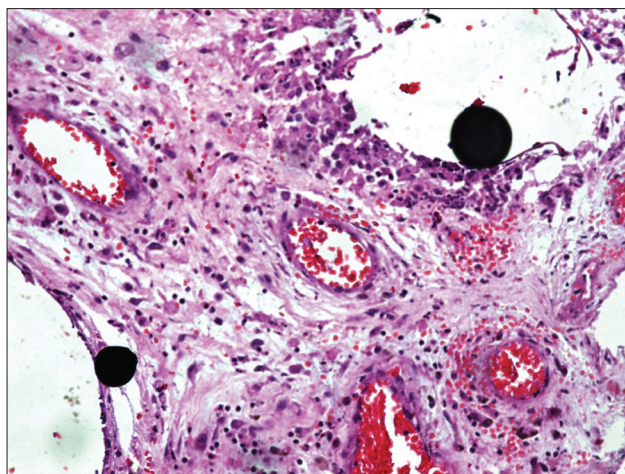
**Figure 1:** Photograph showing multiple ulcers and nodules over the forearm

Access this article online	
<b>Quick Response Code:</b> 	<b>Website:</b> <a href="http://www.jlponline.org">www.jlponline.org</a>
	<b>DOI:</b> 10.4103/0974-2727.129095



**Figure 2:** X-ray (anteroposterior and lateral views) showing multiple subcutaneous radioopaque deposits

signs. On local examination, there were multiple ulcers, the largest of size  $2 \times 2$  cm over the distal forearm and nodular lesions over the volar aspect of the forearm and lower arm. The nodules were firm and fixed. There was no local lymphadenopathy. His systemic examination was normal. He was under treatment by a surgeon for non-healing ulcer in a peripheral hospital for the last 1.5 months. Discrepancy between history and physical examination prompted surgeons to suspect substance abuse; therefore, a psychiatric referral was performed. This revealed intentional subcutaneous injection of mercury at least thrice, obtained after breaking a thermometer and a sphygmomanometer. The patient was inspired by the movie X-Man Wolverine and wanted to simulate a character called “Mercury.” Interestingly, he had a past history of multiple bites by spiders to simulate Spiderman. Surprisingly, he had no other psychiatric problems and had a normal IQ. Complete biochemical and toxicology evaluations, including elemental mercury level in blood, urine and nails, were performed. X-ray and non-contrast computed tomography scan of the left upper limb was performed, which showed a diffuse area of multiple, subcutaneous radioopaque deposits up to the lower arm [Figure 2]. A Doppler study was performed to rule out any intravascular deposit, but all major vessels were patent, which led to the conclusion that the patient had injected mercury subcutaneously. Mercury was not detected in the serum and nails. However, the concentration of mercury in the urine was 0.139 mg/L (normal range = 0.020 mg/L). The chest X-ray was normal. Excision of the skin and subcutaneous tissue containing granuloma was carried out under X-ray guidance. The skin was left open and a split-thickness skin graft was applied later and the tissue was submitted for biopsy. The surgical wounds healed uneventfully.



**Figure 3:** Hematoxylin and eosin-stained section ( $\times 10$ ) showing mercury droplets in the cystic spaces surrounded by chronic inflammatory cells

The pathologic specimen consisted of three tissue pieces measuring  $2 \times 3$  cm,  $1 \times 1$  cm and  $1 \times 0.5$  cm, comprising skin and subcutaneous tissue. The cut-section revealed hemorrhagic and necrotic areas with exuding shiny droplets of mercury. The tissues were processed and microscopic sections were stained with hematoxylin and eosin stain.

The microscopy showed epidermis along with dermis showing multiple cystic spaces containing concentric droplets of mercury, which appeared purplish-black in color. Surrounding these spaces were foreign body-type giant cells, histiocytes, lymphocytes and plasma cells [Figure 3].

Serum and urinary mercury levels were repeated 1 month after follow-up. The patient is on regular follow-up and there are no signs of systemic absorption until now.

## DISCUSSION

Use of metallic mercury is seen in thermometers, manometers, batteries, dental amalgams, fluorescent light bulbs, sphygmomanometers, gas regulators, topical medications, cathartics, substances used in magico-religious practices and some paints. In the 19<sup>th</sup> century, teething powders containing calomel (mercurous chloride), anthelmintics and mercury compounds as a part of fungicides and disinfectants were in wide use. Mercury vapor exposure for a long enough time period at a high enough concentration will lead to organ damage in the brain, kidney and lungs. Overall, inhalation of the vaporized elemental mercury is much more hazardous to human health than ingestion of the liquid form. Although rare, self-injection of elemental mercury is well described and is often part

of a suicide attempt, or may be used by drug abusers.<sup>[3]</sup> Other unusual incidences of self-injection of mercury include a 14-year-old boxer who received an injection of metallic mercury thinking that it would strengthen his sports performance and subjects who believe that mercury injections will improve sexual powers. Furthermore, an individual may self-inject with mercury repeatedly;<sup>[4,5]</sup> health service workers are somewhat overrepresented in such cases.<sup>[6]</sup> Mercury poisoning is not uncommon in children. Yilmaz *et al.* have reported chronic mercury poisoning in two siblings aged 7-13 years who ingested mercury while playing with mercury-containing batteries.<sup>[7]</sup> Zhu *et al.* have described accidental mercury injection in a 1-year-old male infant who was injured by a broken mercury thermometer while taking his axillary temperature, which penetrated into his left subaxillary soft tissue.<sup>[8]</sup>

In previously reported cases, when elemental mercury was injected directly into the tissues, a granulomatous foreign body giant cell reaction was typically observed, with a mixed inflammatory cellular infiltrate composed of polymorphonuclear leukocytes, lymphocytes, histiocytes, plasma cells and occasional eosinophils, similar to our case. Metallic mercury in tissue sections appears as dark, opaque globules, usually spherical and of varying size and number.<sup>[9-11]</sup> A study conducted by Al-Saleh on mice proves that chronic high-dose topical application of mercury-containing skin-lightening creams gets deposited in the brain, liver and kidney tissues, leading to histopathological changes such as congestion, intracellular vacuolization, lymphoid hyperplasia, lymphatic infiltration between tubules and multifocal atrophy of glomeruli in the kidney; hyperplasia of Kupffer cells and hepatocytic nuclei with lymphocytic infiltration around the bile ducts and loss of hepatocellular architecture; thinning of the cortical layer of cerebrum, brainstem and cerebellum, loss of neurons with reactive proliferation of glial cells, microcavitation, vascular congestion, petechial hemorrhage and edema in the brain.<sup>[12]</sup>

Several studies regarding misuse of mercury leading to poisoning have been published in the past years. To the best of our knowledge, the present study however is few of those that discuss the histopathology of skin biopsy with subcutaneous injection of mercury.

Diagnosis of mercury injection is easy if its history is available. In the absence of a history, its typical

histopathological findings can be useful although the mercury droplets can be easily mistaken for artifacts. However, electron microscopy showing spherical globules measuring 400-900 nm in diameter can be confirmatory. Although subcutaneous injection has a low risk of systemic toxicity, it may however depend on the total dose of mercury injected. Diagnosis and complete removal of the lesion containing mercury droplets can rapidly decrease its systemic absorption and its effects. Chelating therapy, if required, and long-term follow-up of such patients along with psychiatric consultation should be performed.

## ACKNOWLEDGMENTS

The authors would like to thank the technicians of JPNATC: Mrs. Meenakshi, Mr. Lian and Mr. Pawan, who helped in the processing of the histopathology samples.

## REFERENCES

1. McAlpine D, Araki S. Minamata disease: An unusual neurological disorder caused by contaminated fish. *Lancet* 1958;2:629-31.
2. Boyd AS, Seger D, Vannucci S, Langley M, Abraham JL, King LE Jr. Mercury exposure and cutaneous disease. *J Am Acad Dermatol* 2000;43:81-90.
3. Hohage H, Otte B, Westermann G, Witta J, Welling U, Zidek W, *et al.* Elemental mercurial poisoning. *South Med J* 1997;90:1033-6.
4. Murray KM, Hedgepeth JC. Intravenous self administration of elemental mercury: Efficacy of dimercaprol therapy. *Drug Intell Clin Pharm* 1988;22:972-5.
5. Burton EM, Weaver DL. Repeated systemic mercury embolization. *South Med J* 1988;81:1190-2.
6. Rodrigues IM, Hopkinson ND, Harris RI. Pulmonary embolism associated with self-administration of mercury. *Hum Toxicol* 1986;5:287-9.
7. Yilmaz C, Okur M, Geylani H, Çaksen H, Tuncer O, Ataş B. Chronic mercury poisoning: report of two cases. *Indian J Occup Environ Med.* 2010;14:17-9.
8. Zhu QH, Chen Y, Zeng QL, Zhao JB. Fluoroscopy-guided percutaneous aspiration of metallic mercury in soft tissues. *Clin Radiol* 2012;67:83-5.
9. Rachman R. Soft-tissue injury by mercury from a broken thermometer. A case report and review of the literature. *Am J Clin Pathol* 1974;61:296-300.
10. Lupton GP, Kao GF, Johnson FB, Graham JH, Helwig EB. Cutaneous mercury granuloma. A clinicopathologic study and review of the literature. *J Am Acad Dermatol* 1985;12:296-303.
11. Sau P, Solivan G, Johnson FB. Cutaneous reaction from a broken thermometer. *J Am Acad Dermatol* 1991;25:915-9.
12. Al-Saleh I, Khogali F, Al-Amodi M, El-Doush I, Shinwari N, Al-Baradei R. Histopathological effects of mercury in skin-lightening cream. *J Environ Pathol Toxicol Oncol* 2003;22:287-99.

**How to cite this article:** Sukheeja D, Kumar P, Singhal M, Subramanian A. Subcutaneous mercury injection by a child: A histopathology case report. *J Lab Physicians* 2014;6:55-7.

**Source of Support:** Nil. **Conflict of Interest:** None declared.