

Paravaginal peripheral primitive neuroectodermal tumor: A rare tumor

Samrat Dutta,
Chandan Dasgupta,
Kakoli Choudhury

Department of Radiotherapy,
Medical College, Kolkata,
West Bengal, India

Address for correspondence:

Dr. Dutta Samrat,
Department of Radiotherapy,
Medical College, 88 College Street,
Kolkata - 700 073,
West Bengal, India.
E-mail: drsamratdutta@gmail.com

ABSTRACT

Peripheral primitive neuroectodermal tumor (PNET) of the female genital tract, particularly those in the vaginal and paravaginal region, are extremely rare. A 36-year-old woman presented with clinical features similar to that of a case of cervical fibroid. It was only after surgery that the histopathology suggested it to be a malignant round cell tumour and was CD99 positive. She underwent adjuvant chemotherapy with the Ifosfamide and Etoposide alternating with Vincristine, Doxorubicin, and Cyclophosphamide regime and radical radiotherapy. She is disease free at 12 months of follow-up. The importance of immunostaining and adequate histopathology report lies in the fact that the correct diagnosis thus achieved enabled us to manage a rare case of paravaginal PNET with a multimodality approach.

Key words: *Immunostain, primitive neuroectodermal tumor, vagina*

INTRODUCTION

Primitive peripheral neuroectodermal tumors (PNETs) are a part of the spectrum of neoplastic diseases known as the Ewing sarcoma family of tumors (EFT) and account for 4% of malignancies. Of this percentage, 15% are of extraskeletal or of soft tissue origin.^[1] We present a case of PNET occurring in the paravaginal tissue, which was difficult to diagnose preoperatively. The interesting point here is that this is a rare case and the patient was diagnosed and later treated radically with surgery, chemotherapy, and radiotherapy.

CASE REPORT

The present case is a 36-year-old married multiparous woman, who was suffering from intermittent retention of urine for the last 5 months and later presented with a mass coming out of the vagina for past 3 months. She had no complains of bleeding or discharge from vagina and her bowel habits were normal. Her general physical examination was normal. On detailed gynecologic examination, it was found that there was a fleshy smooth

surfaced mass measuring 5×4 cm occupying the vaginal cavity. Per speculum examination could not be done owing to lack of space, and on digital palpation a firm mass was felt at the cervicovaginal region on the right side. The overlying vaginal mucosa was smooth. Per rectal examination was normal. A pelvic ultrasonography (USG) revealed a mass in the pelvic region. Chest X-ray, upper abdominal USG, cystoscopy, and proctoscopy yielded normal findings. The overall clinical impression was of a cervicovaginal mass with the provisional diagnosis of a cervical fibroid. Subsequently, she was taken up for surgery. Intraoperative findings revealed a pelvic tumor in the paravaginal region, which was adherent to the surrounding region, and hence was taken out piecemeal. Ultimately, she underwent total abdominal hysterectomy and bilateral salpingo oophorectomy and retroperitoneal lymph node dissection owing to the suspicion of a malignant growth. Postoperative histopathology reported that cervix, vagina, endometrium, tubes, and ovaries were normal. The histology of the tumor was consistent with malignant round cell tumor [Figure 1]. Immunostaining with desmin and cytokeratin was negative but for CD99 it was positive, ultimately favoring the diagnosis of Primitive Neuroectodermal tumor [Figure 2]. The patient underwent adjuvant chemotherapy with three cycles of Ifosfamide and Etoposide alternating with Vincristine, Doxorubicin, and Cyclophosphamide (VAC/IE). After three cycles, she was treated with pelvic radiotherapy to a total dose of 50 Gy in 25 # over 5 weeks. Post radiotherapy she again received three cycles of the chemotherapy. After treatment completion, she had no complains. Her pelvic examination

Access this article online

Quick Response Code:



Website:
www.ijmpo.org

DOI:
10.4103/0971-5851.92823

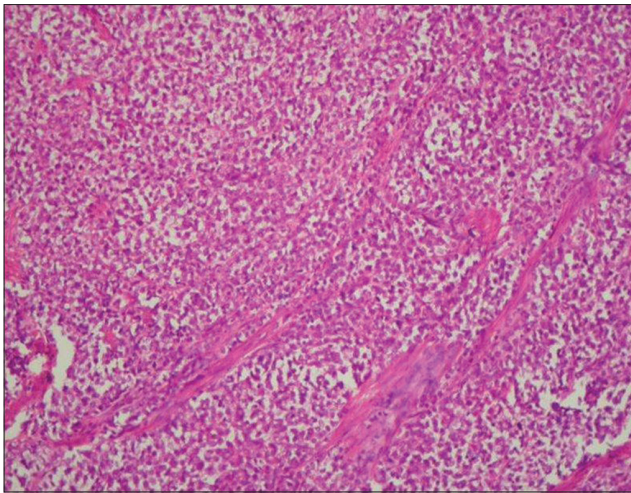


Figure 1: Low power view of tumor

is normal; chest X-ray and whole abdominal and pelvic CT reveals no new lesion or abnormality. She is disease-free 12 months after diagnosis.

DISCUSSION

The PNETs are collectively described as part of the Ewing sarcoma family of tumors. The most common site of PNET in the female genital tract is the ovary. The uterine corpus is the next most common site, with the cervix, vulva, and vagina rarely being the primary site.^[2] A review of the literature revealed only seven previously reported possible cases in the vagina, most of which have not had molecular confirmation.^[3-5]

The differential diagnosis of vaginal and paravaginal tumors include benign tumors such as cervical fibroids and malignant growths like carcinoma. Among the rare variants of vaginal and paravaginal tumors are melanomas, sarcomas, lymphomas. Lymphomas most closely mimic PNETs with sheets of cytologically malignant small cells without evidence of glandular or squamous differentiation. The absence of epithelial markers like cytokeratin excludes a diagnosis of carcinoma, and to a lesser extent, small cell neuroendocrine carcinomas. Although MIC2 is not specific for Ewing sarcoma/PNET and is expressed in a wide range of unrelated tumors, staining with CD99, as in the present case, provides support for the diagnosis of these tumors, if used with other features.

In early days, management decisions for such tumors revolved around optimal local surgical treatment, followed by additional treatment such as irradiation and/or chemotherapy. More recently, however, neo-adjuvant chemotherapy followed by local treatment has been favored because of improved results by the addition of

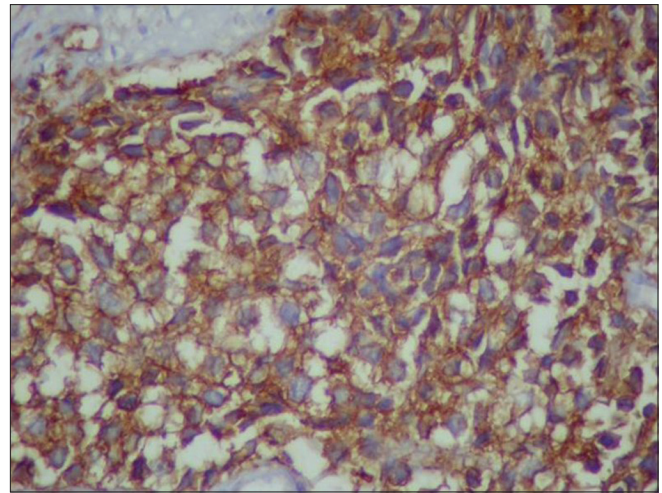


Figure 2: CD99-positive cells

systemic therapy. The limited prognosis of such patients due to the development of metastatic disease has likewise been improved by using a multimodality treatment and sequencing of different treatment strategies. Owing to its location in the pelvis, the question arises whether radical complete surgery is possible. In case of a purely soft tissue origin, due consideration must be given regarding its extent. The present reported case had a clinical picture quite similar to that of a cervical fibroid. Hence, with the provisional diagnosis of a benign lesion, the patient actually did not undergo any preoperative evaluation regarding the histology, nor she underwent any radiological tests like CT scan to know the extent of the lesion.

However, in our opinion, it indicates that tumor in this location gives symptoms at an early stage. This kind of a presentation though poses a diagnostic dilemma to the clinician but at the same time provokes a surgeon to operate early, thus leading to an early diagnosis postoperatively.

Recent data show that the addition of ifosfamide and etoposide to a standard regimen of vincristine, doxorubicin, and cyclophosphamide significantly improves the outcome for patients with non-metastatic Ewing sarcoma or primitive neuroectodermal tumor.^[6] Our patient has now completed radical surgery, adjuvant radiotherapy, and chemotherapy with the regimen of VAC/IE with no evidence of disease 12 months after completion of therapy. Her response supports the use of multimodal therapy for this unusual diagnosis.

The 5-year disease-free survival is 24-80% for localized disease,^[7] with smaller resectable lesions; ie, the reported cases with vaginal location had a better prognosis. For other gynecologic locations, such as uterus, survival was related to stage. Two women with stage I disease were alive 5 years after diagnosis; however, two women with stage II and IV

tumors died 6 and 12 months after diagnosis, respectively.^[8] One patient having disease in the cervix was disease-free 18 months after diagnosis and the other died 4.2 years after diagnosis.^[9]

In summary, the present case is the probably the first case reported of PNET of the paravaginal region, and this was possible only because of proper histopathological report and immunostain.

According to studies with these tumors in other locations, they should be treated with adequate surgery followed by adjuvant chemotherapy, similar to that of Ewing sarcoma, and radiation therapy. Prognosis is related to volume of tumor, age at diagnosis, and stage.

REFERENCES

1. Angervall L, Enzinger FM. Extraskeletal neoplasm resembling Ewing's sarcoma. *Cancer* 1975;36:240-51.
2. Blattner JM, Gable P, Quigley MM, McHale MT. Primitive Neuroectodermal tumour of uterus. *Gynecol Oncol* 2007;106: 419-22.
3. McCluggage WG, Sumathi VP, Nucci MR, Hirsch M, Dal Cin P, Wells M, *et al.* Ewing family of tumours involving the vulva and vagina: Report of a series of four cases. *J Clin Pathol* 2007;60:674-80.
4. Liao X, Xin X, Lü X. Primary Ewing's sarcoma-primitive neuroectodermal tumor of the vagina. *Gynecol Oncol* 2004;92:684-8.
5. Al-Tamimi H, Al-Hadi AA, Al-Khater AH, Al-Bozom I, Al-Sayed N. Extraskeletal neuroectodermal tumour of the vagina: A single case report and review. *Arch Gynecol Obstet* 2009;280:465-8.
6. Grier HE, Krailo MD, Tarbell NJ, Link MP, Fryer CJ, Pritchard DJ, *et al.* Addition of ifosfamide and etoposide to standard chemotherapy for Ewing's sarcoma and primitive neuroectodermal tumor of bone. *N Engl J Med* 2003;348:694-701.
7. Farley J, O'Boyle JD, Heaton J, Remmenga S. Extrasosseous Ewing's sarcoma of the vagina. *Obstet Gynecol* 2000;96:832-4.
8. Daya D, Lukka H, Clement PB. Primitive neuroectodermal tumors of the uterus: A report of four cases. *Hum Pathol* 1992;23: 1120-9.
9. Cenacchi G, Pasquinelli G, Montanaro L, Cerasoli S, Vici M, Bisceglia M, *et al.* Primary endocervical extrasosseous Ewing sarcoma/PNET. *Int J Gynecol Pathol* 1998;17:83-8.

How to cite this article: Dutta S, Dasgupta C, Choudhury K. Paravaginal peripheral primitive neuroectodermal tumor: A rare tumor. *Indian J Med Paediatr Oncol* 2011;32:171-3.
Source of Support: Nil, **Conflict of Interest:** None declared.

New features on the journal's website

Optimized content for mobile and hand-held devices

HTML pages have been optimized of mobile and other hand-held devices (such as iPad, Kindle, iPod) for faster browsing speed.

Click on **[Mobile Full text]** from Table of Contents page.

This is simple HTML version for faster download on mobiles (if viewed on desktop, it will be automatically redirected to full HTML version)

E-Pub for hand-held devices

EPUB is an open e-book standard recommended by The International Digital Publishing Forum which is designed for reflowable content i.e. the text display can be optimized for a particular display device.


Click on **[EPub]** from Table of Contents page.

There are various e-Pub readers such as for Windows: Digital Editions, OS X: Calibre/Bookworm, iPhone/iPod Touch/iPad: Stanza, and Linux: Calibre/Bookworm.

E-Book for desktop

One can also see the entire issue as printed here in a 'flip book' version on desktops.

Links are available from Current Issue as well as Archives pages.

Click on  View as eBook