Article published online: 2022-03-02

Images in Clinical Oncology

SYSTEMIC AMYLOIDOSIS ASSOCIATED WITH MYELOMA

Fig. 1

Fig. 2

Fig. 3

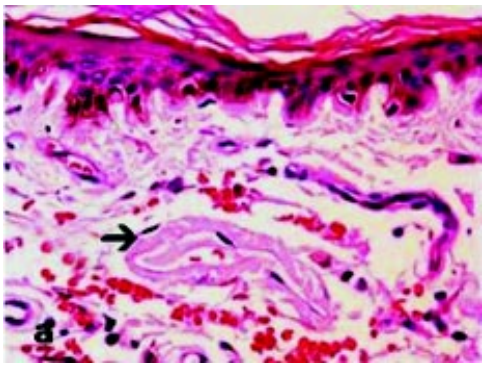

Fig-4 High power photomicrograph shows pale eosinophilic extracellular amorphous deposits in papillary dermis as well as in dermal vessel wall resulting in increased vessel wall thickness [arrow] (Fig a, H & E x 400).

Mr. SS, 60 years old male presented with purpuras, petechiae, ecchymotic patches (fig 1-3) over the face, chest, shoulders and back since one and half years along with history of swelling of limbs and breathlessness. Clinical examination revealed ECOG performance status of 3, skin lesions, hepatomegaly and pedal oedema. Investigations showed grade 1 anaemia, normal renal and liver functions tests. Bone marrow aspirate was suggestive of 18% plasma cells. Skeletal survey revealed multiple lytic lesions in skull and mandible. Protein electrophoresis (SPE) showed sharp and dense M band (2.1g/dl) in serum and narrow M band in urine. Abdominal fat biopsy showed normal blood vessels with no amyloid deposits. Skin biopsy (fig-4) showed amyloid deposits in dermis and vessels which showed apple green birefringence on Congo Red stain under polarized light features compatible with amyloidosis. Echocardiography showed thickened interventricular septum (22mm) with concentric left ventricular hypertrophy. He was diagnosed as myeloma associated with systemic amyloidosis of skin and heart and is currently on treatment with melphalan and dexamethasone.

Concurrent amyloid deposits with myeloma can be identified either at presentation or during course of myleoma in 10-15% patients. Myeloma associated amyloidosis especially with cardiac involvement represents poor prognosis with very limited treatment options.

Aarti Gupta, Saurabh Radhakrishnan and Prasenjit Das*
Department of Medical Oncology and Pathology*
All India Institute of Medical Sciences,
New Delhi-110029
Email : aartigupta06@gmail.com