

Case Report-II

Myofibroblastoma of Breast

PRASENJIT DAS, ALOK SHARMA, RAMAN ARORA AND M. K. SINGH

ABSTRACT

Myofibroblastoma of breast is an extremely rare mesenchymal lesion comprising of myofibroblasts. Less than 70 cases have been reported in the literature. Though many histological variants are known, characteristic morphological, cytologic, immunohistochemical and ultrastructural features help to differentiate it from other spindle cell lesions of breast. Here we report an epitheloid variant of myofibroblastoma breast in a 55-year-old female. Though CD34 showed only focal positivity, typical morphological and other immunohistochemical features helped in arriving at the diagnosis.

INTRODUCTION

Myofibroblastoma is an unencapsulated benign spindle cell tumour of mesenchymal stroma comprising of myofibroblasts. It occurs both in males and females with an age range of 40- 80 years.¹ Since its first description by Wargotz et al, less than 70 cases have been reported in literature.² This uncommon lesion has been described in the soft tissues, breast, skin, lymph nodes and suprasellar regions.³

Myofibroblasts was first described in granulation tissue by Gabbani et al.⁴ They are spindle to fusiform cells with features of both myogenic and fibroblastic differentiation. They can be differentiated from the fibroblasts by morphology, distribution pattern,

immunohistochemical expression and ultrastructural features. Myofibroblasts can be identified in various benign lesions as fibromatosis, myofibromatosis, inflammatory myofibroblastic tumour, spindle cell lipomas and in various sarcomas and metaplastic carcinomas.¹

We report this case of myofibroblastoma of breast in a 55 year old female who previously could not be diagnosed specifically on fine needle aspiration and tru-cut biopsy.

This report adds to the existing spectrum of myofibroblastoma in terms of morphological diversity, interesting immunohistochemical expression pattern and behavior.

CASE: A 55-year-old woman presented with a 3 x 3 cm lump in lower inner quadrant of her right breast for one week. It was firm and mobile and was fixed neither to the underlying muscles nor the overlying structures. Nipple and areola of the same side was within normal limits and the axilla was normal. The woman had her first pregnancy 25 years ago and last child was born 19 years ago. Clinically, a diagnosis of lymphoma/ carcinoma was made due to short duration of presentation

Routine laboratory and biochemical tests were normal. Mammogram of the breast revealed a large well-defined lesion in the lower inner quadrant of mixed density, showing both lipomatous and soft tissue components. No microcalcification or architectural distortion was noted. Sonography showed an echogenic lesion with distal shadowing. The radiological differential diagnosis was a fibroadenolipoma or

Department of Pathology All India Institute of Medical Sciences
New Delhi, India
Correspondence to: **PRASENJIT DAS**
E-mail: dr_prasenpi@yahoo.co.in

a fibroadenoma. Subsequently, a fine needle aspiration showed clusters of benign ductal cells. A trucut biopsy showed benign fibrocollagenous tissue fragments and occasional benign terminal duct-lobular units. An excision biopsy of the nodule was performed under local anesthesia. On histopathological examination, it was a 3 x 3 cm well circumscribed round mass, firm in consistency. Cut section was gray-white and homogenous. Hematoxylin and eosin stained section of the mass showed haphazardly arranged short fascicles of spindle to epithelioid cell separated by thick eosinophilic collagen bands. The margin of the growth was pushing type and showed presence of few mature adipocytes at the periphery. The cells had bipolar plump vesicular nuclei with nuclear grooves at places. The predominant cell morphology was epithelioid type (fig. 1). Mitotic figures were sparse (0-1/10 HPF). At areas, few hyalinized vessels and collection of lymphocytes were noted. No intratumoural duct lobular units were identified.

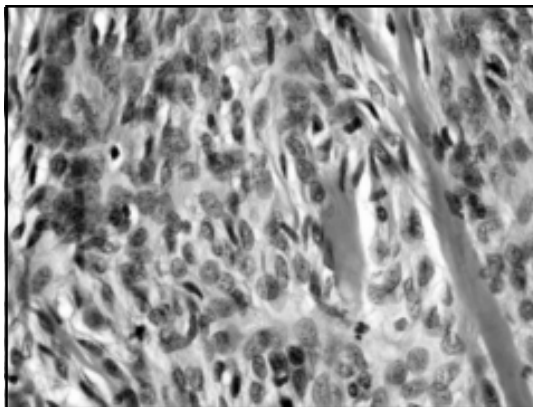


Fig 1: Epithelioid cells interspersed with collagen fibers. Nuclear grooves are noted (H & E X 200).

The tumour cells were immuno positive for vimentin, desmin, smooth muscle actin, estrogen (fig. 2) and progesterone receptors. In addition, focal positivity for CD34 (fig. 3) and bcl 2 proteins was noted. The tumour cells were negative for S-100 protein and epithelial membrane antigen. With elastic Von Gieson's stain the collagen bundles stood out as zig-zag reddish-brown bands.

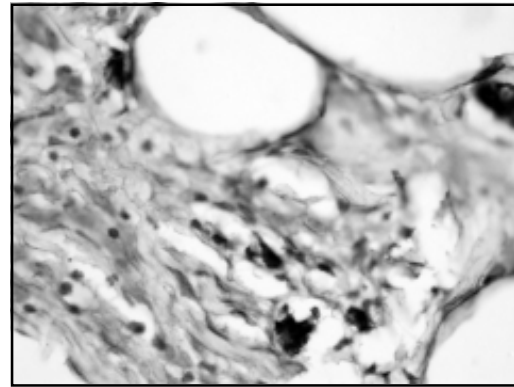


Fig 2: The tumour cells are strongly positive for estrogen receptors (IHC x 100).

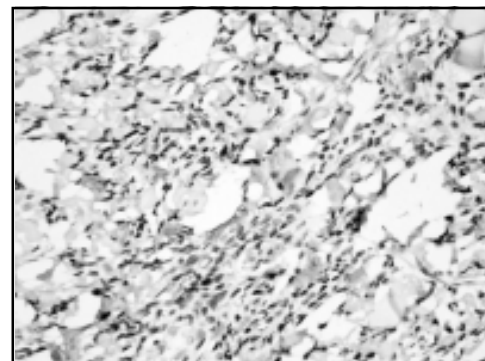


Fig 3: The tumour cells are only focally positive for CD 34 (IHC x 200)

DISCUSSION

Myofibroblastoma of the breast is an extremely rare lesion with less than seventy cases reported in literature. First description of this entity was given by Wargotz et al [1987], who reported a series of 16 cases with characteristic histological features and showed a distinct male preponderance.² Later reports described an almost equal incidence of myofibroblastomas amongst both sexes.^{1,5}

The usual clinical presentation is unilateral painless lump, not adherent to overlying or underlying structures. Bilaterality and unilateral multicentricity are rare.⁶ Radiologically, they are homogenous, lobulated and well circumscribed lesions, typically lacking microcalcification.¹ Ultrasonographic findings cannot often differentiate it from fibroadenoma.

Microscopically, five distinct subtypes have been described: classical, collagenized, epitheloid, cellular and infiltrative.⁷ Mammary ducts and lobules are absent in typical histological subtype and the adjacent breast parenchyma may form a pseudocapsule. Occasionally, myxomatous change of the stroma, multinucleated giant cells, cartilaginous or osseous components and nuclear pleomorphism may be identified within the lesion; and, presence of these components do not necessarily mean a malignancy.^{1,7,8} Mitotic figures also vary, and in a typical case of mammary myofibroblastoma a mitotic activity varying from 0-6/ 10 HPF is usually described. Mitotic activity > 6/ 10 HPF, along with cellular pleomorphism and infiltrative margins are considered as features of myofibroblastic sarcoma.^{9,10}

Before considering this lesion, the other lesions with myofibroblastic differentiation, e. g. fasciitis, nodular fasciitis, myofibroma/myofibromatosis or myofibroblastic sarcoma should be thoroughly ruled out considering the site of tumour, histomorphology and immunohistochemical findings. Fibromas, though a close morphological mimicker of myofibroblastoma, are rare in breast and show infiltrative margins. Nodular fasciitis, though may occur in any part of the body, their occurrence in breast is rare. Keloid like collagen, varying cellularity and infiltrative margins help to differentiate these from myofibroblastomas. Myofibroma/ myofibromatosis is common in upper half of body and more closely mimic hemangiopericytomas.¹¹ Myofibroblastic sarcomas may resemble other sarcomas such as malignant fibrous histiocytoma due its marked pleomorphism. Immunohistochemical stains for fibronectin or type IV collagen are helpful to show myofibroblastic differentiation.⁹

Majority of the myofibroblastomas are immunoreactive for CD34, desmin, smooth muscle actin and vimentin and are negative for cytokeratin and S-100. Variable nuclear positivity for estrogen, progesterone and androgen receptors has been described in the literatures like in our case.^{1,12,13} The epitheloid variant may show negativity or only focal

positivity for CD 34.^{1,13} In our case, the predominant pattern was epitheloid and CD 34 was only focally positive. A few studies describe the ultrastructural features of this lesion to be similar to leiomyoma or myogenic stromal tumours.¹⁴ However, there are studies which showed no expression of H- caldesmone (smooth muscle marker).⁵ Fine needle aspiration may pose diagnostic difficulties. The reported cytological features include clusters and isolated cells which intimately adherent with extracellular stroma. The cells can be spindle, round or epitheloid. Nuclear grooves may or may not be found.¹⁵ Mast cells are frequently seen in cytology smears.¹⁶ In our case the aspiration smears showed non-specific findings. However, aspiration of the myofibroblastoma variants described previously may show cytologically atypical cells and may lead to a misdiagnosis of malignancy. Though a very short history led to a clinical assumption of malignancy, findings of ultrasonography and mammography without microcalcification prevented an initial extensive surgery in this case.

Thus, regardless of patient's age any breast lesion with spindle cell morphology should be correlated with clinical, radiological, cytological findings and thereafter a further plan management should be decided. Myofibroblastoma behaves in a benign fashion and excision biopsy is usually adequate for this tumour. No recurrences or metastasis are described in the literature. In the present case no recurrence or metastases have been noticed 8 months after lumpectomy.

REFERENCES:

1. Fattaneh A, Tavassoli, Peter Develee. *World Health Organization Classification of tumours; 5. Pathology and Genetics of tumours of the Breast and female Genital Organs.* IARC Press. Lyon, 2003.
2. Wargotz ES, Weiss SW, Norris HJ. *Myofibroblastoma of breast: sixteen cases of a distinctive benign mesenchymal tumour.* *Am J Surg Pathol.* 1987;11:493-502.
3. Shinjima N, Ohta K, Yano S, Nakamura H et al. *Myofibroblastoma in the suprasellar region. Case report.* *J Neurosurg.* 2002;97(5):1203-7.
4. Gabbani G, Ryan GB, Majno G. *Presence of modified fibroblasts in granulation tissue and their possible role in wound contraction.* *Experientia,* 1971;27:549-50.

5. Margo G, Gurrera A, Bisceglia M. H-Caldesmon expression in myofibroblastoma of breast: evidence supporting the distinction from leiomyoma. *Histopathology*, 2003;42:233-38.
6. Hamele-Bena D, Crano ML, Scitto et al. Uncommon presentation of mammary myofibroblastoma. *Hum Pathol* 1996;9:786- 90.
7. Rosen PP. Myofibroblastoma. Rosen PP, In Rosen's *Breast Pathology*, 2nd edition. New York: Lippincott Williams & Wilkins 2001:266- 806.
8. Fukugama M, Ushigome S. Myofibroblastoma of breast with divergent differentiation. *Arch Pathol Lab Med* 1997;121:599-603
9. Lucin K, Mustac E, Jonjic N. Breast sarcoma showing myofibroblastic differentiation. *Virchows Arch* 2003;443:222-24.
10. Gocht A, Bosmuller HC, Bassler R, et al. Breast tumours with myofibroblastic differentiation: clinicopathological observations in myofibroblastoma and myofibrosarcoma. *Pathol Res Pract* 1999;195:1-10.
11. Fletcher C D M, Unni K K, Mertens F (Eds). *The WHO classification of tumours. Pathology and Genetics of tumours of soft tissue and bone*. IARC press: Lyon 2002. pp 50.
12. Morgan MB, Pitha JV, myofibroblastoma of the breast revisited: an etiological association with androgens: *Hum Pathol* 1998;29:347- 51.
13. Deligeorgi-Politi H, Kontozoglou T, Joseph, et al. Myofibroblastoma of the breast: Cytologic, histologic, immunohistochemical and ultrastructural findings in two cases with differential cellularity. *Breast* 1997;3:365- 71.
14. Taccagni G, Rovere F, Masullo M et al. Myofibrosarcomas of breast. Review of literature on myofibroblastic tumours and criteria for defining myofibroblastic differentiation. *Am J Surg Pathol* 1997;21:489-96.
15. Sharma A, Sen AK, Chaturvedi NK et al. Myofibroblastoma male breast: a case report. *Indian J Pathol Microbiol* 2007; 50: 326-28.
16. Powari M, Srinivasan R, Radotra BD. Myofibroblastoma of male breast: A diagnostic problem on fine needle aspiration cytology. *Diag Cytopathol* 2002;26:290- 93.

