Article published online: 2022-03-02

Original Article

Epstein-Barr Virus in Gastric Lymphoma- An Indian Perspective

ABHAY SOOD, ABHITA BRAGANZA AND RAJALAKSHMI T

ABSTRACT

Background : Primary Gastric Non-Hodgkin's Lymphomas (NHL) are being increasingly encountered in the recent years. While the role of Helicobacter pylori (H. pylori) has been explored in its causation, some studies have suggested the role of the Epstein - Barr virus (EBV). However data from India is not readily available and this prompted us to study the morphology of primary gastric NHL, the prevalence of EBV infection in primary Gastric NHL and study its association with H. pylori infection.

Materials & Methods : **A retrospective study. Sixteen biopsy proven cases of primary gastric NHL were studied. Histologic features were reviewed. Immuno-histochemistry for EBV LMP-1 and Modified Giemsa stain to identify Helicobacter pylori were done.**

Results: **There were 10 low-grade and 6 high-grade lymphomas, 15 of them classifiable as Mucosa-associated lymphoid tissue (MALT) type, owing to the presence of lymphoepithelial lesions. 36% of the cases were EBV positive. Only one case showed H. pylori. 4 patients succumbed to the disease, of which 3 were seropositive for HIV.**

Conclusion: **Our pilot study suggests that EBV may have an important role in the pathogenesis of gastric MALT lymphomas. The significance of this association and its prognostic value need to be explored in larger number of patients.**

Department of Pathology, St. John's Medical College, Bangalore – 560034. India
Correspondence to: **RAJALAKSHMI T**
Email: rajnav@gmail.com

INTRODUCTION

Primary Gastric non Hodgkin's lymphoma (NHL) is a common extranodal NHL. The causative association of H. pylori with gastric NHL, particularly of the MALT type has been proven.[1] The largest series of gastrointestinal lymphomas from India has been a study of 75 cases, with poorly differentiated lymphocytic lymphoma being cited as the commonest histologic subtype.[2] Since then, there has been evolution of the concept of MALTomas, and the regression of such tumours following eradication of Helicobacter pylori (H. pylori).[1,3]

Apart from the role of H. pylori, another infectious agent i.e. the Epstein - Barr virus (EBV) is also implicated as a causative agent and the disease is said to be biologically and morphologically distinct from MALToma.[4,5] The association of EBV with gastric lymphoma is not constant and is also seen commonly with high-grade lesions such as diffuse large B-cell subtype.[5] Xu et al have reported that EBV was seen in cases that are negative for H. pylori.[6] There is no data from India as to the association of EBV with gastric lymphomas, their morphologic appearance and relationship to H. pylori infection. We undertook this study to explore this association.

MATERIAL AND METHODS

In this retrospective study, 16 histologically and/or immunophenotypically proven cases of primary Gastric NHL were studied. Cases that had adequate clinical details and retrievable slides and tissue blocks were selected. Those cases of known primary nodal lymphomas with gastric involvement were excluded form the study. The presence of H. pylori infection in the uninvolved tissue was looked for and confirmed by histochemical stain i.e. modified Giemsa. If present, they were expressed semi-quantitatively as occasional, few or many. The presence of EBV was looked for by performing immunohistochemistry (IHC) for the viral Latent Membrane Protein 1 (LMP-1) (Dako, M0897). This was done in a dilution of 1:50 on paraffin-embedded sections using heat-based antigen retrieval and conventional Avidin-Biotin method and developed with DAB. The staining was interpreted as positive, if a minimum of one neoplastic cell showed cytoplasmic/membranous staining. Histologic subtyping was done as per WHO classification. The results were tabulated.

RESULTS

The histologic features, results of EBV and H.pylori stain are summarized in Table 1. Of the 16 gastric lymphomas, 10 were low-grade MALT lymphomas and 6 were high-grade lymphomas.

The low-grade lymphomas (n=10) comprised of intermediate-sized lymphoid cells admixed with plasma cells and monocytoid cells in 4 cases. Scattered large, atypical cells were seen in 4 cases. Lymphoid follicles with germinal centres were seen in 3 cases, of which one showed colonization by neoplastic cells. Lymphoepithelial lesions, with destructive invasion of gastric glands were seen in 8/9 cases. (Fig 1) Mitotic rate was 1-2 per 10 high-power fields.

The high-grade lymphomas (n=6) showed a preponderance of diffuse sheets of large lymphoid cells with strikingly atypical nuclei, prominent nucleoli and many mitotic figures in every high-power field. Plasma cells were present. Lymphoepithelial lesions were seen in 5 cases. Lymphoid follicles were absent.

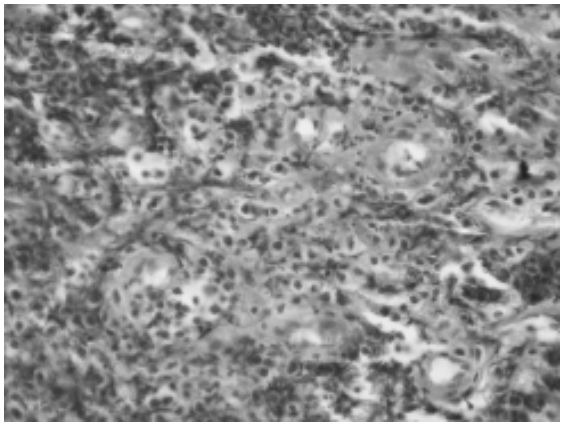

Fig 1. Destructive lymphoepithelial lesions in gastric MALT lymphoma (H&E x 400)

Results of immunophenotyping were available in 6 cases, all of which were B-cell phenotype. 2 were high-grade and 4 were low-grade NHL.

Immunostain for EBV was done in 11/16 cases. In 5 cases, there was no tumour tissue left in the block. 4/11 cases were positive, 3 of them being low-grade lymphomas. Scattered positivity was noted within the tumour cells. One of the EBV positive low-grade lymphomas also showed a few H. pylori. All the remaining cases were negative for H. pylori.

FOLLOW-UP:

Follow-up data is available for 8 cases. 4 patients expired within a month of diagnosis, three of them due to sepsis. Three of these were also seropositive for HIV and all of them were histologically high-grade lymphomas. The remaining patient succumbed to pulmonary thromboembolism. 3 other cases showed response to chemotherapy and were disease-free at the time of follow –up (Range, 1 to 4 years) . One case was referred to a cancer centre and lost to follow-up.

DISCUSSION

Primary gastric NHL, is the most common extranodal lymphoma, and is being encountered

Table 1. Distribution of histologic features, EBV and H. pylori in 16 primary gastric Non-Hodgkin's Lymphomas

S. No				Centro-cytes	Centro-blasts	Plasma cells	Monoeytoid cells	Large atypical	Folli-cles	Follicular coloni-sation	LELs	Diagnosis	EBV	H. Pytori
	Small	Inter-mediate	large											
1	0	+	0	0	+	+	+	+	+	0	0	low grade MAL Toma	-	ND
2	0	+	+	0	0	+	+	+	+	0	+	low grade MAL Toma	_	_
3	0	+	0	0	+	+	+	0	0	0	+	low grade MAL Toma	_	_
4	0	+	0	0	+	+	0	0	0	0	+	low grade MAL Toma	+	_
5	0	+	0	0	+	+	+	+	0	0	+	low grade MAL Toma	-	-
6	0	+	0	+	+	+	0	0	+	+	+	low grade MAL Toma	-	-
7	0	+	0	+	+	+	+	0	0	0	+	low grade MAL Toma	ND	ND
8	+	+	0	+	+	+	0	0	0	0	0	low grade MAL Toma	+	+
9	0	+	0	0	+	+	0	+	0	0	+	low grade MAL Toma	ND	
10	0	+	0	+	+	+	0	0	0	0	+	low grade MAL Toma	+	ND
11	0	0	+	+	+	0	0	+	0	0	+	high grade MAL Tom lymphoma	-	ND
12	0	+	+	0	+	+	0	+	0	0	+	high grade large cell lymphoma	ND	ND
13	0	0	+	+	+	+	+	+	0	0	+	high grade MALT lymphoma	ND	-
14	0	+	0	0	+	+	0	0	0	0	+	high grade MALT lymphoma	-	-
15	+	0	+	+	+	+	+	+	0	0	+	high grade MALT lymphoma	+	-
16	0	0	+	+	+	+	+	+	0	0	0	Large cell lymphoma	ND	-

(LEL = lymphoepithelial lesion, ND = not done)

increasingly in India in the recent years. This is probably related to the prevalence of H. pylori gastritis, which has been shown to have a causative association.[1] Most of the gastric lymphomas in the western population are of MALT type, and are known to regress after eradication of H. pylori.[1] The largest Indian study cites "poorly differentiated lymphocytic lymphoma" as the commonest, subtype which does not convey much about the histogenesis and does not employ the current WHO terminology.[2]

In addition to H. pylori, EBV has also been implicated as an aetiologic agent in the west and parts of Asia.[5] In a study of 79 cases, 15 were found to express EBV LMP-1 by IHC as well as in-situ hybridization, suggesting a greater role. However, in a study from Korea only 2 out of 33 gastric lymphomas had expression of EBV DNA, negating the likelihood of causative association.[7] These conflicting results and lack of Indian data justify the need for our study. EBV is associated with a host of other malignancies, prominently nasopharyngeal carcinoma, Burkitt's lymphoma and Hodgkin's lymphoma. In Hodgkin's lymphoma, it has emerged significant in some studies, with EBV associated tumours said to carry a better prognosis.[8,9] As EBV maintains a high replicating population of tumour cells, they are said to be more chemosensitive. The same mechanism possibly is at play in gastric lymphomas, too.

Most of the gastric lymphomas we encountered were of the MALT type. MALTomas are characterised by the presence of lymphoepithelial lesions (LELs), defined as clusters of a minimum of 3 neoplastic lymphocytes infiltrating and destroying epithelial cells, which show a dense pink cytoplasm.[6] The background is polymorphous, comprising of small lymphocytes, plasma cells, eosinophils and monocytoid cells. They may be

mistaken for a reactive infiltrate. While the low grade MALT lymphomas show these features consistently, the high-grade ones may not demonstrate LELs and may be difficult to differentiate from other high-grade lymphomas. Only the concomitant presence of a low-grade component can help classify a high-grade lymphoma as MALT type.[6] In our study, 5/6 high-grade cases showed LELs. This feature was highlighted by the PAS stain, which demonstrated the outlines of the glandular remnants amidst the high-grade component. We feel this stain can be employed in all biopsies with suspicious lymphoid infiltrates. The remaining case did not show LELs.

Lymphoid follicles with germinal centres were seen in 3/9 low-grade lymphomas. These are also seen in H.pylori-associated gastritis, and pose a diagnostic problem.[10] Wotherspoon et al have proposed a scoring system (scores 0-5) in this context, that is being used by many pathologists.[11] In addition, immunohistochemical detection of CD 20+, IgM+, IgD- cells beyond the confines of the follicle and "follicular colonization" by these marginal zone cells supports the diagnosis.[10] Follicular colonization refers to neoplastic lymphocytes invading the centre of a reactive follicle.

The role of EBV in primary gastric lymphoma is not well understood. There are conflicting results from various parts of the world.[5,6,7] The rates of EBV association range from 6-19% in Asians.[6,7] There is only one study from India which has documented the association of EBV with gastric carcinoma, citing a rate of 24%.[12] There is no record of its prevalence in gastric lymphoma. We found EBV LMP-1 in 4/11 cases (36%), 3 of which were low-grade lymphomas. This suggests a bigger role for EBV in the pathogenesis of gastric lymphomas in India and warrants studies on a larger sample size. The major limiting factor in our study was the availability of tissues. Since most of the samples were endoscopic biopsies and multiple serial sections were taken to establish the diagnosis and performing CD20 immunostain, there was not enough tumour tissue left to perform immunohistochemistry for EBV.

Only one case showed H. pylori in addition to EBV, which is in concordance with reports citing that though the organisms are implicated in the pathogenesis, they do not persist in tumour tissues.[6] It is also food for thought, whether these two proposed aetiologic agents are mutually exclusive or linked to each other.

Looking at the follow-up, high-grade gastric lymphomas carry a worse prognosis. Two of these were EBV positive, and three were associated with HIV, which is a risk factor for EBV and contributed to the rapid deterioration.

The use of more sensitive techniques such as EBER in-situ hybridisation might yield a higher rate of EBV positivity.[4,5,6] Whether this is a true association of gastric lymphoma with EBV which, in addition, translates into prognostic significance is an important avenue to be explored in a larger series.

CONCLUSION

In this study of primary gastric lymphomas, we found a predominance of low-grade MALT lymphomas, characterised by a polymorphous cellular infiltrate and lymphoepithelial lesions. H. pylori was found in only one case. 36% of lymphomas were EBV positive, suggesting a possible role for viral oncogenesis. This assumes importance in the era of targeted therapy, urging the need for a larger study.

Acknowledgement: This study was supported by a grant from the Rajiv Gandhi University of Health Sciences, Karnataka.

REFERENCES:

1. *Bayerdorffer E, Neubauer A, Rudolph B et al. Regression of primary gastric lymphoma of mucosa-associated lymphoid tissue type after cure of Helicobacter pylori infection. Lancet 1995;345:1591-1594.*

2. *Singh DP, Sharma SC, Sandhu AP et al. Primary gastrointestinal lymphoma-disease spectrum and management: a 15-year review from North India. Indian J Gastroenterol 1997;16(3):88-90.*

3. *Isaacson PG. Recent Developments in Our Understanding of Gastric Lymphomas. Am J Surg Pathol 1996;20Suppl 1: 1-7.*

4. *Chan WY, Chan EK, Chow JH. Epstein-Barr virus-associated gastric lymphomas are distinct from mucosa-associated lymphoid tissue-type lymphomas:*

genetic abnormalities of p53 gene. Diagn Mol Pathol 2001;10(3):153-160.

5. *Liu q, Ohshima K, Masuda Y, Kikuchi M. Detection of the Epstein-Barr virus in primary gastric lymphoma by in-situ hybridization. Pathol Int 1995;45(2):131-136.*

6. *Xu WS, Ho FC, Ho J, Chan AC, Srivastava G. Pathogenesis of gastric lymphoma: the enigma in Hong Kong. Ann Oncol 1997;8Suppl 2: 41-44.*

7. *Yang WI, Cho MS, Tomita Y, Ohsawa M, Aozasa K. Epstein-Barr virus and gastrointestinal lymphomas in Korea. Yonsei Med J. 1998;39(3):268-76.*

8. *Rajalakshmi T, Payal K, Makhija P, Karuna V. Epstein-Barr Virus in Hodgkin Lymphoma – Incidence and prognostic implications. Ind. J. Med and Paed Oncol 2006;27(1):23-26.*

9. *Naresh KN, Johnson J, Srinivas V et al: Epstein-Barr virus provides survival advantage to Reed-Sternberg cells in classical Hodgkin's disease and survival advantage to the patient. Ann Oncol 1999;10:2.*

10. *Jaffe ES, Harris NL, Stein H, Vardiman JW (Eds) WHO Classification of tumours of haematopoietic and lymphoid tissues. MALT Lymphoma. IARC Press: Lyon 2001;157-160.*

11. *Wotherspoon AC, Doglioni C, Diss TC et al. Regression of primary low-grade B-cell gastric lymphoma of mucosa-associated lymphoid tissue type after eradication of Helicobacter pylori. Lancet 1993;342:575-77.*

12. *Andal N, Shanthi P, Krishnan KB, Taralaxmi V. The Epstein Barr virus and gastric carcinoma. Indian J Pathol Microbiol 2003;46(1):34-6.*

CLINICAL RESEARCH WORKSHOP

A workshop on Clinical Research Methodology is being organized in Lucknow on 10-12 December, 2008, under the aegis of the U.S. National Institutes of Health and the Sanjay Gandhi Postgraduate Institute of Medical Sciences (SGPGI).

The workshop will focus on methodology to design and conduct observational studies (e.g. prospective cohort, case-control and cross-sectional studies), the most common clinical research studies reported in the literature. The workshop is targeted at early and mid-career medical faculty members/ researchers, as well as postgraduate students with interest in clinical research.

Applicants should email a short (**strictly in one page**) summary of their experience, expertise and current activities in clinical research by October 31, 2008 to Paolo Miotti, U.S. Embassy, New Delhi (pm122m@nih.gov). A selection committee will notify the successful applicants of their acceptance. Participants' travel and hotel expenses will be covered by the workshop organizers.