

## Letter to the Editor-1

### Cisplatin Induced Acute Cerebral Infarct

Sir,

Cisplatin is a commonly used cytotoxic drug for various types of solid tumours. Its toxicities include emesis, nephrotoxicity, peripheral neuropathy and ototoxicities. Stroke as a vascular toxicity associated with cisplatin is very rare. We report one such case in a woman treated for primary extra ovarian peritoneal carcinoma.

**Case:** A 72-year-old female, presented with progressive distension of abdomen of 2 months duration. Clinically, she had tense ascites, which was hemorrhagic and ascitic fluid cytology revealed adenocarcinoma. Ultrasound of the abdomen and pelvis showed large ascites. Liver was normal. There was no adnexal mass or retro peritoneal lymphadenopathy. She had undergone abdominal hysterectomy for dysmenorrhoea 20 years back. She was on regular treatment for type II diabetes and hypertension for the last 3 years and both conditions were well controlled.

Serum CA 125-458 i.u /ml and serum CEA 4.8 ng/ml. Gastroscopy and colonoscopy were normal. Hence the diagnosis of primary extra ovarian peritoneal carcinomatosis was made. She had performance status 2. She was started on chemotherapy with cisplatin and cyclophosphamide. Patient was hydrated with 1 litre of normal saline prior to and after the cisplatin infusion and took adequate oral fluids. Granisetron and dexamethasone were used for emesis control. She tolerated chemotherapy well. 36 hours after chemotherapy, she developed mild confusion and incoherent speech. Neurological status was assessed clinically. She was a right-handed individual and literate. She was conscious and had normal attention. Her language fluency was reduced, with occasional phonemic paraphasias. Her naming ability was intact for objects and body parts. But it was impaired for colours and parts of objects. She could comprehend three stage commands. She had normal repetition. Her reading and writing ability was normal. She did not have any facial palsy. She had normal power in all 4 limbs. There was right upper limb

pronator drift with asterixis of right hand. Sensory examination, coordination, stretch reflexes were normal. She did not have extensor plantar response. Her stance and gait were normal.

CT scan brain (Figure: 1) showed acute infarct in left capsulo ganglionic region. Carotid Doppler showed calcified plaques in both carotid bulbs without significant haemodynamic changes. Echocardiogram was normal. Serum electrolyte Na 135 meq/l, K 5.4 meq/l and magnesium (2.2 meq/l).

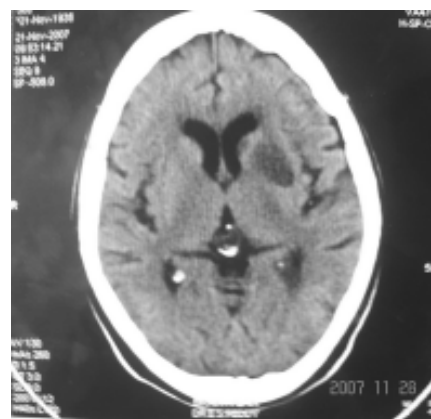


Fig 1: CT scan brain showing acute infarct in left capsulo ganglionic region.

She was managed conservatively, with anti platelet agent, clopidogrel. Cisplatin was excluded from further chemotherapy and paclitaxel was used instead. Patient achieved complete response after 4 cycles of paclitaxel and cyclophosphamide and completed additional two cycles of same chemotherapy. She tolerated this chemotherapy well. Neurological status remained status quo.

#### COMMENTS:

Here we describe a case of acute cerebrovascular ischaemic stroke following combination chemotherapy with cisplatin and cyclophosphamide for primary extra ovarian peritoneal carcinomatosis. Previously, a retrospective study studying stroke incidence in

patients on chemotherapy, has reported an incidence of 0.137%.<sup>1</sup> Middle cerebral arterial stroke was the most common type. Platinum compound, especially cisplatin, was the most commonly used drug in patients who had developed stroke. Nearly, 75% of strokes occurred within 10 days after chemotherapy. Sixty percent of strokes occurred following the first cycle. The median survival in this cohort was 4 weeks. In the clinical spectrum of cisplatin associated vascular toxicities, one case of myocardial infarction has also been reported<sup>2</sup>; Raynaud's phenomenon has also been reported in patients receiving BEP chemotherapy for germ cell tumours.<sup>3</sup>

Several molecular mechanisms have been implicated for cisplatin associated vascular toxicity. These include reduced activity of protein C<sup>4</sup> and increased levels of von Willibrand factor<sup>5</sup>, which have been known to increase the hypercoagulability state. Additionally, cisplatin infusion releases free radicals, which cause direct vascular endothelial injury, leading to the release of endothelial and platelet derived micro particles, initiating a cascade of platelet aggregation and vasoconstriction resulting in thrombosis. Another study showed initial reduction, later followed by increase in the endothelial and platelet micro particles at the second and third infusion of cisplatin.<sup>6</sup> Cisplatin is also known to produce hypomagnesemia, which increases the vascular smooth muscle contraction contributing to vascular toxicity.<sup>2</sup> However, in our case the magnesium levels were normal.

Chemotherapy induced tumour cell lysis has been speculated to increase the mucin influx in to the blood leading to a hypercoagulable state.<sup>7</sup> Further, Mucin-producing signet ring cell adenocarcinomas are known to secrete abnormally glycosylated mucins and mucin fragments into the blood stream, which are associated with coagulopathies.<sup>7</sup> It is also possible that in some cases both the tumour (mucin secreting) and the drug (Cisplatin) might work in synergism to produce vascular toxicity.

The fact that patient could tolerate paclitaxel and cyclophosphamide well and neurological condition did not get worse, suggest that Cisplatin was the most probable aetiological factor for stroke in this patient.

There are no known risk factors to identify the vulnerable patients for cerebrovascular toxicity of cisplatin and therefore no proven methods of prevention of such a serious complication associated with morbidity and mortality. Maintenance of good hydration is known to prevent hypercoagulability and thrombotic complications.

Further more, it is not clear, if other platinum compounds are safe in patients known to have had cisplatin associated vascular toxicity.

#### REFERENCE:

- 1) Li SH, Chen WH, Tang Y, et al. Incidence of ischemic stroke post-chemotherapy: a retrospective review of 10,963 patients. *Clin Neurol Neurosurg.* 2006;108(2):150-6.
- 2) Brouha ME, Bloemendal HJ, Kappelle LJ, Winter JB. Cerebral infarction and myocardial infarction due to cisplatin-containing chemotherapy. *Ned Tijdschr Geneeskd.* 2003;147(10):457-60.
- 3) Vogelzang NJ, Torkelson JL, Kennedy BJ. Hypomagnesemia, renal dysfunction, and Raynaud's phenomenon in patients treated with cisplatin, vinblastine, and bleomycin. *Cancer.* 1985;56(12):2765-70.
- 4) Taher A, Shamseddine A, Saghir N, et al. Acquired protein C deficiency following cisplatin-avelbine administration for locally advanced breast cancer. Case report. *Eur J Gynaecol Oncol.* 1999;20(4):323-4.
- 5) Licciardello JT, Moake JL, Rudy CK, Karp DD, Hong WK. Elevated plasma von Willebrand factor levels and arterial occlusive complications associated with cisplatin-based chemotherapy. *Oncology.* 1985;42(5):296-300.
- 6) Periard D, Boulanger CM, Eyer S, Amabile N, Pugin P, Gerschheimer C, Hayoz D. Are circulating endothelial-derived and platelet-derived microparticles a pathogenic factor in the cisplatin-induced stroke? *Stroke.* 2007;38(5):1636-8.
- 7) Wahrenbrock M, Borsig L, Le D, Varki N, Varki A. Selectin-mucin interactions as a probable molecular explanation for the association of Trousseau syndrome with mucinous adenocarcinomas. *J Clin Invest.* 2003;112(6):853-62.

**Sambasivaiah K, Srikanth Reddy,  
Praveen Kumar B.S and Suneetha P**  
Departments of Medical Oncology,  
Neurology, and Radiology  
Narayana Medical College Hospital,  
Nellore, Andhra Pradesh.  
Email: sambasvims@yahoo.co.in

