

# Embryonal rhabdomyosarcoma of the broad ligament

Mihir N. Chandarana,

Shankar Raghu,

Monica Bhagat, Sajid Qureshi

Department of Surgical Oncology,  
Division of Pediatric Surgery,  
Tata Memorial Centre, Mumbai,  
Maharashtra, India

## Address for correspondence:

Dr. Sajid Qureshi,  
Room No. 14, Main Building, Tata  
Memorial Centre, Dr. E. Borges  
Road, Mumbai - 400 012,  
Maharashtra, India.  
E-mail: sajidshafique@rediffmail.com

## ABSTRACT

Broad ligament tumors are uncommon. Sarcomas rarely arise from the broad ligament, leiomyosarcomas being the most common. Rhabdomyosarcomas of the broad ligament are very rare. To the best of our knowledge, no case of an embryonal rhabdomyosarcoma of the broad ligament has been reported in literature.

**Key words:** Broad ligament, embryonal rhabdomyosarcoma, sarcoma

## INTRODUCTION

A study by Gardner *et al.* first described broad ligament tumors in 1957.<sup>[1]</sup> Leiomyosarcomas are the most common malignant broad ligament tumors.<sup>[2]</sup> Rhabdomyosarcomas arising from the broad ligament are very rare. We came across 3 cases of sarcomas, other than leiomyosarcomas, reported to arise from the broad ligament.<sup>[3-5]</sup> To the best of our knowledge, no case of an embryonal rhabdomyosarcoma (ERMS) of the broad ligament has been reported in literature. We report about a 9-month-old female child with an ERMS of the broad ligament.

## CASE REPORT

The case we present here is a 9-month-old female child, presented to us with the complaints of straining at micturition and defecation since the age of 5 months. The patient was diagnosed with benign partial epilepsy of infancy and was under treatment for the same. No other comorbidities were present. On examination, the patient had multiple Café au lait spots over her body (more than 5 in number). However, there were no other features

to suggest neurofibromatosis, like, family history, Lisch nodules, axillary or inguinal freckling and osseous lesions. Abdominal examination revealed an abdominopelvic mass, in the midline, extending superiorly to just above the umbilicus. The mass was firm to hard in consistency and mobile. The mass was also felt on per-rectal examination. A contrast enhanced computed tomography (CECT) scan of the abdomen and pelvis confirmed the clinical findings of an abdominopelvic mass of about 9.8 cm × 6 cm × 5 cm extending from the level of acetabulum in the pelvis, to the level of L3 vertebra [Figure 1]. The mass was isodense to hypodense on a plain scan with heterogenous enhancement on post-contrast scan. The urinary bladder was pushed to the right side due to mass effect but planes were maintained. There was mild left-sided hydronephrosis with the distal left ureter not visualized. The uterus and adnexa were not visualized separately. A percutaneous biopsy done from the mass revealed ERMS. The metastatic work-up, including a bone scan, CECT thorax and bone marrow examination, was normal.

The patient received neoadjuvant chemotherapy (NACT), as per intergroup rhabdomyosarcoma study group (IRS) IV protocol (vincristine, actinomycin and cyclophosphamide). The post NACT CECT scan showed a stable disease. An exploratory laparotomy performed revealed a lobulated mass of 10 cm × 5 cm × 5 cm [Figure 1]. The mass had a pedicle and was seen to be arising from the left broad ligament. The uterus and adnexa were separate from the mass, pushed to the right side. The mass was densely adhered to the urinary bladder but could be separated

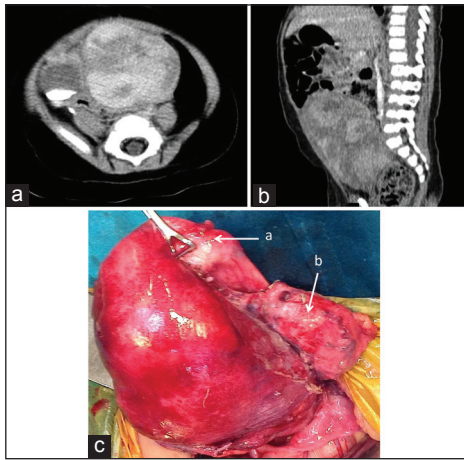
## Access this article online

### Quick Response Code:



Website:  
www.ijmpo.org

DOI:  
10.4103/0971-5851.133734



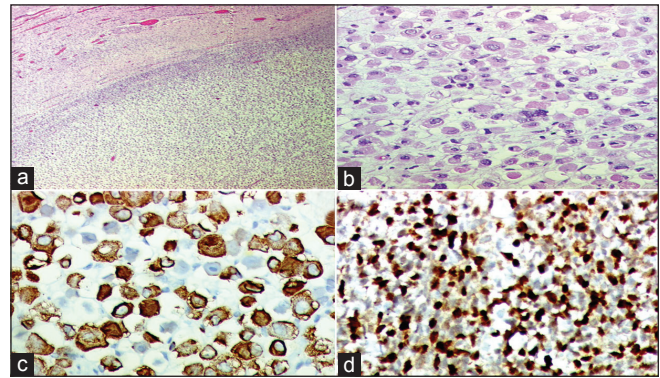
**Figure 1:** Contrast enhanced computed tomography scan showing the heterogeneously enhancing mass arising from pelvis, with contrast in urinary bladder (a and b). Intra-operatively (c), the mass seen arising from the broad ligament, the uterus (a) and urinary bladder (b) separated

by dissection. The ureters on both sides were separate from the mass. The mass was excised in-toto preserving the uterus and the adnexae. The post-operative course of the patient was uneventful. The final histopathology revealed an ERMS with cut margin negative for tumor. The Immunohistochemistry studies were positive for desmin and myosin [Figure 2]. As per the TNM and IRS staging, our patient was staged as Stage I, Group III, with embryonal histology and thus classified as low risk subgroup.<sup>[6]</sup> The patient was treated with adjuvant chemotherapy as per IRS IV protocol.

## DISCUSSION

Rhabdomyosarcoma is the most common soft-tissue sarcoma of children accounting for 3-4% of all the childhood cancers.<sup>[7]</sup> Pathologically, rhabdomyosarcoma is classified into three subtypes: Embryonal, alveolar and pleomorphic. ERMS forms 60% of the cases and is seen in younger patients. Sites commonly affected are head and neck and genitourinary systems. Rhabdomyosarcoma is known to be associated with Café au lait spots and neurofibromatosis type-I. Our patient though had Café au lait spots, did not have other features suggestive of neurofibromatosis.

On reviewing the literature on broad ligament sarcomas (excluding leiomyosarcomas), we came across only 3 such cases. Copeland *et al.* in their study have reported the first of those in 1985 in their series of eight patients of female genital tract sarcomas.<sup>[3]</sup> The patient was 16 years of age with an alveolar rhabdomyosarcoma of the broad ligament. The second case was a 55-year-old female diagnosed and treated for an undifferentiated pleomorphic sarcoma



**Figure 2:** Histology showing rhabdomyosarcomatous elements (a and b). Immunohistochemistry positive for desmin (c) and myosin (d)

of the broad ligament reported by Bouraoui *et al.*<sup>[4]</sup> The third patient, reported by Diaz-Murillo *et al.* was a 27-year female with an undifferentiated round cell sarcoma of the broad ligament.<sup>[5]</sup> Our patient is a 9-month-old child with an ERMS of the broad ligament. All the three previously reported patients received multimodality treatment. The first two patients developed recurrence and did not survive beyond 1-year of diagnosis. The patient reported by Diaz-Murillo was followed-up for 12 years without any recurrence. Our patient is still receiving her adjuvant chemotherapy.

The treatment of rhabdomyosarcoma requires a multimodality approach. The treatment is decided after a tissue diagnosis and metastatic work-up of the patient. Our patient after appropriate investigations was diagnosed as a non-metastatic pelvic ERMS. On the basis of CECT scan findings of an abutting urinary bladder and non-visualization of the left ureter, it was decided to start NACT (IRS IV protocol)<sup>[8]</sup> and reassess for the response. On repeating a CECT scan after NACT, it was a stable disease; hence, it was decided to go ahead with surgery for appropriate local control of the tumor. A gross total excision of the tumor could be achieved. Adjuvant radiation therapy was considered in view of the mass adherent to the urinary bladder, but withheld considering the age and low risk group of the patient. Adjuvant chemotherapy was given.

## CONCLUSION

Broad ligament rhabdomyosarcomas are an extremely rare entity. To the best of our knowledge, this is the first case of an ERMS arising from the broad ligament in an infant.

## REFERENCES

- Gardner GH, Greene RR, Peckham B. Tumors of the broad ligament. *Am J Obstet Gynecol* 1957;73:536-54.

2. Chmaj-Wierzchowska K, Buks J, Wierzchowski M, Szymanowski K, Opala T. Leiomyoma cellulare in the broad ligament of the uterus — Case report and review of literature. *Ginekol Pol* 2012;83:301-4.
3. Copeland LJ, Sneige N, Stringer CA, Gershenson DM, Saul PB, Kavanagh JJ. Alveolar rhabdomyosarcoma of the female genitalia. *Cancer* 1985;56:849-55.
4. Bouraoui S, Mlika M, Blel A, Kamoun H, Mzabi-Regaya S. Undifferentiated pleomorphic sarcoma of the broad ligament. *Pathologica* 2008;100:478-81.
5. Diaz-Murillo R, Iglesias-Sanchez C, Zapardiel I. Undifferentiated round cell sarcoma of the broad ligament. *Ecancermedalscience* 2013;7:303.
6. Malempati S, Hawkins DS. Rhabdomyosarcoma: Review of the children's oncology group (COG) soft-tissue sarcoma committee experience and rationale for current COG studies. *Pediatr Blood Cancer* 2012;59:5-10.
7. Wang LL, Yustein J, Louis T, Russell HV, Pappo AS, Paulino A *et al.* Solid tumors of childhood. In: Pine JW, editor. *Hellman and Rosenberg's Cancer Principles and Practice of Oncology*. 9<sup>th</sup> ed. Philadelphia: Lippincott Williams and Wilkins; 2011. p. 1760-92.
8. Wu HY, Snyder HM 3<sup>rd</sup>, Womer RB. Genitourinary rhabdomyosarcoma: Which treatment, how much, and when? *J Pediatr Urol* 2009;5:501-6.

**How to cite this article:** Chandarana MN, Raghu S, Bhagat M, Qureshi S. Embryonal rhabdomyosarcoma of the broad ligament. *Indian J Med Paediatr Oncol* 2014;35:103-5.  
**Source of Support:** Nil, **Conflict of Interest:** None declared.

### Author Help: Reference checking facility

The manuscript system ([www.journalonweb.com](http://www.journalonweb.com)) allows the authors to check and verify the accuracy and style of references. The tool checks the references with PubMed as per a predefined style. Authors are encouraged to use this facility, before submitting articles to the journal.

- The style as well as bibliographic elements should be 100% accurate, to help get the references verified from the system. Even a single spelling error or addition of issue number/month of publication will lead to an error when verifying the reference.
- Example of a correct style  
Sheahan P, O'leary G, Lee G, Fitzgibbon J. Cystic cervical metastases: Incidence and diagnosis using fine needle aspiration biopsy. *Otolaryngol Head Neck Surg* 2002;127:294-8.
- Only the references from journals indexed in PubMed will be checked.
- Enter each reference in new line, without a serial number.
- Add up to a maximum of 15 references at a time.
- If the reference is correct for its bibliographic elements and punctuations, it will be shown as CORRECT and a link to the correct article in PubMed will be given.
- If any of the bibliographic elements are missing, incorrect or extra (such as issue number), it will be shown as INCORRECT and link to possible articles in PubMed will be given.