

Fatal hematogenous relapse of mucinous borderline ovarian tumor of intestinal type

A. Robert Louis,
Sunil Kumar Gupta,
Chandra Gouda,
Gurudutt Gupta¹

Departments of Medical Oncology
and ¹Pathology, Rajiv Gandhi
Cancer Institute and Research
Center, Sector 5 Rohini, New Delhi,
India

Address for correspondence:

Dr. A. Robert Louis,
Department of Medical
Oncology, Unit II, Rajiv Gandhi
Cancer Institute and Research
Center, Sector 5 Rohini,
New Delhi - 110 085, India.
E-mail: drrobertlouis@gmail.com

ABSTRACT

We describe an unusual case of fatal hematogenous relapse of borderline mucinous ovarian tumour of intestinal type after three years of primary optimal cytoreduction with dissemination to liver, bones and lymphangitic pattern of spread in lungs with resistance to standard chemotherapy.

Key words: *Chemoresistant, hematogenous relapse, mucinous borderline ovarian tumor*

A 61-year-old lady who has been diagnosed as pathological stage IA (limited to one ovary with no capsule breach) borderline ovarian tumor of intestinal type [Figure 1]

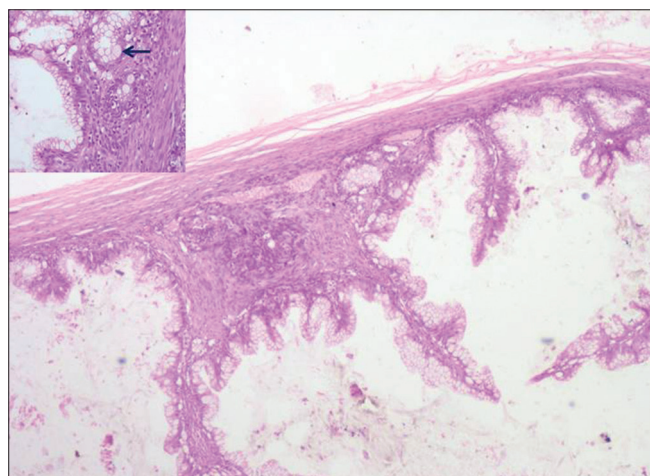


Figure 1: Section showing borderline mucinous tumor-intestinal type with goblet cells (black arrow) of ovary (H and E, x40) and inset (H and E, x200)

in 2008 has come to us three years later with abdominal pain, backpain and exertional breathlessness. Computed tomography evaluation showed liver lesion, extensive lymphangitic pulmonary lesion and scattered vertebral lesion but no peritoneal disease [Figure 2]. Bonescan showed multiple uptakes in axial and appendicular skeleton. Biopsy from liver lesion showed mucin positive adenocarcinoma consistent with ovarian origin positive for cytokeratin 7, cytokeratin 20 CK7, CK20) and cancer antigen 125 (CA 125) and negative for caudal type

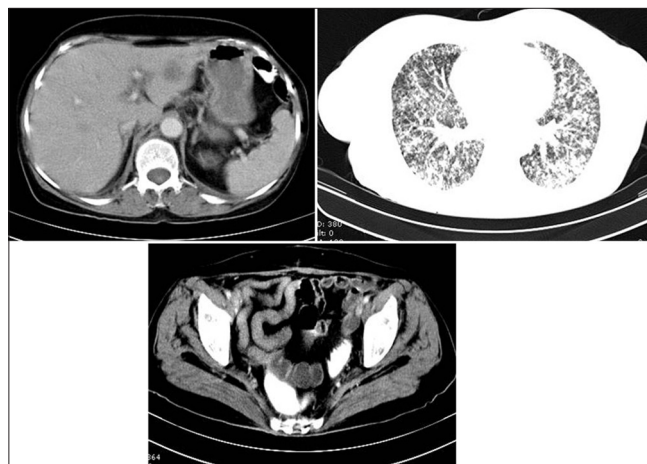


Figure 2: Computed tomography evaluation showed liver lesion and extensive lymphangitic pulmonary lesion and scattered vertebral lesion but no peritoneal disease

Access this article online

Quick Response Code:



Website:
www.ijmpo.org

DOI:
10.4103/0971-5851.116222

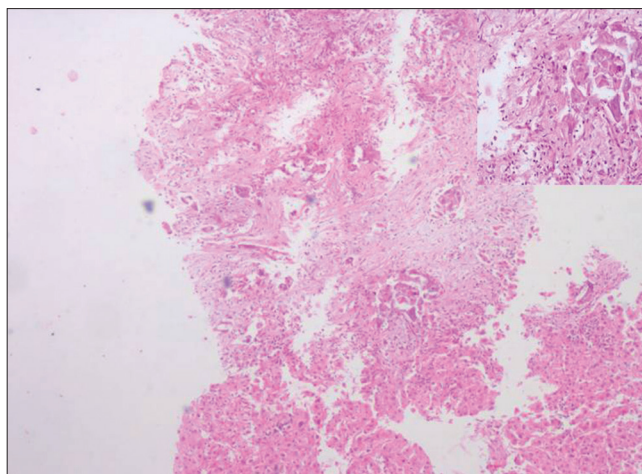


Figure 3: Section showing metastatic deposits of mucinous adenocarcinoma (H and E, x40) and inset (H and E, x200)

homeobox 2 (CDX2) [Figures 3 and 4]. Her upper and lower Gastrointestinal endoscopies were normal. She had progressive disease despite paclitaxel and carboplatin based therapy and failed subsequent secondline therapy before she eventually died of disease related respiratory failure.

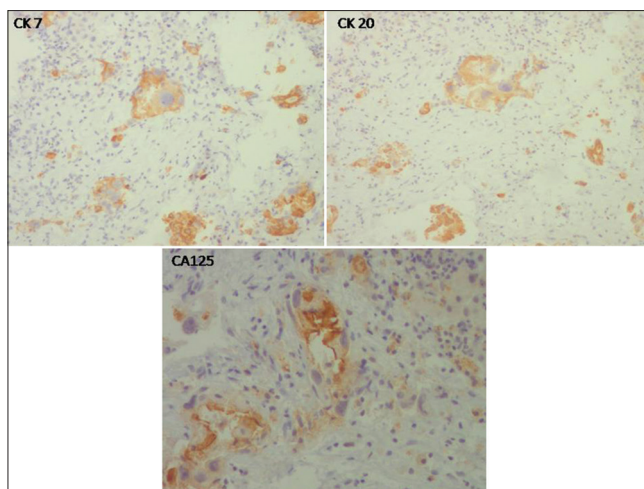


Figure 4: Special immunostains highlight immunopositivity for Ck 7, Ck 20 and Ca125. (Dab, x200)

How to cite this article: Louis AR, Gupta SK, Gouda C, Gupta G. Fatal hematogenous relapse of mucinous borderline ovarian tumor of intestinal type. *Indian J Med Paediatr Oncol* 2013;34: 134-5.

Source of Support: Nil, **Conflict of Interest:** None declared.

"Quick Response Code" link for full text articles

The journal issue has a unique new feature for reaching to the journal's website without typing a single letter. Each article on its first page has a "Quick Response Code". Using any mobile or other hand-held device with camera and GPRS/other internet source, one can reach to the full text of that particular article on the journal's website. Start a QR-code reading software (see list of free applications from <http://tinyurl.com/yylh2tc>) and point the camera to the QR-code printed in the journal. It will automatically take you to the HTML full text of that article. One can also use a desktop or laptop with web camera for similar functionality. See <http://tinyurl.com/2bw7fn3> or <http://tinyurl.com/3ysr3me> for the free applications.