Article published online: 2021-07-30

In the workup of patients with obscure gastrointestinal bleed, does 64-slice MDCT have a role?

Chinmay Kulkarni, Srikanth Moorthy, Sreekumar KP, Rajeshkannan R, Nazar PK, Sandya CJ, Sivasubramanian S, Ramchandran PV

Department of Radiology, Amrita Institute of Medical Sciences and Research Center, Elamakkara, Cochin, Kerala, India

Correspondence: Dr. Chinmay Kulkarni, Department of Radiology, Amrita Institute of Medical Sciences and Research Center, Amrita Lane, Elamakkara P.O., Kochi, Kerala, India. E-mail: chidoc@rediffmail.com

Abstract

Purpose: The purpose was to prospectively determine the sensitivity of 64-slice MDCT in detecting and diagnosing the cause of obscure gastrointestinal bleed (OGIB). **Materials and Methods:** Our study included 50 patients (male 30, female 20) in the age range of 3–82 years (average age: 58.52 years) who were referred to our radiology department as part of their workup for clinically evident gastrointestinal (GI) bleed or as part of workup for anemia (with and without positive fecal occult blood test). All patients underwent conventional upper endoscopy and colonoscopy before undergoing CT scan. Following a noncontrast scan, all patients underwent triple-phase contrast CT scan using a 64-slice CT scan system. The diagnostic performance of 64-slice MDCT was compared to the results of capsule endoscopy, 99m-technetium-labeled red blood cell scintigraphy (99mTc-RBC scintigraphy), digital subtraction angiography, and surgery whenever available. **Results:** CT scan showed positive findings in 32 of 50 patients. The sensitivity, specificity, positive predictive value, and negative predictive values of MDCT for detection of bleed were 72.2%, 42.8%, 81.2%, and 44.4%, respectively. Capsule endoscopy was done in 15 patients and was positive in 10 patients; it had a sensitivity of 71.4%. Eleven patients had undergone 99mTc-RBC scintigraphy prior to CT scan, and the result was positive in seven patients (sensitivity 70%). Digital subtraction angiography was performed in only eight patients and among them all except one patient showed findings consistent with the lesions detected on MDCT. **Conclusion:** MDCT is a sensitive and noninvasive tool that allows rapid detection and localization of OGIB. It can be used as the first-line investigation in patients with negative endoscopy and colonoscopy studies. MDCT and capsule endoscopy have complementary roles in the evaluation of OGIB.

Key words: Arteriography digital subtraction; capsule endoscopy; diagnosis; gastrointestinal hemorrhage; spiral cone-beam computed tomography

Introduction

Acute gastrointestinal (GI) bleed is a common cause of recurrent hospitalization and mortality. In most patients, bleeding is detected initially through upper GI endoscopy and colonoscopy. However, in 5% of patients the cause cannot be identified by routine endoscopic examinations.[1] Obscure gastrointestinal bleed (OGIB) is defined as recurrent acute or chronic bleeding for which no source has been identified by routine endoscopic studies (i.e., upper GI endoscopy and colonoscopy).[2] OGIB has been classified into two types: obscure overt bleed and obscure occult bleed. Obscure overt bleeding is defined as clinically evident bleeding that persists or reoccurs after negative endoscopic examinations.[2] Obscure occult bleeding is defined as persistently positive fecal occult blood test with or without iron deficiency and without frank blood loss recognizable to the patient or physician.[2] Because of the multiplicity of lesions that can cause GI bleed, the length of the GI tract, and the intermittent nature of bleeding, the workup of these patients is extensive and often repetitive. In patients with

Access this article online	
Quick Response Code:	Website: www.ijri.org
	DOI: 10.4103/0971-3026.95404

negative routine endoscopic studies, the common location of the GI bleed is the small bowel. The published algorithm for the diagnostic workup of OGIB recommends endoscopic studies as the first-line investigation, to be followed by capsule endoscopy (CE), double-balloon enteroscopy, and conventional angiography if there are no findings on endoscopic studies [Figure 1].[3] CT scan does not play a role in this suggested workup.

Advances in multidetector computed tomography (MDCT) have greatly expanded the diagnostic role of MDCT for various GI diseases. We conducted this study to determine the utility of MDCT for detecting and diagnosing the cause of OGIB.

Purpose

This prospective study aimed to determine the sensitivity of 64-slice MDCT for detecting and diagnosing the cause of OGIB.

Materials and Methods

The ethics committee of our institute approved this prospective study. Informed consent was taken from all patients undergoing the study. We prospectively studied 50 consecutive patients (male 30; female 20) in the age range of 3–82 years (average age 58.52 years) from July 2007 to October 2009. The study population consisted of patients who were referred for MDCT as a part of the workup for clinically evident active GI bleeding or as a part of the workup for anemia (with or without positive fecal occult blood test). Patients with positive findings on upper endoscopy or colonoscopy were excluded from the study. All patients underwent technically successful triple-phase CT scan. CT scan was performed using a protocol approved by the institutional review board and the radiation safety committee.

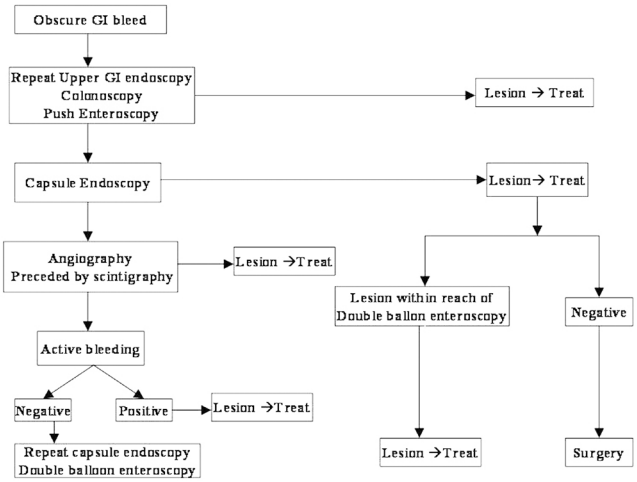

Figure 1: Protocol for evaluation of OGIB (modified from Clinical Journal of Gastroenterology, 2007;41(3):242-51

CT scan technique

The scanning was performed with a 64-slice CT system (Sensation® 64; Siemens Medical Solutions, Erlangen, Germany). All patients were scanned according to a standard protocol [Table 1].

An unenhanced CT scan was obtained before contrast-enhanced CT scan to identify any preexisting hyperattenuating areas within the bowel lumen that could be confused with hemorrhage. Contrast-enhanced images were obtained in bolus-triggered arterial phase, enteric phase, and venous phase. Bolus triggering was automatic software based (CARE bolus; Siemens Medical Solutions). A region of interest was placed over the descending thoracic aorta, 2 cm proximal to the diaphragm, and the scanning was initiated 6 seconds after the threshold of 150 HU was reached. Patients were scanned at 120 kVp and an effective milliampere-second (mAs) of 225. The average dose for each patient was 26.8 mSv in adults. In one child, 3 years old, the scan was done using a pediatric protocol that delivers an effective mA of 20 and a radiation dose of 1.6 mSv. The images were interpreted primarily using contiguous 1.5 mm axial unenhanced CT scan and contrast CT scan images on a picture archiving and communication system (PACS) workstation. The images were interpreted by gastrointestinal radiologists who have also practiced gastrointestinal intervention for the past 10 years. First the unenhanced CT scan data were evaluated to differentiate artifacts from bleed and then the contrast-enhanced CT scan data were evaluated. The bleeding site and mesenteric vessels were evaluated using a workstation with real-time maximum intensity projection (MIP), multiplanar reformation (MPR), and volume rendered technique (VRT) images.

Table 1: Multidetector computed tomography protocol used for scanning patients

Parameter	Comment
Area scanned	Domes of diaphragm to ischial tuberosity
Scan direction	Craniocaudal
Peak voltage (kV)	120 kV
Effective (mAs)	225 effective mAs
Rotation time (s)	0.33 s
Detector collimation	0.6 mm
Slice thickness	0.6 mm
Feed/Rotation (mm)	32 × 0.6 mm (19.2 mm)
Kernel	B30f medium smooth
Increment	0.6 mm × 0.3 mm
Oral contrast	Water 3 cups while waiting and 1 cup right before the scan; (i.e., 1800 cc total, after 4 hours of fasting)
Intravenous contrast	Omnipaque® 350
Volume (ml)	1.5 ml/kg
Rate (ml/s)	4–5 ml/s
Scan delay (s)	Arterial–bolus tracking Enteric: at 25 seconds Venous: 70–75 seconds
3D Technique	MPR, VRT, and MIP

Findings were correlated with the results of digital subtraction angiography (DSA), CE, 99m-technetium-labeled red blood cell (99mTc-RBC scintigraphy), and surgical findings whenever the data were available.

The criterion to diagnose active bleeding was contrast material extravasation, with a focal area of high attenuation within the bowel lumen (mean attenuation >90 HU).[4,5] Angiodysplasia was diagnosed in the presence of ectatic dilated vessels within the bowel wall and early filling veins [Figure 2]. Other findings such as vascular aneurysm/pseudoaneurysm [Figure 3], extravasation of contrast [Figure 4], graft-enteric fistula [Figure 5], gastrointestinal stromal tumor [Figure 6], polyps [Figure 7], abnormal enhancement [Figure 2], thickening of the bowel wall [Figure 2], and diverticula were regarded as positive CT scan findings. The final diagnosis was considered achieved when the findings were unequivocal on CT scan or when equivocal findings on CT scan were confirmed by another modality or by surgical/histopathological findings. The observations were recorded and analyzed using SPSS® 11.0 for Windows® and the sensitivity, specificity, positive predictive value, and negative predictive value of MDCT, CE, and 99mTc-RBC scintigraphy were calculated and analyzed.

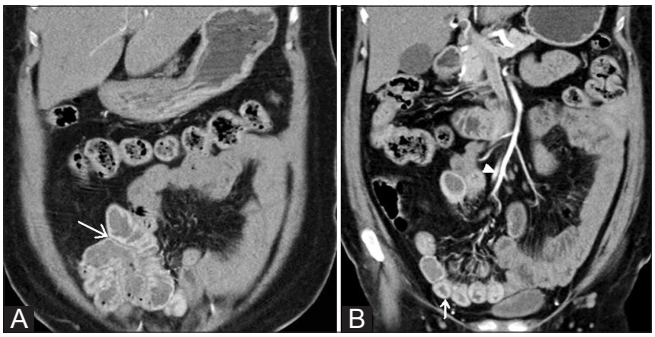

Figure 2 (A, B): A 51-year-old female presented with melena. Coronal CT scans (A, B) show nodular enhancement of the wall in the distal ileum (arrow) and an early draining vein (arrowhead) The patient underwent ileal resection and anastomosis. The histopathology report was consistent with angiodysplasia

Results

All patients underwent triple-phase contrast CT scan following noncontrast CT scan. CE was performed in 16 patients. The CE study could not be completed in one patient due to equipment failure. Eleven patients underwent 99mTc-RBC scintigraphy. DSA was performed in eight patients.

Out of the 50 patients, 24 patients presented with melena, 13 with hematochezia, 6 with hematemesis, and 7 with iron-deficiency anemia (with fecal occult blood positivity in 6 patients) [Table 2].

Positive findings were seen in 32 of the 50 patients [Table 3]. The sensitivity, specificity, positive predictive value, negative predictive value, and accuracy of MDCT were 72.2%, 42.8%, 81.2%, 44.4%, and 68%, respectively [Table 4]. The sensitivity, specificity, positive predictive value, and negative predictive value of CE were 71.4%, 100%, 100%, and 20%, respectively [Table 5]. The sensitivity, specificity, positive predictive value, and negative predictive value of 99mTc-RBC scintigraphy were also calculated [Table 6]. DSA was performed in eight patients and all except one showed findings consistent with the lesions detected on MDCT [Table 7].

Discussion

Detecting the site and cause of GI bleeding is important because without specific therapy, mortality in these patients is approximately 10%.[6] The mortality risk increases by 2–6 fold in older patients and in patients with recurrent bleeding.[7] We conducted this study to assess the role of MDCT in the workup of patients with OGIB.

Figure 3 (A-C): A 37-year-old male with pancreatitis presented with melena. Axial (A), coronal (B) and sagittal (C) contrast-enhanced CT scans show a gastroduodenal artery pseudoaneurysm (arrow)

There are limited data available regarding use of 64-slice MDCT in OGIB. Previous studies have relied on single-phase or dual-phase CT techniques, using single-detector or multidetector spiral CT systems.[8–16] In our study scanning was performed with a 64-slice CT system. We used a triple-phase acquisition (arterial phase, enteric phase, and venous phase), which was designed to optimize detection of most of the common causes of OGIB. Previous angiographic studies suggest that arterial-phase imaging as well as delayed acquisitions are necessary to detect small bowel angiodysplasias.[17] Detection of active bleeding with CT scan requires sufficient delay after intravenous contrast injection to allow accumulation of extravasated contrast material within the bowel lumen. In our study, 50% of the bleeds were due to vascular causes, which are better detected in the arterial phase. Small bowel neoplasms were detected in five patients, which were better seen in the enteric phase. Huprich *et al*., and Jaeckle *et al*., have recommended a triple-phase acquisition protocol to increase the sensitivity for the detection of OGIB.[18,19]

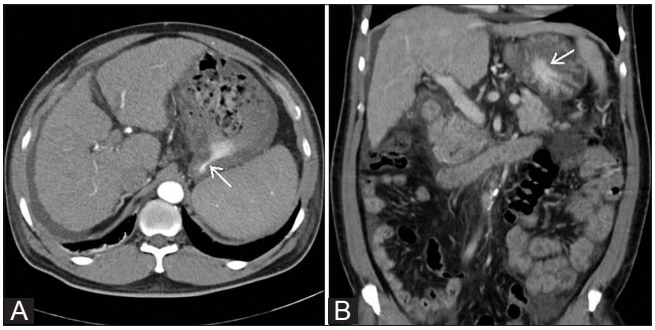

Figure 4 (A, B): A 64-year-old male with cirrhosis of liver presented with melena. Axial (A) and coronal (B) contrast-enhanced CT scans show extravasation of contrast (arrow) in the fundus of the stomach. The bleed was due to portal gastropathy

In our study contrast material (350 mgI_2/ml) was injected at the rate of 4–5 ml/s. Sapreas *et al*. found that four-slice MDCT identified the bleeding source in only 24% of patients when contrast material was injected with a flow rate of 3 ml/s.[20] The authors assumed that this low sensitivity of MDCT might be because of the relatively low injection rate of contrast material. In the study by Huprich *et al*., contrast material (300 mgI_2/ml) was injected with a flow rate of 4 ml/s,[18] and 64-slice MDCT was able to identify the bleeding source in 45% of patients. These findings indicate that sensitivity of MDCT might rise with an increase in the rate of injection.

In a recent study, Huprich *et al*. retrospectively evaluated the role of CT enterography in OGIB in 22 patients. CT showed positive findings in 10 patients (45%).[18] In our study we

Figure 5 (A-C): A case of superior mesenteric artery thrombosis, treated with bypass graft, presented with hematochezia. Axial plain (A) and contrast-enhanced CT scans in the arterial (B), and venous (C) phases show leak of contrast from the graft into the small bowel through a graft-enteric fistula (arrow)

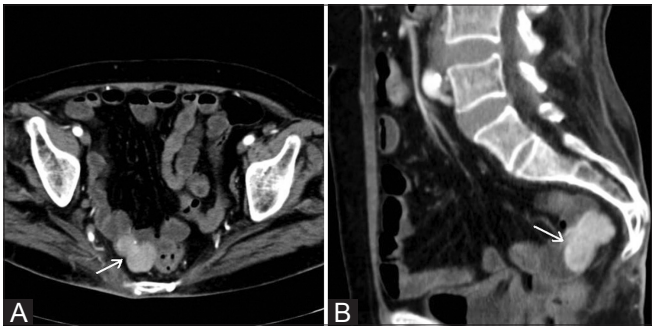

Figure 6 (A, B): An 84-year-old female patient presented with melena. Axial (A) and sagittal (B) contrast-enhanced CT scans show an enhancing intramural mass lesion in the mid-ileum. The operative and histopathological diagnosis was gastrointestinal stromal tumor

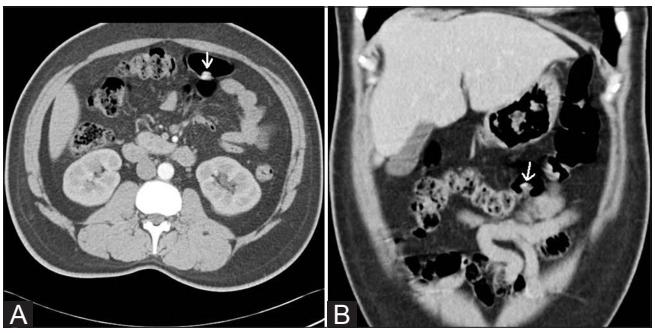

Figure 7 (A, B): A 34-year-old male presented with melena. Axial (A) and coronal (B) contrast-enhanced CT scans show an enhancing vascular polyp (arrow) in the mid-transverse colon. The polyp was missed on initial colonoscopy; it was found on repeat colonoscopy, and polypectomy was done

Table 2: Clinical features of patients

Symptoms	Number of patients	Percentage of patients
Melena	24	48
Hematochezia	13	26
Hematemesis	6	12
Iron-deficiency anemia with fecal occult blood positivity	7	14

Table 3: Diagnosis on multidetector computed tomography

Diagnosis	Number of patients	Percentage of patients
Angiodysplasia/A–V malformation	8	25
Extravasation of contrast	8	25
Tumors/Vascular polyp	6	19
Pancreatitis with complications	3	9.25
Diverticular disease	3	9.25
Graft–enteric fistula	2	6.25
Dissection/aneurysm of infrarenal abdominal aorta	2	6.25

Table 4: Statistical analysis of multidetector computed tomography

	Disease		Total
	Positive	Negative	
Multidetector computed			
Positive	26	6	32
Negative	10	8	18
Total	36	14	

Sensitivity, specificity, positive predictive value, negative predictive value of MDCT in detecting bleeding were 72.2% (95% CI: 59.55% to 84.45%), 42.8%, 81.2%, 44.4% respectively. The accuracy of MDCT (which takes into consideration true positive and true negative results) in detecting bleeding was 68% (95% CI: 55.07% to 80.93%)

Table 5: Statistical analysis of capsule endoscopy

	Disease		Total
	Positive	Negative	
Capsule endoscopy			
Positive	10	0	10
Negative	4	1	5
Total	14	1	

Sensitivity, specificity, positive predictive value, negative predictive value, of capsule endoscopy in detecting bleed were 71.4% (95% CI: 48.04% to 93.96%), 100%, 100%, 20% respectively

Table 6: Statistical analysis of 99mTc-RBC scintigraphy

	Disease		Total
	Positive	Negative	
99mTc-RBC scintigraphy			
Positive	7	0	7
Negative	3	1	4
Total	10	1	

Sensitivity, specificity, positive predictive value, negative predictive value of 99mTc-RBC scintigraphy in detecting bleed was 70.0% (95% CI: 42.92% to 97.08%), 100%, 100%, 25% respectively

Table 7: Comparison of multidetector computed tomography and digital subtraction angiography findings

Multidetector computed tomography	Digital subtraction angiography
Mild contrast blush in jejunum	Second jejunal branch injection – early draining vein with an arteriovenous malformation nidus
Extravasation of contrast in hepatic flexure of colon	Contrast blush in hepatic flexure of colon
Angiodysplasia of distal ileum	Angiodysplasia
Extravasation of contrast in cecum	Angiogram shows no active bleed/ lesion
Cecal hemorrhage	Angiogram shows contrast blush in cecum, with a feeder from a branch of the ileocolic artery
Enhancing mass lesion (GIST) in mid-ileum	Tumor blush in mid-ileum, with a branch of the superior mesenteric artery supplying tumor
Pancreatitis with gastroduodenal artery pseudoaneurysm	Gastroduodenal artery pseudoaneurysm
Mid-ileal arteriovenous fistulas	Mid-ileal A-V fistulas with early draining vein

prospectively evaluated 50 consecutive patients. MDCT detected the source of bleed in 32 patients with sensitivity, specificity, positive predictive value, and negative predictive value of 72.2%, 42.8%, 81.2%, and 44.4%, respectively. The accuracy (i.e., true positives and true negatives) of CT was 68.00% (95% CI: 55.07-80.93%).

CE was positive in 10 out of the 15 patients in whom it was performed (sensitivity: 71.4%). CE and CT scan findings were in agreement in two cases. One patient showed circumferential wall thickening in the distal ileum on CT scan, while CE showed a submucosal bulge with stricture in the distal ileum. The postoperative histopathological diagnosis in this patient was carcinoid. The other patient showed multiple cecal diverticula with diverticulitis on CT scan and active bleed in the cecum on CE [Figure 8]. MDCT was positive in two patients with negative CE findings. One patient showed a moderately enhancing mass in the jejunum on CT scan, which was operated and found to be a GI tumor. Another patient showed a pancreatic pseudocyst eroding into the splenic flexure; this was confirmed at surgery. MDCT was negative in six patients with positive findings in the CE study. Four patients showed small bowel ulcers (in the distal ileum in three patients and in the mid-jejunum in one patient) probably due to nonsteroidal anti-inflammatory drug (NSAID) use [Figure 9]. In the remaining two patients the diagnoses were ileal telangiectasia and Meckel diverticulum respectively. This clearly highlights the fact that mucosal ulcerations are best diagnosed with CE,

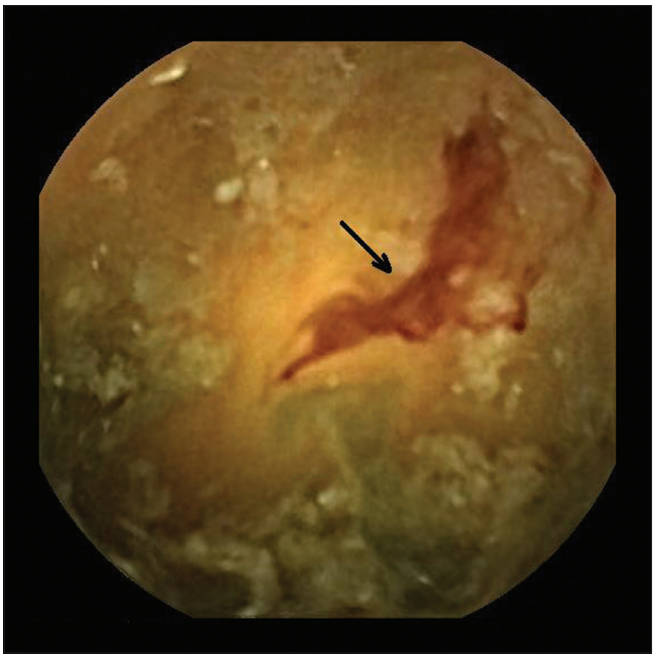

Figure 8: A 64-year-old patient presented with melena. Capsule endoscopy shows active bleed (arrow) in the cecum

Figure 9: An 82-year-old patient presented with melena. Capsule endoscopy shows distal ileal ulcers. CT scan was negative in this patient

whereas extramucosal lesions like tumors require CT scan for diagnosis. However, in two patients with ileal ulcers, CT scan showed other significant findings of dissection of the infrarenal abdominal aorta and aneurysm of the infrarenal abdominal aorta respectively. Both CT scan and CE were negative in two patients in whom 99mTc-RBC scintigraphy showed active bleed in the terminal ileum and ascending colon respectively. Both patients were managed conservatively and are on follow-up, and no further episodes of bleeding have occurred.

Sapreas *et al*. prospectively compared CE with CT scan or standard angiography for the diagnosis of OGIB and concluded that CE detects more lesions than CT scan or standard mesenteric angiography.[20] In our study, while CE had a sensitivity of 71.4%, CT scan showed a greater sensitivity of 72.2%. This is probably due to the fact that 61% of the lesions in our study were extraluminal. However, CE was performed in only 15 patients; a larger cohort of patients may be required to elucidate the true relative roles of these two modalities. CE examination takes a longer time to complete, is expensive, and is available in a few centers only. It also tends to be inconclusive in the presence of massive bleeding (>1 ml/min), where excessive blood in the GI tract obscures details. On the other hand, MDCT is freely available, relatively less expensive, and requires only minutes for completion of examination; moreover, active bleeding can actually increase the detection rate.

In our study, 99mTc-RBC scintigraphy was positive in 7 out of 11 patients in whom it was performed (sensitivity 70%). MDCT and 99mTc-RBC scintigraphy findings were in agreement in four patients. In two patients in whom CT scan showed positive findings, 99mTc-RBC scintigraphy was negative. One patient showed an abnormal blush in the proximal jejunum on CT scan and another showed concentric wall thickening in the distal ileum. However, these patients were managed conservatively, and there were no recurrent symptoms on follow-up. CT scan was negative in three patients with positive findings on 99mTc-RBC scintigraphy. Two were managed conservatively, while in one patient Meckel diverticulum was diagnosed at surgery.

The sensitivity of 99mTc-RBC scintigraphy in patients with obscure overt bleeding is between 15% and 70%.[21–24] The sensitivity for detecting active bleeding (at a rate of 0.1 ml/min) is greater than 90%.[22,24] In a study by Voeller *et al*., 99mTc-RBC scintigraphy failed to localize the bleeding site correctly in 85% of patients.[25] A positive scan cannot provide an etiology for the bleed.[21] CT scan is better for the anatomical localization of the bleed and for detecting its etiology. 99mTc-RBC scintigraphy is probably best reserved for patients suspected to have active bleeding that is not detected by other means and in centers with angiographic capabilities.

DSA was performed in eight patients in our study. All patients except one showed findings consistent with the lesions detected on MDCT. In one patient the angiogram did not show a cecal bleed that was diagnosed on MDCT. Empirical embolization of the ileocolic artery was performed in this patient and further bleeding did not occur. Our study indicates that MDCT has better sensitivity than DSA for detecting the site of bleed and, besides, it also provides a

good vascular road map for surgery or embolization. The sensitivity of angiography in OGIB is between 40% and 80%.[26-28] Angiography demonstrates extravasation of contrast if the rate of bleeding is greater than 0.5 ml/min.[26,27] However, Kuhle *et al*., in a recent publication, have shown that MDCT can detect rates of bleeding as low as 0.5 ml/min.[28] This is comparable to that of catheter angiography. The main advantage of DSA is subsequent intervention that can be done to stop bleeding once a bleed is detected.

Our study conducted in a tertiary referral center included only patients with a diagnosis of OGIB. The sensitivity of MDCT for detecting and diagnosing the cause of a bleed in a more general population may be less than what we observed. The nonavailability of a pathological diagnosis in patients with negative imaging could have affected the estimation of accuracy. CE was performed in only a few patients; a larger cohort of patients will be required to elucidate the true relative roles of these two modalities.

In conclusion, MDCT is a sensitive and noninvasive tool in patients with OGIB, allowing rapid detection and localization of the bleed. MDCT and CE have complementary roles in the evaluation of OGIB. However, the wide availability of MDCT and the speed of examination make it better suited to be a first-line investigation in patients with OGIB after negative upper and lower GI endoscopies.

References

1. Lewis BS. Small intestinal bleeding. Gastrointest Endosc Clin N Am 1994;23:67-91.
2. AGA. American gastroenterological association medical position statement: Evaluation and management of occult and obscure gastrointestinal bleeding. Gastroenterology 2000;118:197.
3. Concha R, Amaro R, Barkin JS. Obscure gastrointestinal bleeding: Diagnostic and therapeutic approach. J Clin Gastroenterol 2007;41:242-51.
4. Willmann JK, Roos JE, Platz A, Pfammater T, Hilfiker PR, Marincek B, *et al*. Multidetector CT: Detection of active hemorrhage in patients with blunt abdominal trauma. AJR Am J Roentgenol 2002;179:437-44.
5. Yoon W, Jeong YY, Shin SS, Lim HS, Song SG, Jang NG, *et al*. Acute massive gastrointestinal bleeding: Detection and localization with arterial phase multi-detector row helical CT. Radiology 2006;239:160-7.
6. Potter GD, Sellin JH. Lower gastrointestinal bleeding. Gastroenterol Clin North Am 1988;17:341-55.
7. Rollins ES, Picus D, Hicks ME, Darcy MD, Bower BL, Kleinoffer MA. Angiography is useful in detection of source of chronic gastrointestinal bleeding of obscure origin. AJR Am J Roentgenol 1991;156:385-8.
8. Duchesne J, Jacome T, Serou M, Tighe D, Gonzales A, Hunt JP, *et al*. CT angiography for the detection of a lower gastrointestinal bleeding source. Am Surg 2005;71:392-7.
9. Grassi R, di Mizio R, Romano S, Cappabianca S, del Vecchio W, Severini S. Multiple jejunal angiodysplasia detected by enema-helical CT. Clin Imaging 2000;24:61-3.
10. Junquera F, Quiroga S, Saperas E, Perez-Lafuente M, Videla S, Alvarez-castells A, *et al*. Accuracy of helical computed tomographic angiography for diagnosis of colonic angiodysplasia. Gastroenterology 2000;119:293-9.
11. Tew K, Davies RP, Jadun CK, Kew J. MDCT of acute lower gastrointestinal bleeding. AJR am J Roentgenol 2004;182:427-30.
12. Miller FH, Hwang CM. An initial experience: Using helical Ct imaging to detect obscure gastrointestinal bleeding. Clin Imaging 2004;28:245-51.
13. Dicle O, Goktay AY. Helical CT angiography in gastrointestinal bleeding. AJR am J Roentgenol 1997;169:1749.
14. Mindelzun RE, Beaulieu CF. Using biphasic CT to reveal gastrointestinal arteriovenous malformations. AJR am J Roentgenol 1997;168:437-8.
15. Yamaguchi T, Yoshikawa K. Enhanced CT for initial localization of active lower gastrointestinal bleeding. Abdom Imaging 2003;28:634-6.
16. Yoshikawa K, Yamaguti T, Nakamura M, Hirayabasi K, Hazano K, Udita M, *et al*. The role of dual-phase enhanced helical computed tomography in difficult intestinal bleeding. J Clin Gastroenterol 2000;31:83-4.
17. Boley SJ, Sprayregen S, Sammartano RJ, Adams A, Kleinhaus S. The pathophysiologic basis for the angiographic signs of vascular ectasias of the colon. Radiology 1997;125:615-21.
18. Huprich JE, Fletcher JG, Alexander JA, Fidler JA, Burton SS, McCullough CH. Obscure gastrointestinal bleeding: Evaluation with 64-slice multiphase CT enterography-initial experience. Radiology 2008;246:56-71.
19. Jaeckle T, Stuber G, Hoffmann MH, Freund W, Schmitz BL, Aschoff AJ. Acute gastrointestinal bleeding: Value of MDCT. Abdom Imaging 2007;33:285-93.
20. Saperas E, Dot J, Videla S, Alvarez-Castells A, Perez-Lafuente M, Armengol JR, *et al*. Capsule endoscopy versus computed tomographic or standard angiography for the diagnosis of obscure gastrointestinal bleeding. Am J Gastroenterol 2007;102:731-7.
21. Howarth DM, Tang K, Lees W. The clinical utility of nuclear medicine imaging for the detection of occult gastrointestinal hemorrhage. Nucl Med (Stuttg) 2002;23:591.
22. McKusick KA, Froelich J, Callahan RJ, Winzelberg GG, Strauss HW. 99mTc red blood cells for detection of gastrointestinal bleeding: Experience with 80 patients. AJR Am J Roentgenol 1981;137:1113-8.
23. Ohri SK, Desa LA, Lee H, Patel T, Jackson J, Lavender JP, *et al*. Value of scintigraphic localization of obscure gastrointestinal bleeding. J R Coll Surg Edinb 1992;37:328.
24. Szasz IJ, Morrison RT, Lyster DM. Technetium-99m-labelled red blood cell scanning to diagnose occult gastrointestinal bleeding. Can J Surg 1985;28:512.
25. Voeller GR, Bungh G, Britt LG. Use of technetium-99m-labelled red blood cell 99mTc-RBC scintigraphy in the detection and management of gastrointestinal hemorrhage. Surgery 1991;110:799.
26. Lau WY, Fan ST, Wong SH, Wong KP, Poon GP, Chu KW, *et al*. Preoperative and intraoperative localization of gastrointestinal bleeding of obscure origin. Gut 1987;28:869.
27. Lau WY, Ngan H, Chu KW, Yuen WK. Repeat selective visceral angiography in patients with gastrointestinal bleeding of obscure origin. Br J Surg 1989;76:226.
28. Kuhle WG, Sheiman RG. Detection of active colonic hemorrhage with use of helical CT: Findings in a swine model. Radiology 2003;228:743-52.

Cite this article as: Kulkarni C, Moorthy S, Sreekumar KP, Rajeshkannan R, Nazar PK, Sandya CJ, *et al*. In the workup of patients with obscure gastrointestinal bleed, does 64-slice MDCT have a role?. Indian J Radiol Imaging 2012;22:47-53.

Source of Support: Nil, **Conflict of Interest:** None declared.