

Radiological Quiz – Genitourinary

A RAO, BS VISWAROOP, A DEVASIA

Ind J Radiol Imag 2006 16:1:143-144

A 50 year old male patient presented to the emergency room in acute retention. There was a history of voiding difficulty for 20 days, but no hematuria or calculia. He was treated for gonococcal urethritis 3 years ago and a year later he noticed small swelling at penoscrotal junction, which increased gradually. On examination he had a hard mobile swelling measuring about 3cms x 3cms at the penoscrotal junction. A suprapubic catheterization was carried out. Plain

radiograph of the pelvis [Fig. 1] and retrograde urethrogram [Fig. 2] were done. Micturating Cystourethrogram done through the suprapubic catheter showed normal urinary bladder with no vesicoureteric reflux. The Ultrasound of urinary bladder and kidneys showed no significant abnormality. Urine microscopy showed a few pus cells. Biochemical parameters were normal. What is your diagnosis?

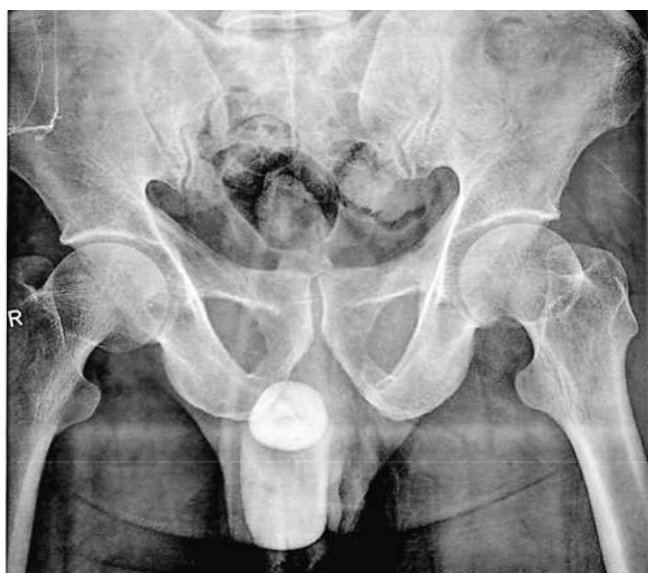

Fig 1

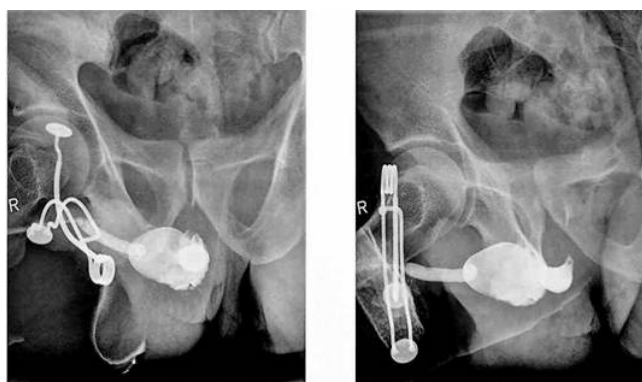


Fig 2

From the Department of Radiodiagnosis¹ and Department of Urology² - Christian Medical College, Vellore -4, Tamilnadu, India: 632004.

Request for Reprints: DR. Ankamma Rao, Lecturer, Department of Radiodiagnosis. Christian Medical College, Vellore -4, Tamilnadu,

Received on 7 April 2005; Accepted 10 October 2005

Radiological Diagnosis

ACQUIRED URETHRAL DIVERTICULUM WITH LARGE CALCULUS.

A urethral diverticulum with calculus was suspected clinically. Plain radiograph of pelvis [Fig: 1] showed the calculus in relation to the anterior urethra at penoscrotal junction. Retrograde urethrogram done after one week of antibiotic course showed a wide mouthed 3cms saccular diverticulum with a smooth filling defect [Fig: 2] in the anterior urethra at the penoscrotal junction. Exploration revealed urethral diverticulum containing pus and a 3x3cms calculus. Diverticulectomy with urethroplasty was done. The procedure was uneventful and following catheter removal he voided with a good stream.

Discussion:

The common form of urethral diverticulum is congenital and seen in males at the penoscrotal junction. Congenital male diverticula are much less common than other urethral abnormalities including posterior urethral valves [1, 2]. Acquired urethral diverticula are rare and common in females but can be seen occasionally in men. The causes for acquired diverticula include trauma, infection, prolonged catheterizations, and periurethral abscess. Etiological factors in congenital diverticula have been summarized by Williams and Retik, and include intrauterine distal urethral stenosis, lesser degree hypospadias or congenital cystic dilatation of the normal or accessory periurethral glands [3].

Complications of the urethral diverticula include infection, stone formation, urinary obstruction, and renal failure and malignancy [4]. Recurrent infection is the most common clinical presentation [4]. Stone formation in diverticula is due to urinary stasis and foreign material accumulation. Clinically these patients have a poor stream and if the diverticulum is large, a palpable or visible swelling may be found on the ventral surface of the penis or the perineum

during voiding. In addition to voiding and retrograde cystourethrography, high-resolution ultrasound (Sonourethrogram) is also useful in the evaluation of urethral diverticulum and its complications. Ultrasound is convenient, rapid, real time study, which can be repeated without radiation exposure to the patients, and cross sectional, longitudinal images can be easily obtained. The disadvantage of the Ultrasound of the penile urethra is its inability to visualize the posterior prostatic urethra without a transrectal approach.

This case highlights the complication of gonococcal infection leading to urethritis, periurethral infection, and giant urethral diverticulum with calculus formation. The management of giant diverticulum in males is by open surgery, preferably a one-step diverticulectomy procedure. In cases, where urethral stenosis or a significant inflammatory involvement of the periurethral tissues is present, a two-stage urethroplasty is preferred [2].

References:

1. Ketabchi. Giant congenital anterior urethral diverticulum. *Iran J Med Sci* 1998; 23:145- 146
2. Gonzalvo Perez V, Botella Almodovar R and et al Urethral diverticulum complicated with giantlithiasis: *Actas Urol Esp* 1998; 22(3): 250-2.
3. Williams DI, Retik AB. Congenital valves and diverticulum of the anterior urethra. *Br J Urol* 1998; 41:228-9.
4. Gerald W. Friedland Editor. Congenital Anomalies of the Urinary Tract. In Howard M Pollack, Bruce L McClennan, *Clinical Urography*. 2nd Edition, Philadelphia, WB Saunders, 2000: 2103-2104.