Article published online: 2021-08-02

01-5

Tunneled coronary artery: case report.

PS GARDE, AA KARANDIKAR, OJ TAVRI, DP PATKAR, AK DALAL

Ind J Radiol Imag 2006 16:3:283-284

Keywords: Tunneled, CT coronary angiography, myocardial

INTRODUCTION:

Tunneled coronary arteries are clinically relevant due to their association with myocardial ischemia.

The coronary arteries may dip into the myocardium for varying lengths and then reappear on the heart surface. The muscle overlying the intramyocardial segment of the epicardial coronary artery is termed as myocardial bridge and the artery coursing within the myocardium in called a tunneled artery. We present a case of tunneled coronary artery, as detected on CT coronary angiography.

CASE REPORT:

A 55 years old non- hypertensive, nondiabetic male presented with atypical chest pain on exertion. His present ECG reveals ST-T changes in the anteroseptal leads. There was history of similar complaint in the past with similar changes on ECG. Conventional catheter angiography done revealed no abnormality.

ECG gated CT coronary angiogram was performed on 16 slice Somatom Sensation 16 (Siemens, Erlangen) with 0.42 secs rotation time. 100 ml of nonionic contrast with a 50ml of saline chase was injected through an antecubital vein with the help of a pressure injector at the rate of 4ml/sec. With a 120 Kv and effective mAs of 600, slice collimation of 0.75 mm, slice width of 1.0mm, reconstruction increment of 0.7mm the scan was performed in 20 secs.

In this study, there was nonvisualisation of mid segment of left anterior descending artery in its normal epicardial course, for a length of approximately 3 cms. Axial raw data , curved MPR (Fig 1a and 1b) and volume rendered images (Fig.2) showed the intramyocardial course of the mid segment of left anterior descending artery. The distal left anterior descending artery is epicardial and shows good opacification. Thus a diagnosis of tunneled mid left anterior descending artery was made.

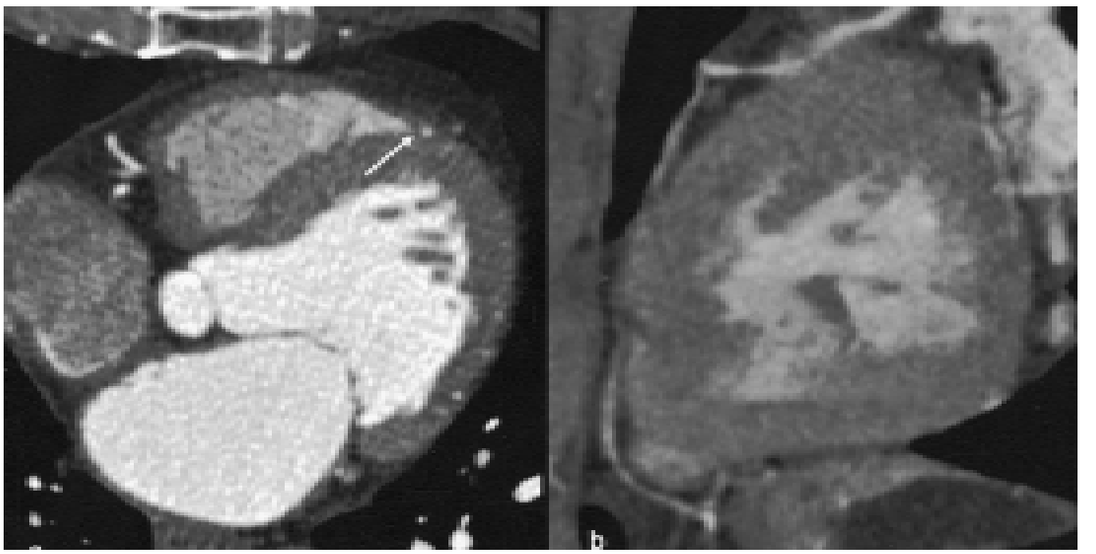

Figure 1-
a- Axial raw data image demonstrates the intramyocardial LAD and the epicardial diagonal branch.
b- Curved MPR image of tunneled LAD.

From the INSIGHT IMAGING CENTRE. A9/10, Gita Building, P. Ramabai Marg, Gamdevi, Mumbai- 400 007.

Request for Reprints: Dr. Parul S. Garde. Narayan niwas, E- block, DL Vaidya Road, Dadar(W), Mumbai-28.

Received 31 January 2006; Accepted 15 May 2006

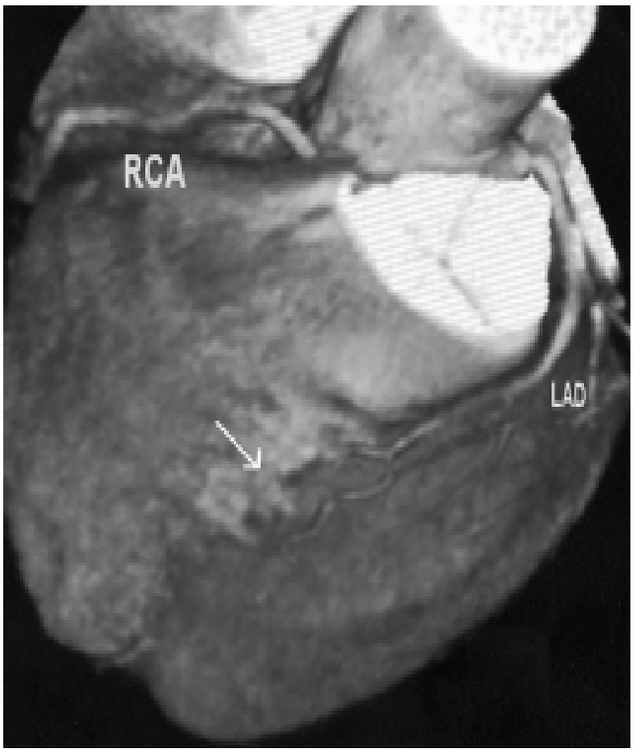

Figure2-
Volume Rendered image showing the entire course of LAD artery. The distal portion of the artery turns epicardial.

Retrospective review of the conventional catheter angiography revealed narrowing of midportion of left anterior descending artery during systole and good opacification of the same during diastole (Fig.3). This confirmed the diagnosis of tunneled artery on the CT coronary angiogram.

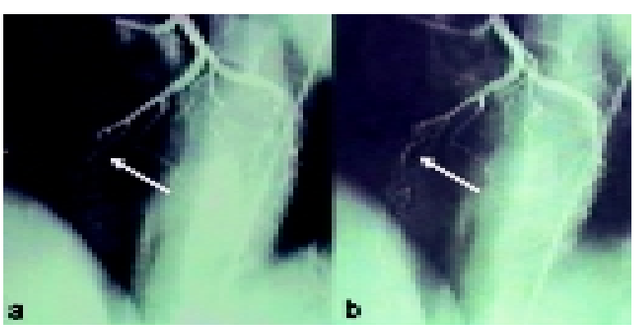

Figure 3-
a- Catheter coronary angiogram obtained during systole.
b- Catheter coronary angiogram obtained during diastole. The LAD artery is better opacified during diastole.

DISCUSSION:

Tunneled coronary arteries have long been recognized anatomically but suggested associations between myocardial ischemia and myocardial bridges have heightened their clinical relevance [1]. They are presumed to be of congenital origin. There is a significant difference in the incidence of tunneled major coronary arteries detected at autopsy (5-86%) as against those detected on angiography (0.5-12%) [2]. Postulated factors for this discrepancy include length of the tunneled vessel, degree of systolic compression, heart rate. Longer segments of tunneled vessel, severe systolic narrowing of the tunneled segment and tachycardia may contribute to the production of myocardial ischemia.

Conventional catheter angiography has been the gold standard of imaging coronary arteries. But tunneled artery may sometimes be missed especially if images are obtained only during systole. There is compression of involved vessel in systole and opacification of the same during diastole.

CT coronary angiography demonstrates the intramyocardial course of the artery. Volume rendered images also help to assess the length of the involved segment.[3,4].

Suggested treatment of symptomatic, myocardial bridges includes [5,6]:

1. Beta and Calcium channel blockers (used to control tachycardia and antispasmodic effects).
2. Surgery - supra arterial myotomy is performed which involves release of the bridge, to obtain relief of symptoms. Postoperative improvement is judged by use of nuclear imaging and intraoperative high frequency echocardiography

BIBLIOGRAPHY

1. Ramzan Akdemir, Huseyin Gunduz, Yunus Emiroglu and Cihangir Uyan. Myocardial bridging as a cause of acute myocardial infarction: a case report. BMC cardiovascular disorders 2002;2:15.
2. Irvin RG. The angiographic prevalence of myocardial bridging in man. Chest 1982, 81: 196-202.
3. Channerks, Bukis E, Hartnell G, Rees JR. Myocardial bridging of the coronary arteries. Clinical Radiology 1983, 40: 355 - 359.
4. M Kulkarni, Aparna Sodani, Rosita, C Puranik, Sunita Sullere, B Saha. Right myocardial bridge on CT Coronary Angiography. JAPI August 2004; 52: 661-662.
5. Betriv A, Tubau J, Sanz G, Magnna J et al. Relief of angina by periarterial muscle resection myocardial bridges. Am. Heart J. 1980, 100: 223 - 226.
6. Watanabe G, Ohhira M, Takemura H, Tanaka N, Iwa T. Surgical treatment for myocardial bridge using intraoperative echocardiography. J Cardiovasc Surg. 1989; 30; 1009-1012.