

Joubert Syndrome

R BAVAHARAN, NS MANI, TMUKUNTHARAJAN, N KARUNAKARAN

Ind J Radiol Imag 2005 15:2:221-222

Key words : - Joubert Syndrome, MRI

Joubert syndrome is a rare autosomal recessive type of congenital cerebellar vermal hypoplasia . It is associated with cystic lesions of the abdominal organs. Here we present a case of Joubert syndrome. This case was interesting as it was associated with papillary cystadenoma of the pancreas , paraovarian cyst and Patent Ductus Atrteriosus which are rare association with this entity.

CASE REPORT:

A 14 year old mentally retarded girl presented with history of non specific abdominal pain. On examination she had ataxic gait with horizontal,coarse nystagmus.

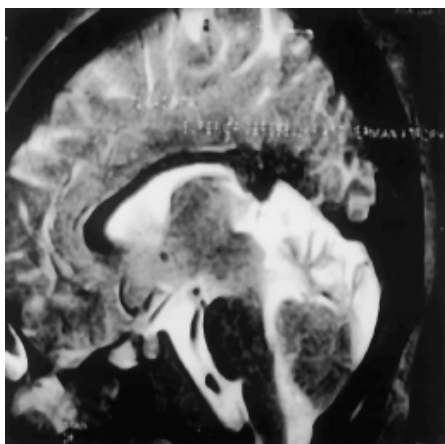


Fig1- T1 axial shows horizontally placed superior cerebellar peduncle with secondary prominence of fourth ventricle.

Ultrasound examination of abdomen and pelvis revealed cystic lesion in head of pancreas, Bilateral polycystic kidney with right para-ovarian mass.

MRI Brain revealed elongated,horizontally placed superior cerebellar peduncle(Molar Tooth sign) - (Fig1), vermian atrophy and corpus colossal dysgenesis (Fig2) ,Batwing

shaped fourth ventricle(Fig3) ,Bullet shaped third ventricle(Fig4).

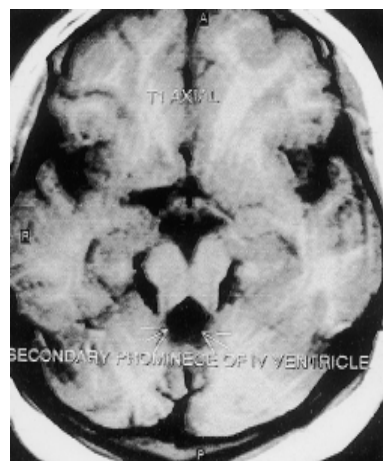


Fig2- T2W sagittal shows vermian atrophy with corpus colossal dysgenesis

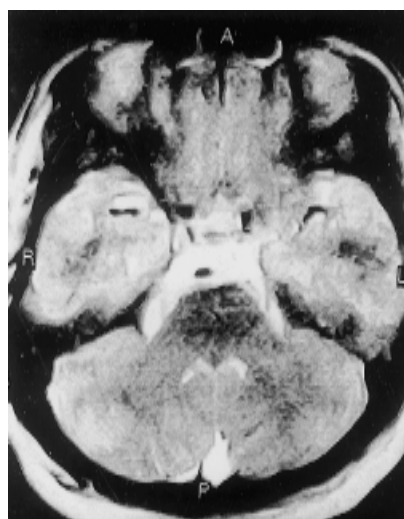

Fig3- T2W axial shows Bat wing shaped fourth ventricle.

From the Department of Imaging Sciences , Meenakshi Mission Hospital & Research Centre, Madurai, TamilNadu.

Request for Reprints: Dr NS Mani, Department of Imaging Sciences , Meenakshi Mission Hospital & Research Centre, Madurai, TamilNadu.

Received 1 December 2004; Accepted 15 March 2005

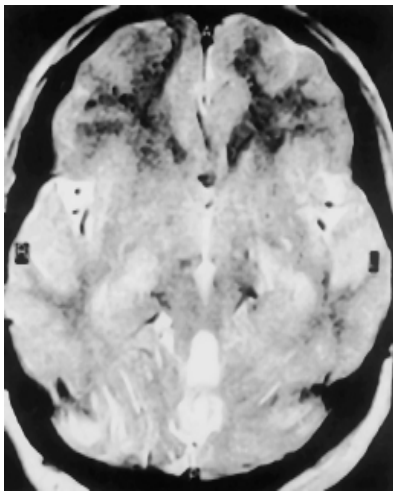


Fig4- T2W axial shows Bullet shaped third ventricle

In view of her pancreatic cystic disease , laparoscopic cystectomy done .The biopsy report revealed it as solid and cytic papillary neoplasm. In the post operative period she developed shortness of breath for which echo was done which revealed small Patent Ductus Arteriosus. But progressively she improved of her respiratory symptoms and was discharged.

DISCUSSION:

Cerebellar deformities can be broadly divided into 3 main groups

- 1) Partial Vermian agenesis
- 2) Subtotal agenesis
- 3) Cystic malformations of Posterior fossa

Joubert syndrome is an autosomal recessive type of cerebellar maldevelopment (especially vermian agenesis).Most common in males. May be associated with DandyWalker malformation , Werding-Hoffman

disease,occipital encephaloceles.

Clinical features include neonatal hyperpnea or apnea, poor visual development with oculomotor disturbances, colobomas, ataxia, mental retardation.

Pathological features include nearly total aplasia of cerebellar vermis, dysplasia and heteropia of cerebellar nuclei, pyramidal decussations, inferior olivary nucleus, solitary fascicles and dorsal column nuclei may be absent.

MRI of brain shows Cerebellar hemispheres are seperated in midline cerebellar vermian agenesis (neuronal migration anomaly),Horizontally placed superior cerebellar peduncles ("Molar tooth sign"), Superior cerebellar peduncle surrounded by CSF, Bat-wing appearance of enlarged fourth ventricle, Enlarged Cysterna Magna and Tectum may be dysplastic.

It is associated with Cystic Renal disease, Retinal Dysplasia,and Dysgenesis of Corpus collosum.

other causes of vermian dysgenesis include

- Dandy Walker Syndrome
- Down Syndrome
- Retrocerebellar cysts
- Chiari malformations
- Congenital Oculomotor apraxia Syndrome
- Rhombencephalosynapsia

References

1. Neuroradiology - The Requisites, Grossman, Mosby, 2003, p433,434
2. Radiology Review manual, Wolfgang Dahnert, Lippincot, 1999, p247
3. Cerebellar Anomalies, Clinival Neuroradiology, Radiology on CD-ROM, Lippincot-Raven, 2001