Article published online: 2021-07-27

Role of penumbra mechanical thrombectomy device in acute dural sinus thrombosis

Suraj Mammen, Shyamkumar Nidugala Keshava, Vinu Moses, Sanjith Aaron[1], Munawwar Ahmed, George K Chiramel, Sunithi E Mani, Mathew Alexander[1]

Departments of Radiology, [1]Neurology, Christian Medical College, Vellore, Tamil Nadu, India

Correspondence: Dr. Shyamkumar Nidugala Keshava, Department of Radiology, Christian Medical College, Vellore, Tamil Nadu, India. E-mail: aparna_shyam@cmcvellore.ac.in

Abstract

Background: In dural venous sinus thrombosis (DVST), the mortality ranges 5–30%. Deep venous system involvement and septic dural sinus thrombosis have a higher mortality rate. In acute occlusion, collateral flow may not be established, which may result in significant edema and mass effect. Endovascular interventions may be considered as a treatment option in appropriate high-risk patients with DVST. **Materials and Methods:** Eight patients with magnetic resonance imaging (MRI)-confirmed dural sinus thrombosis, who did not respond to the conventional standard medical treatment, were subsequently treated with mechanical thrombectomy using the Penumbra System®. In all cases, medical treatment including anticoagulants were continued following the procedure for a minimum period of 1 year. **Results:** Recanalization of the dural sinus thrombosis was achieved in all 8 cases. There were no immediate or late endovascular-related complications. One death occurred due to an unrelated medical event. At 6 months, there was notable improvement in the modified Rankin Score (mRS), with 5/8 (62%) patients achieving mRS of 2 or less. The follow-up ranged between 3 months and 26 months (mean: 14.5 months), and there were no new neurological events during the follow-up period. **Conclusion:** Cerebral venous sinus thrombosis is a rare but life-threatening condition that demands timely diagnosis and therapy. In cases of rapidly declining neurological status despite standard therapy with systemic anticoagulation and anti-edema measures, mechanical thrombectomy could be a lifesaving and effective option. In this study, good outcomes were observed in the majority of patients at long-term follow up.

Key words: Dural sinus thrombosis; neurointervention; recanalization; thrombectomy

Introduction

Cerebral venous sinus thrombosis (CVST) was first described by Ribes in 1825.[1] The mortality and morbidity from CVST in various prospective studies range between 8.8% and 44.4%.[2] Conditions predisposing to dural sinus thrombosis include puerperium, trauma, malignancy, disseminated intravascular coagulation, hypercoagulable states, infections, medications (e.g., synthetic steroids and contraceptive hormones), connective tissue disorders, and dehydration.[3] In contrast to arterial infarction, CVST commonly occurs in the young. The absence of pathognomonic features can delay diagnosis. Headache is the most common symptom (80–90%), other common presentations are focal or generalized seizures, focal

Access this article online	
Quick Response Code:	Website: www.ijri.org
	DOI: 10.4103/0971-3026.202956

Cite this article as: Mammen S, Keshava SN, Moses V, Aaron S, Ahmed M, Chiramel GK, *et al*. Role of penumbra mechanical thrombectomy device in acute dural sinus thrombosis. Indian J Radiol Imaging 2017;27:82-7.

neurological deficits, and alteration in sensorium.[4] Occlusions in the superficial venous system are better tolerated and has a better prognosis than thrombosis in the deep venous system because of the extensive collateral supply.[3] The treatment is aimed at opening up of the occluded sinuses by systemic anticoagulation and giving antiedema measures in the acute phase. Surgical decompression may be the option in cases with a large infarct volume and midline shift.[5] In cases where there is no significant improvement following systemic anticoagulation, direct thrombolysis and mechanical thrombectomy can be considered.

Here, we review the techniques and indications for endovascular treatment of CVST and long-term results in 8 cases of dural venous sinus thrombosis (DVST) that underwent mechanical thrombectomy with Penumbra device with or without concurrent balloon angioplasty and chemical thrombolysis.

Materials and Methods

Out of the 243 cases of acute CVT treated in a quaternary level teaching hospital over a period of 4 years, 8 underwent mechanical thrombectomy using the Penumbra system, with or without concurrent balloon angioplasty and chemical thrombolysis. The ages ranged from 20–40 years, with all the patients being females. In all 8 patients, the common presenting feature was headache [Table 1]. In 5/8 patients, there was involvement of the superficial venous system, and in the rest there was involvement of the superficial and deep system. Seven out of 8 cases had venous infarct on the magnetic resonance imaging (MRI) before endovascular thrombectomy was performed [Figure 1].

All patients were initially managed medically, systemic anticoagulation (intravenous unfractionated heparin) was started to keep the target PTT >1.5 times the control. Anticonvulsants were started in patients who presented with seizures and also were given prophylatically to others with large venous infarcts involving the cerebral cortex. All patients were treated for raised intracranial pressure with acetazolamide (Dose ranging from 250 mg thrice a day to 500 mg thrice day), intravenous dexamethasone, and hypertonic (3%) saline. These patients were taken up for endovascular thrombectomy after clinical and radiological worsening.

In 5 out of 8 cases, balloon angioplasty was concurrently used along with the Penumbra System (Penumbra, Alameda, USA). In the remaining 3 cases, however, Penumbra mechanical clot retrieval was performed in conjunction with balloon angioplasty and chemical thrombolysis. The clinical outcome was measured based on the modified Rankin score (mRS).

Transarterial cerebral angiography was not routinely performed to survey the DVST detail, except when required. Penumbra mechanical clot retrieval was done with additional balloon angioplasty and chemical thrombolysis were carried out on as required basis. A 6F Envoy guide catheter (Codman & Shurtleff, Inc, Raynham, MA, USA) was first advanced through the femoral vein and placed at the base of the skull. The blocked dural sinuses were approached using an anteroposterior, lateral, or a combination of both projections. Using a 300 cm 0.014 in microwire, a 032″ Penumbra reperfusion microcatheter was advanced retrogradely into the anterior two-thirds of the superior sagittal sinus. To disrupt the thrombus, 5 mg tPA, or 2L Urokinase was administered or a 3–5 mm balloon angioplasty was performed up to 2–3 times from the distal to the proximal end of the occlusion to sufficiently extract the thrombus. Then using a Penumbra reperfusion catheter–separator combination, thrombus extraction was performed [Figures 2-5]. In cases where there was no significant angiographic recanalization of the sinus after 2 or 3 passes of the Penumbra device along with thrombolysis/angioplasty, the procedure was discontinued.

Medical management was continued in all patients. A repeat magnetic resonance venography (MRV) was performed if the patient showed no significant clinical improvement after 2–3 days. After discharge, the patient was followed up with, mRS score assessment and fundal examination.

Recanalization of the dural sinus thrombosis was achieved in all 8 cases. Three showed complete recanalization, whereas 4 showed partial recanalization. There were no hemorrhagic events during or after the procedure in any of

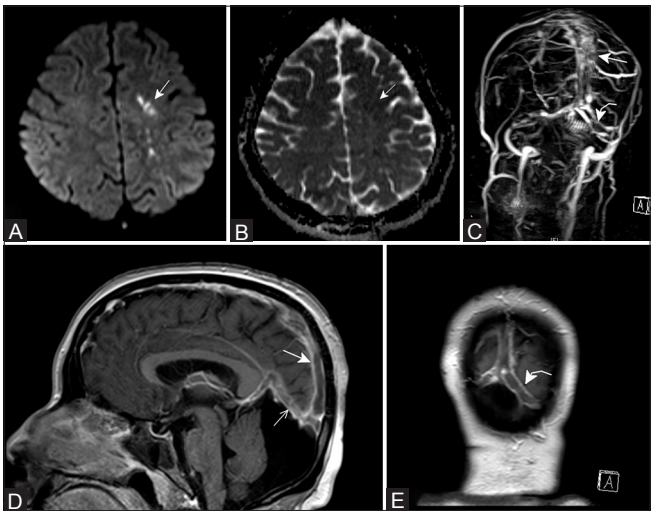

Figure 1 (A-E): MRI brain showing areas of restricted diffusion in deep white matter of bilateral frontal lobes (arrow) in both diffusion (A) and ADC maps (B) suggestive of infarcts. There is extensive subacute thrombosis of the entire superior sagittal sinus (straight arrow), both transverse sinuses (curved arrow), straight sinus (thin arrow), and multiple cortical veins in the MRV images (C-E)

Table 1: Clinical and radiological profile

	Age/sex	Presentation	Imaging findings	Procedure performed	Immediate procedure outcome	Complication	Outcome in the follow-up MRI
Case 1	36/F	Worsening headache with bilateral visual loss (B/L papilledema)	SSS, SS, internal cerebral vein, both TS, multiple cortical veins	Penumbra + 5 mm × 80 mm balloon plasty	Partial recanalization of SSS, TS, SS and cortical vein	Nil	Venous infarcts, recanalization of superior sagittal sinus, sigmoid sinus, partial of left transverse sinus
Case 2	33/F	TB on ATT, sudden onset progressive weakness of left upper and lower limb, GTCS	SSS, left TS, Sigmoid sinus	Penumbra + 3 mm × 40 mm balloon plasty	Venous infarcts, partial recanalization of the SSS, left TS, left sigmoid sinus	Nil	Recanalization of the SSS, non-visualization of the left sigmoid sinus and transverse sinus
Case 3	21/F	26-week amenorrhoea, headache × 1 month, GTCS	SS, left TS, left sigmoid sinus and left IJV	Penumbra + 5 mm × 60 mm balloon plasty	Partial recanalization of left transverse sinus and sigmoid sinus	Nil	Follow MRI was not done, Clinically normal
Case 4	30/F	Fever, headache and altered sensorium	SSS, bilateral transverse sinus, right sigmoid sinus, SS, multiple cortical veins, probably the left internal cerebral vein, extensive venous infarct	Penumbra + 5 mg rtPA + 5 mm × 18 mm balloon plasty	No significant recanalization of SSS, complete recanalized sigmoid sinus and transverse sinus	Nil	MRI not done as patient died on the 4th day
Case 5	16/F	Headache, vomiting, right side weakness	SS, basal vein of Rosenthal, right basal ganglia haemorrhagic infarct and diffuse gyral swelling	Penumbra + 5 mm × 4 mm plasty	No significant recanalization of the straight sinus	Nil	Near total recanalization of SS, basal vein of Rosenthal, and significant reduction in the gyral swelling
Case 6	38/F	Headache, altered sensorium	SSS, Torcula, right TS, right SS, right IJV, scattered patchy white matter infarcts	500,000 units Urokinase, balloon venoplasty, followed by Penumbra	Partial recanalization	Nil	Partial recanalization of SSS, right TS, right sigmoid sinus, scattered patchy white matter infarcts
Case 7	40/F	Headache, left sided weakness, altered sensorium	Right TS, internal cerebral vein, straight sinus, venous infarct in the thalami and right cerebellar hemisphere	200,000 units Urokinase, 3 mm × 20 mm balloon venoplasty, Penumbra	No significant recanalization of the straight sinus	Nil	Follow MRI was not done
Case 8	18 year/F	Primigravida with 10 days h/o holocranial headache, 1 episode of GTCS requiring mechanical ventilation, no significant improvement in her sensorium after 2 days of conservative management	SSS, B/L TS, B/L SS, with venous infarcts in the left high frontal and right high parietal	3 mm × 6 cm balloon, Penumbra	No significant recanalization of SSS. In view of multiple radiations and teratogenic medications medical termination of pregnancy was performed	No procedure related complication, nosocomial pneumonia	Repeat MRI not done post intervention, however Modified Rankin Score of 1 at 3 month follow-up

B/L: Bilateral, SSS: Superior Sagittal Sinus, SS: Straight Sinus, TB: Tuberculosis, ATT: Anti Tubercular Treatment, GTCS: Generalized Tonic Clonic Seizure. No significant recanalization: Segmental recanalization, without antegrade flow into internal jugular vein

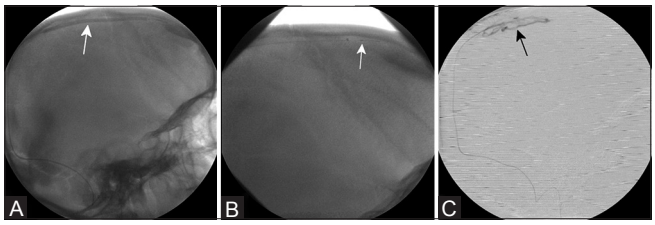

Figure 2 (A-C): Thrombolysis was done by angioplasty (A) with a 3 mm × 10 cm balloon (arrow) followed by mechanical thrombectomy (B) with a Penumbra catheter system (arrow). No significant recanalization of superior sagittal sinus (arrow), transverse, and sigmoid sinuses in the post-thrombolysis venogram (C)

the patients, nor any immediate or late endovascular-related complications was detected. One patient died due to unrelated viral encephalitis. In the remaining cases, the mRS score and fundal findings improved with gradual improvement in the mRS score. Good improvement was noted at 6 months with mRS 0–2 in 5/8 (62%) cases [Table 2]. Patients were followed for a mean of 14.5 months (range: 3 months to 26 months); there were no new neurological events during the follow-up period. None of the patients developed recurrence of dural sinus thrombosis.

Discussion

Venous sinus thrombosis is a rare and potentially life-threatening condition, with a 30-day fatality rate of 3.4% in a multicentre international prospective study.[2] Intravenous anticoagulation with heparin, followed by oral anticoagulation is the front-line treatment. When

the clinical condition fails to respond despite standard medical management, endovascular therapy can be undertaken.[6] All 8 patients described here were young, otherwise healthy individuals with severe and progressive neurological symptoms in spite of standard medical therapy.

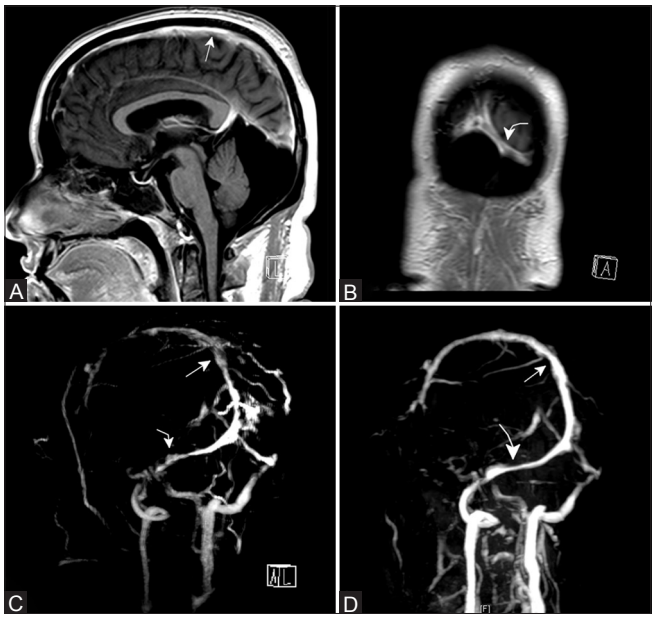

Figure 3 (A-D): MRV done 5 days after thrombolysis (A-C) shows partial resolution of thrombus in the superior sagittal sinus (straight arrow), transverse sinus (curved arrow), and straight sinus with residual filling defects. MRV done two and a half years later (D) shows near complete recanalization of the superior sagittal sinus (straight arrow), transverse (curved arrow) and sigmoid sinuses, and straight sinus

Before the era of mechanical thrombectomy devices, endovascular chemical thrombolysis was performed by infusion of Urokinase or tPA.[7-10] Dentali *et al*.[10] found that local thrombolysis was associated with a non-negligible incidence of major bleeding complications, including intracranial bleeding, potentially affecting patient outcome. In this study, Urokinase was used because it was readily available and less expensive than rTPA. In only one case tPA was used.

The use of mechanical thrombectomy with or without concurrent chemical thrombolysis has been reported using other devices, such as balloon angioplasty, the Angiojet Rheolytic catheter (Possis Medical, Minneapolis, Minnesota, USA), the Merci Retriever device (Concentric Medical, Mountain View, California, USA), and the Solitaire FR retrieval device (Covidien, Irvine, CA, USA), with each having their own inherent limitations.[11] In 3 out of 8 cases, thrombolysis was combined with balloon angioplasty and mechanical thrombectomy to aid in clot retrieval.

Here, we report possibly the largest series using the Penumbra system for mechanical thrombectomy in DVST. The Penumbra system is a modification of the manual proximal aspiration technique and consists of a dedicated reperfusion catheter connected to a pump, which applies continuous aspiration. A microwire with an olive-shaped tip called the separator is used to clear the tip of the reperfusion catheter from clot fragments to avoid obstruction. The PS has shown safety and efficacy in the mechanical treatment of acute ischemic stroke due to thromboembolism.[8,12] In this report, the procedures

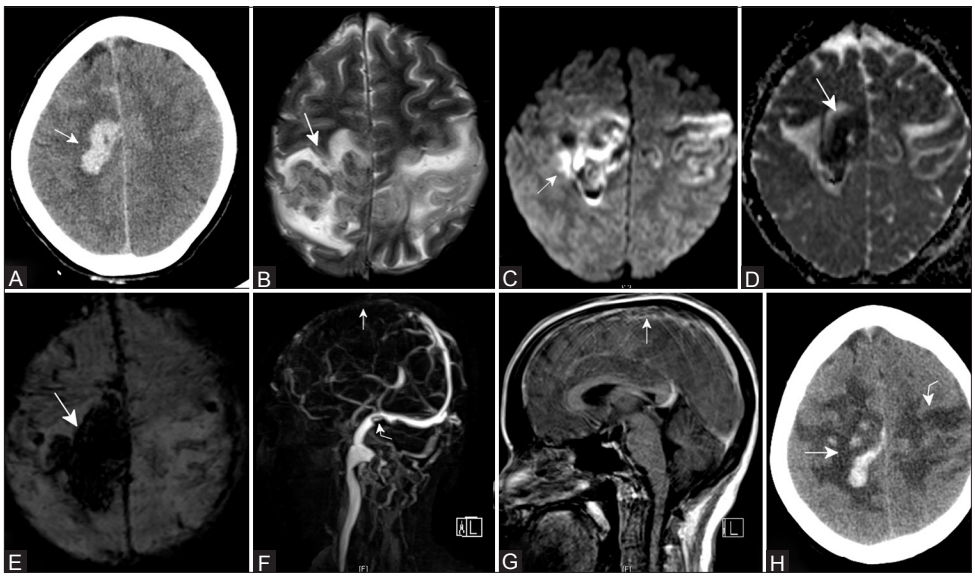

Figure 4 (A-H): Non-contrast CT brain axial images shows hyperdense area (arrow) in the parasagittal aspect of right high parietal region suggestive of a haemorrhagic infarct (A) MRI brain done the next day shows heterogeneous lesion (arrows) in FLAIR and T2 (B-D) with blooming on SWI (E) in right parasagittal parietal region keeping with a infarct with haemorrhagic transformation. MRV shows filling defects in the superior sagittal sinus (straight arrow), right transverse (curved arrow) and sigmoid sinuses (F and G). CT brain done 6 days later shows (H) increase in haemorrhagic component in the right high fronto-parietal region (straight arrow) and new hypodense lesion in left high fronto-parietal region (curved arrow) with small foci of haemorrhage

Table 2: Patient follow up (showing the Modified Rankin Score over 2 years)

Patient number	Modified Rankin Score at discharge	Modified Rankin Score at 3 months	Modified Rankin Score at 6 months	Modified Rankin Score at 12 months	Modified Rankin Score at 24 months
Case 1	3	3 Visual loss due to bilateral secondary optic atrophy	3	3	3
Case 2	4	4	3	2	2
Case 3	3	2	2	No follow after 6/12	
Case 4	6	NA	NA		
Case 5	3	2	2	1	1
Case 6	4	3	2	2	1
Case 7	2	1	1	1	1
Case 8	2	1	1	1	1

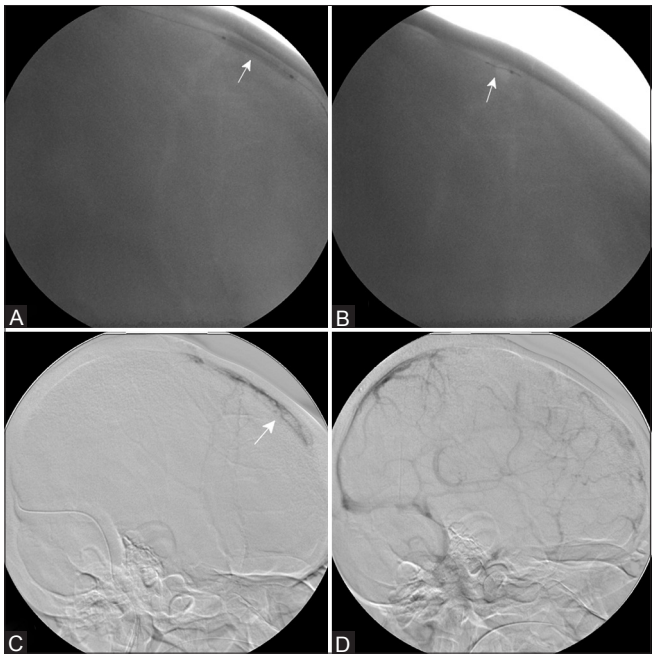

Figure 5 (A-D): Thrombolysis was done by balloon angioplasty (A) using a 3 mm × 4 cm balloon (arrow) followed by mechanical thrombectomy (B) using a Penumbra thrombectomy device (arrow). Post-thrombolysis venogram (C) shows minimal recanalization of the anterior superior sagittal sinus (arrow) and angiogram (D) showed no flow in the anterior superior sagittal sinus but a patent posterior segment of superior sagittal sinus

utilized a 0.41 or 0.32 inch Penumbra system reperfusion catheter based on the ease of the wire to traverse the thrombus. Balloon angioplasty augmentation was performed in cases where the Penumbra system separator did not macerate the clot independently to allow optimum aspiration using the reperfusion catheter.

While most cases did not demonstrate significant recanalization in the immediate post-thrombolysis imaging, they showed improvement in their clinical course after the procedure as well as significant resolution in the follow-up imaging [Figures 3D and 6]. There were no intraprocedural complications and no procedure-related complications postoperatively. The mean follow-up period in this study was 14.5 months, which is unique compared to other similar

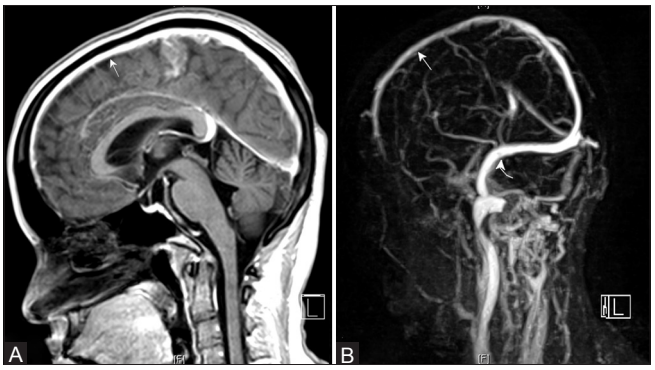

Figure 6 (A and B): MRV done 4 months later (A and B) showed near complete recanalization of the superior sagittal sinus (straight arrow), right transverse (curved arrow), and sigmoid sinuses

studies.[6] None of the patients had recurrent dural sinus thrombosis during the follow-up period. A multicentre randomized controlled trial may be required to measure the clinical efficacy on a large sample size.

Conclusion

Cerebral venous sinus thrombosis is a rare but life-threatening condition that demands timely diagnosis and therapy. In cases of rapidly declining neurological status despite standard therapy of systemic anticoagulation, mechanical thrombectomy appears to be a safe and effective method when used alone or in combination with catheter-directed chemical thrombolysis.

Financial support and sponsorship

Nil.

Conflicts of interest

There are no conflicts of interest.

References

1. Medel R, Monteith JS, Crowley WR, Dumont SA. A review of therapeutic strategies for the management of cerebral venous sinus thrombosis. Neurosurg Focus 2009;27:E6.
2. Ferro JM, Canhão P, Stam J, Bousser MG, Barinagarrementeria F; ISCVT Investigators. Prognosis of cerebral vein and dural sinus

thrombosis: Results of the International Study on Cerebral Vein and Dural Sinus Thrombosis. Stroke 2004;35:664-70.

3. Chow K, Gobin YP, Saver J, Kidwell C, Dong P, Viñuela F. Endovascular Treatment of Dural Sinus Thrombosis With Rheolytic Thrombectomy and Intra-Arterial Thrombolysis. Stroke 2000;31:1420-5.
4. Bentley NJ, Figueroa ER, Vender RJ. From presentation to follow-up: Diagnosis and treatment of cerebral venous thrombosis. Neurosurg Focus 2009;27:E4.
5. Aaron S, Alexander M, Moorthy RK, Mani S, Mathew V, Patil AK, *et al*. Decompressive craniectomy in cerebral venous thrombosis: A single centre experience Neurol Neurosurg Psychiatry 2013;84:995-1000.
6. Choulakian A, Alexander MJ. Mechanical thrombectomy with the penumbra system for treatment of venous sinus thrombosis. J Neurointerv Surg 2010;2:153-6.
7. Gerszten PC, Welch WC, Spearman MP, Jungreis CA, Redner RL. Isolated deep cerebral venous thrombosis treated by direct endovascular thrombolysis. Surg Neurol 1997;48:261-6.
8. Rahman M, Velat JG, Hoh BL, Mocco J. Direct thrombolysis for cerebral venous sinus thrombosis. Neurosurg Focus 2009;27:E7.
9. Mohammadian R, Sohrabi B, Mansourizadeh R, Mohammadian F, Nazempour A, Farhoudi M, *et al*. Treatment of Progressive Cerebral Sinuses Thrombosis with Local Thrombolysis. Interv Neuroradiol 2012;18:89-96.
10. Dentali F, Squizzato A, Gianni M, De Lodovici ML, Venco A, Paciaroni M, *et al*. Safety of thrombolysis in cerebral venous thrombosis. A systematic review of the literature. Thromb Haemost 2010;104:1055-62.
11. Siddiqui FM, Banerjee C, Zuurbier SM, Hao Q, Ahn C, Pride GL, *et al*. Mechanical Thrombectomy versus Intrasinus Thrombolysis for Cerebral Venous Sinus Thrombosis: A Non-Randomized Comparison. Interv Neuroradiol 2014;20:336-44.
12. Penumbra Pivotal Stroke Trial Investigators. The Penumbra pivotal stroke trial I: Safety and effectiveness of a new generation of mechanical devices for clot removal in intracranial large vessel occlusive disease. Stroke 2009;40:2761-8.