

# Inguinoscrotal hernia in infants: Three case reports in ultrasound diagnosis

Dharmraj Meena, Richa Jhuria, Sangeeta Saxena, Umesh Saini

Department of Radiodiagnosis, Govt. Medical College and Associated Group of Hospitals, Kota, Rajasthan, India

**Correspondence:** Dr. Dharmraj Meena, Department of Radiodiagnosis, Govt. Medical College and Associated Group of Hospitals, Kota - 324 001, Rajasthan, India. E-mail: dr.dharmrajmeena9875@hotmail.com

## Abstract

An inguinal hernia occurs when an intestinal loop or part of the omentum or genital organs passes into the scrotal cavity or labia through an incompletely obliterated processus vaginalis. Inguinal hernias are most common in preterm neonates, especially at 32-weeks gestation. Content of hernia is mostly bowel and ovary/testicles. Presence of uterus in herniated sac is rare, and only few cases are reported in literature. Hernia is more frequently located on the right side because the right processus vaginalis closes later than the left. Physical examination is sufficient to enable diagnosis in most cases. Ultrasound examination is indicated in patients with inconclusive physical findings, in patients with acute scrotum, and to investigate contralateral involvement in patients in whom only a unilateral hernia is clinically evident. Routinely, color or power Doppler imaging is used in inguinal-scrotal hernia to investigate intestinal and testicular/ovarian perfusion. Urgent surgery is indicated in patients with an akinetic dilated bowel loop (a sign of strangulation) or impaired testicular/ovarian perfusion.

**Key words:** Hernia; incarceration; inguinoscrotal; omentum; processus vaginalis

## Introduction

Congenital anomaly of infancy and childhood includes indirect inguinal hernia with an incidence ranging from 0.8% to 4%, which is more prevalent in premature infants at 30%. One-third of all children with hernias present before 6 months of age, and most hernias occur in males, with a male to female ratio of 6:1.<sup>[1]</sup> The herniated sac may contain the intestines, omentum, fluid, testes, ovaries, fallopian tubes, uterus, and urinary bladder. The incidence of herniated sac containing ovaries and the fallopian tubes are approximately 15–20% in female infant.<sup>[2]</sup> However, inguinal hernias containing the uterus and an ipsilateral ovary are infrequent. Furthermore, inguinal hernias that contain the uterus and both ovaries are thought to be extremely rare, and only few cases have been reported in the literature.<sup>[3]</sup>

Few of these hernia show spontaneous regression;<sup>[4]</sup> however, if the content of herniated sac is ovaries and/or intestinal structures, it reduces the chance of spontaneous regression, along with increasing the chance of incarceration.<sup>[5-7]</sup> Hence, early diagnosis and appropriate intervention is required before an irreversible damage occurs to the herniated structure. Ultrasonography with color Doppler is first line and a very effective diagnostic tool for the evaluation of inguinal lesions.

## Case Reports

In this paper, three cases of infantile inguinal hernia are included. Two female infant, one having uterus and both

### Access this article online

#### Quick Response Code:



**Website:**  
www.ijri.org

**DOI:**  
10.4103/0971-3026.202951

This is an open access article distributed under the terms of the Creative Commons Attribution-NonCommercial-ShareAlike 3.0 License, which allows others to remix, tweak, and build upon the work non-commercially, as long as the author is credited and the new creations are licensed under the identical terms.

**For reprints contact:** reprints@medknow.com

**Cite this article as:** Meena D, Jhuria R, Saxena S, Saini U. Inguinoscrotal hernia in infants: Three case reports in ultrasound diagnosis. Indian J Radiol Imaging 2017;27:78-81.

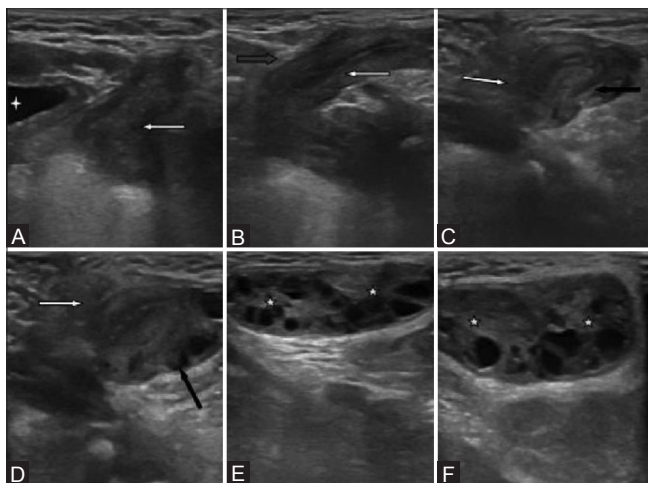
ovaries, other having one ovary as sac content, and one male infant with herniation of bowel with incarceration.

#### Case 1

A 3-month-old female infant, who was born at 36 weeks of gestation with birth weight of 2300g, presented to the pediatric outpatient department (OPD) for increasing swelling at the left labial region since last 5 days, along with complaints of on and off swelling 3 times since birth; however, at presentation, the swelling was larger as compare to the previous state. During physical examination, two separate oval structures were palpated, which were nontender, along with normal appearing overlying skin. Provisional diagnosis was of indirect inguinal hernia containing either ovary or testis. The patient was send for ultrasonography for further confirmation. Ultrasound using high frequency probe showed two oval structures having multiple small anechoic cysts at left labial region with a hypoechoic structure having internal echogenic strip, which was continued in abdominal cavity through a defect in abdominal wall of 6.6 mm. Hence, USG findings were suggestive of indirect inguinal hernia containing uterus and bilateral ovary [Figure 1]. At colour Doppler ultrasound normal arterial vascularity was detected in bilateral ovary, suggesting viable ovarian tissue [Figure 2]. The baby was operated by the pediatric surgeon, and at the operation, both ovary with uterus were herniated into the left inguinal canal and left labia majora. A surgical reduction procedure of herniated structure and high inguinal ligation was performed.

#### Case 2

A 1-month-old male infant present to pediatric emergency OPD with complaints of painful left inguinoscrotal swelling.



**Figure 1 (A-F):** On ultrasonogram; A to F showing sequential images of herniation of uterus and bilateral ovary in left inguinal region in a 3-month-old female infant having left inguinal and left valva swelling. (A) Urinary bladder (white star) and laterally uterus (white arrow). (B) Herniation of uterus through anterior abdominal wall (blue arrow). (C, D) Uterus and one ovary in the herniated sac at labia majora region. (E, F) Both ovaries (yellow stars) having peripherally oriented follicles

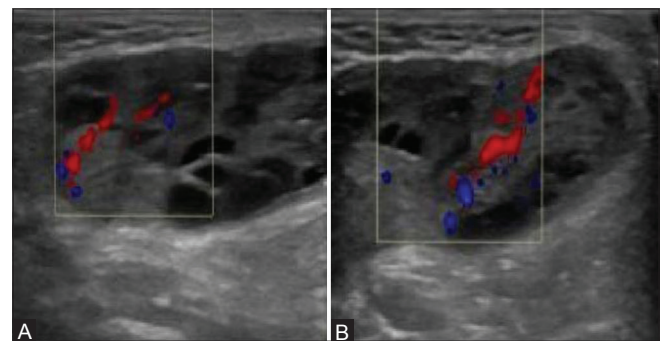
On presentation, the infant was anxious and in a steady state of intense crying. On physical examination, a tender mass was palpated in the left inguinoscrotal region with inflamed reddish scrotal skin. Ultrasonography examination showed dilated fluid-filled bowel loop in inguinoscrotal region [Figure 3] along with reduced peristaltic activity with mild amount of fluid in the herniated sac cavity around bowel and anterior laterally pushed left testis; the findings were suggestive of incarcerated hernia as peristaltic activity present in herniated loop was sufficient to rule out strangulation. Echogenic mesentery was seen attached to the dilated loop at superficial inguinal ring region, which showed vascularity on color Doppler, further confirming viability of loop. Emergency laprotomy was done, herniated loop was replaced in the abdomen along with high ligation of herniated sac.

#### Case 3

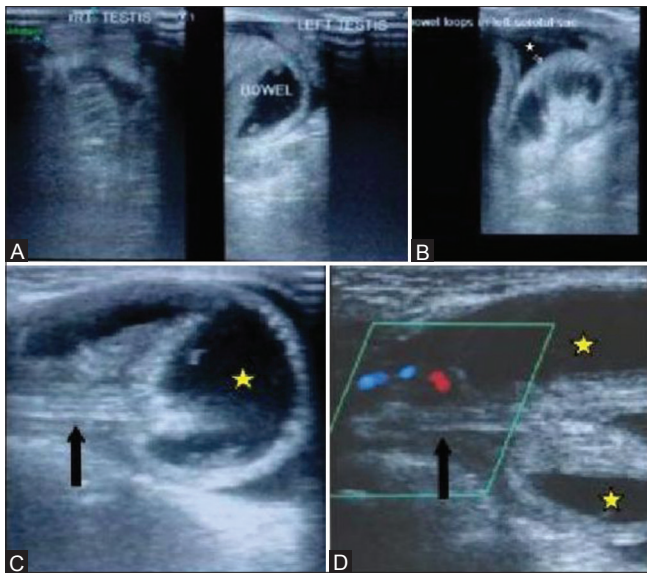
A 5-day-old female newborn, who was born after 39 weeks of gestational with a birth weight of 2700 g, was brought to the pediatric OPD following the discovery of an asymptomatic lump in her right groin by her mother. On physical examination, a nontender mass was palpated in the right inguinal region extending up to the upper aspect of right valva just above the labium majora. She was advised ultrasonography for further evaluation. On B-mode ultrasound, an 8 mm wide fascial defect and a herniation of well-defined oval structure contain internal small cysts, which was about 15 mm × 9 mm in diameter, with a attached pedicle. Thus, this was diagnosed as the right ovary herniated through the inguinal canal [Figure 4]. At Colour Doppler, vascular signals with arterial wave form were obtained at pedicle region, thus indicating viability. On the same evening, the swelling was readily reduced with gentle pressure.

## Discussion

The processus vaginalis arises as an evagination of parietal peritoneum around the sixth month after conception. Depending on gender, the processus vaginalis is accompanied by testis or round ligament of the uterus and passes through



**Figure 2 (A and B):** Color Doppler images show normal arterial flow right (A) and left side ovary (B) present in the herniated sac at left labial region

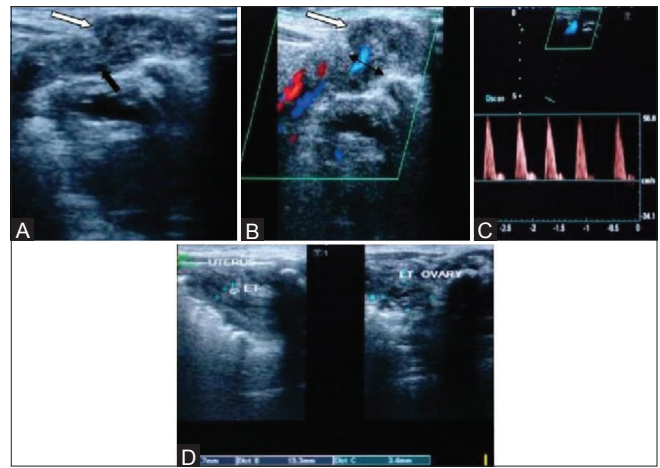


**Figure 3 (A-D):** (A-D) Ultrasound of left inguinoscrotal region with high frequency transducer in 1-month-old male infant showing left inguinal hernia extending into left scrotum containing bowel loop with feature indicative of incarceration. (A) Right side ultrasound image shows normally placed right testis in right scrotal sac, left side ultrasound image shows dilated fluid fill bowel loop in left scrotal sac, displacing left testis anteriorly. (B) Ultrasound image shows dilated fluid filled small bowel loop (arrow) with mild fluid around the bowel (white star) suggestive of incarceration of herniated bowel. (C, D) Ultrasound image at higher level in scrotum show bowel loop (yellow star) along with its echogenic mesentery (black arrow), normal vascularity in mesentery sufficient to rule out ischemia of herniated bowel

the inguinal canal toward the scrotum or labium major.<sup>[8]</sup> The female counterpart of the processus vaginalis known as the canal of Nuck is relatively small and commonly disappears by 8 months of gestation.<sup>[9]</sup> Hence, premature delivery before the closure of this canal increasing the risk of the development of an inguinal hernia.<sup>[10]</sup>

Inguinal hernias are more common on the right side, occurring in approximately 60% of the cases, with 30% on the left side, and 10% bilateral.<sup>[11]</sup> Inguinal hernias may contain the intestines, omentum, fluid testes, ovaries, fallopian tubes, uterus, and urinary bladder.<sup>[12]</sup> Incarceration is an important complication of inguinal hernias in the pediatric age group and occurs with a frequency of 31%.<sup>[13]</sup> The bowel, ovaries, or fallopian tubes are the organs that are most commonly incarcerated. Although some hernias regress spontaneously, this is less likely to occur if it contains the ovary, and in comparison to a bowel containing hernia, the risk of incarceration is greatly increased. An incarcerated hernia may progress rapidly to strangulation, a situation with vascular compromise and infarction of the incarcerated contents. Incarcerated ovaries are also susceptible for torsion in female infant.

Uncomplicated inguinal hernias usually present with a history of intermittent swelling in the inguinal region, which in males may extend to the scrotum, and in females, may



**Figure 4 (A-D):** (A-D) Ultrasound with high frequency transducer probe in 5-day-old female neonate for asymptomatic right inguinal region swelling show viable right ovary with attached ovarian ligament. (A) Transverse ultrasound scan at right inguinal region swelling show oval shape hypoechoic structure (white arrow) contain small peripheral follicles suggest appearance of ovary herniated into right inguinal canal, ovary attach to hypoechoic pedicle (black arrow). (B, C) Color Doppler study shows prominent vessels with arterial flow with PSV approximately 50–60 cm/s in ovarian pedicle, having normal spectral wave form. (D) Ultrasound scan in pelvic region show uterus with visible echogenic endometrium and left ovary in normal position

extend to the labia majora. The swelling is usually nontender and readily reducible with gentle pressure. An incarcerated hernia usually presents as firm, tender, nonreducible swelling in the inguinal region (possibly extending to the scrotum and labia majora).

Ultrasonography is an easily applied and highly accurate imaging modality. With a high-frequency transducer and color Doppler, ultrasound is the imaging modality of choice for characterization of herniated structure and viability. Ultrasound may be indicated to differentiate an inguinoscrotal hernia from other conditions as well as to investigate contralateral involvement.<sup>[14]</sup> Ultrasound examination should include both inguinal canals because a clinically inapparent contralateral hernia can be found in 88% of cases.<sup>[15]</sup>

Uterus appears as a hypoechoic structure with echogenic internal endometrium. Ultrasonography finding of solid masses containing multiple cysts of varying size is a useful sign for the identification of ovary containing hernias. In case of ovarian torsion, there is an enlarged, mass-like ovary with heterogeneous echogenicity that contains multiple peripheral cysts and no blood flow within the ovary.<sup>[16]</sup> Colour Doppler use for further conformation which permits the examiner to evaluate the vascular structures at the ovarian pedicle and determine if the herniated and torsioned ovary tissue has suffered ischemia or not.<sup>[13]</sup>

On ultrasound, intestinal loops within the scrotum appear as tubular structures containing hyperechoic air bubbles



or fluid. Peristalsis of bowel loops is easily detected because of the movement of gas bubbles. Signs of an incarcerated hernia having bowel loops as content are thickening of the wall of the herniated bowel loop, fluid in the herniated bowel loop, free fluid in the hernia sac, and intraabdominal bowel dilatation. Criteria for strangulation have been described and include the presence of a dilated akinetic loop, the presence of peristaltic activity in bowel proximal to the loop, and rapid accumulation of peritoneal fluid after the onset of obstruction.<sup>[17]</sup> The presence of peristaltic activity in herniated bowel has been considered to be evidence against strangulation.<sup>[18]</sup> Late presenting strangulation can have reduced or absent color flow on color Doppler and may require bowel resection. It is important to note that absent color Doppler flow is a late finding of bowel strangulation.<sup>[19]</sup>

Children with Complete androgen insensitivity syndrome previously called the testicular feminization syndrome have female genitalia and endocrine function, but intraabdominal testis, despite ovary. So as concerning this entity approximately 1.6% of the children presenting with inguinal hernia, there may be testicles in herniated sac especially if condition is bilateral.<sup>[20]</sup>

## Conclusion

We suggest that ultrasound should be performed routinely in those with an inguinal hernia containing an asymptomatic/symptomatic palpable mass because early surgical intervention is necessary to prevent the damage of herniated organs and because unexpected reproductive structures may be involved in the hernia sac.

## Financial support and sponsorship

Nil.

## Conflicts of interest

There are no conflicts of interest.

## References

1. Inguinal hernias and hydroceles in infancy and childhood: A consensus statement of the Canadian Association of Paediatric Surgeons. *Paediatr Child Health* 2000;5:461-2.
2. Laing FC1, Townsend BA, Rodriguez JR. Ovarycontaining hernia in a premature infant: Sonographic diagnosis. *J Ultrasound Med* 2007;26:985-7.
3. Cascini V, Lisi G, Renzo DD, Pappalepore N, Chiesa PL. Irreducible indirect inguinal hernia containing uterus and bilateral adnexa in a premature female infant: Report of an exceptional case and review of the literature. *J Pediatr Surg* 2013;48:e17e19.
4. Oudesluys-Murphy AM, Teng HT, Boxma H. Spontaneous regression of clinical inguinal hernias in preterm female infants. *J Pediatr Surg* 2000;35:1220-1.
5. Goldstein IR, Potts WJ. Inguinalherniainfemaleinfants and children. *Ann Surg* 1958;148:819-22.
6. Boley SJ, Cahn D, Lauer T, Weinberg G, Kleinhaus S. Their reducible ovary: Atrue emergency. *J Pediatr Surg* vol. 26, no. 9, pp. 1035-1038,1991.
7. Kapur P, Caty MG, Glick PL. Pediatricherniasand hydroceles. *Pediatr Clin North Am* 1998;45:773-89.
8. Khanna PC, Ponsky T, Zagol B. Sonographic appearance of canal of Nuck hydrocele. *Pediatr Radiol* 2007;37:603e6.
9. Shadbolt CL, Heinze SB, Dietrich RB. Imaging of groin masses: Inguinal anatomy and pathologic conditions revisited. *Radiographics* 2001;21:261-71.
10. Merriman TE, Auld AW. Ovarian torsion in inguinal hernias. *Pediatr Surg Int* 2000;16:383-5.
11. Ziegler MM. Diagnosis of inguinal hernia and hydrocele. *Pediatric Rev* 1994;15:286-8.
12. Ming Y, Luo C, Chao H.C, Chu S.M. Inguinal hernia containing uterus and uterine adnexa in female infants: Report of two cases. *Pediatr. Neonatol.* 2011;52:103-05.
13. Shalev J, Mashiach R, Bar-Hava I, Girtler O, Bar J, Dicker D, *et al.* Subtorsion of the ovary: Sonographic features and clinical management. *J Ultrasound Med* 2001;20:849-54.
14. Aso C, Enríquez G, Fité M, Torán N, Piró C, Piqueras J, *et al.* Gray-scale and color Doppler sonography of scrotal disorders in children: An update. *Radiographics* 2005;25:1197-214.
15. Moss RL, Hatch EI. Inguinal hernia repair in early infancy. *Am J Surg* 1991;161:596-9.
16. Aydin R, Polat AV, Ozaydin I, Aydin G. Gray-scale and color Doppler ultrasound imaging findings of an ovarian inguinal hernia and torsion of the herniated ovary: A case report. *Pediatr Emerg Care* 2013;29:364-5.
17. Ogata M, Mateer JR, Condon RE. Prospective evaluation of abdominal sonography for the diagnosis of bowel obstruction. *Ann Surg* 1996;223:237-41.
18. Blaivas M. Ultrasound-guided reduction of a Spigelian hernia in a difficult case: An unusual use of bedside emergency ultrasonography. *Am J Emerg Med* 2002;20:59-61.
19. Ogata M, Imai S, Hosotani R, Aoyama H, Hayashi M, Ishikawa T. Abdominal ultrasonography for the diagnosis of strangulation in small bowel obstruction. *Br J Surg* 1994;81:421-4.
20. Siddaiah B. XY female with complete androgen insensitivity syndrome with bilateral inguinal hernia. *J Indian Med Assoc* 2013;111:480-1.