Article published online: 2021-07-27

Percutaneous transhepatic techniques for management of biliary anastomotic strictures in living donor liver transplant recipients

Chinmay B Kulkarni, Nirmal K Prabhu, Nazar P Kader, Ramiah Rajeshkannan, Sreekumar K Pullara, Srikanth Moorthy

Department of Radiology, Amrita Institute of Medical Sciences, Ponekkara, Kochi, Kerala, India

Correspondence: Dr. Chinmay B Kulkarni, Department of Radiology, Amrita Institute of Medical Sciences and Research Centre, Amrita Lane, Ponekkra, Elamakkara, Kochi - 682 041, Kerala, India. E-mail: chidoc@rediffmail.com

Abstract

Aim: To retrospectively analyze the percutaneous transhepatic techniques and their outcome in the management of biliary strictures in living donor liver transplant (LDLT) recipients. **Materials and Methods:** We retrieved the hospital records of 400 LDLT recipients between 2007 and 2015 and identified 45 patients with biliary strictures. Among them, 17 patients (37.8%) (Male: female = 13:4; mean age, 36.1 ± 17.5 years) treated by various percutaneous transhepatic biliary techniques alone or in combination with endoscopic retrograde cholangiopancreatography (ERCP) were included in the study. The technical and clinical success of the percutaneous management was analyzed. **Results:** Anastomotic strictures associated with leak were found in 12/17 patients (70.6%). Ten out of 12 (83.3%) patients associated with leak had more than one duct-duct anastomoses (range, 2–3). The average duration of onset of stricture in patients with biliary leak was 3.97 ± 2.68 months and in patients with only strictures it was 14.03 ± 13.9 months. In 6 patients, endoscopic-guided plastic stents were placed using rendezvous technique, plastic stent was placed from a percutaneous approach in 1 patient, metallic stents were used in 2 patients, cholangioplasty was performed in 1 patient, N-butyl- 2-cyanoacrylate embolization was done in 1 child with biliary-pleural fistula, internal-external drain was placed in 1 patient, and only external drain was placed in 5 patients. Technical success was achieved in 12/17 (70.6%) and clinical success was achieved in 13/17 (76.5%) of the patients. Posttreatment mean time of follow-up was 19.4 ± 13.7 months. Five patients (29.4%) died (two acute rejections, one metabolic acidosis, and two sepsis). **Conclusions:** Percutaneous biliary techniques are effective treatment options with good outcome in LDLT patients with biliary complications.

Key words: Biliary tract; cholangiopancreatography; endoscopic retrograde; liver transplantation; stricture

Introduction

Living donor liver transplants (LDLT) are associated with a higher rate of biliary complications than deceased donor liver transplants (DDLT).[1-3] Biliary leaks and subsequent biliary strictures have been reported to occur in up to 30% of the patients undergoing LDLT. Biliary strictures are associated

Access this article online	
Quick Response Code:	Website: www.ijri.org
	DOI: 10.4103/0971-3026.202950

Cite this article as: Kulkarni CB, Prabhu NK, Kader NP, Rajeshkannan R, Pullara SK, Moorthy S. Percutaneous transhepatic techniques for management of biliary anastomotic strictures in living donor liver transplant recipients. Indian J Radiol Imaging 2017;27:92-9.

with a high morbidity and mortality if not managed appropriately.[1-5] Biliary strictures can be anastomotic or non-anastomotic. Management of biliary complications involves a combination of endoscopic, radiological, and surgical procedures.[6] Endoscopic techniques are the first line of treatment with success rates of 70–100% in anastomotic strictures and 50–75% in non-anastomotic strictures. However, the success rate decreases in LDLT, and is only 60–75% in anastomotic strictures and 25–33% in non-anastomotic strictures.[7] Percutaneous techniques with a success rate of 50–75% are generally considered to be the second line of management and play a key role in LDLT patients where the success rate of endoscopic techniques is less.[7] We retrospectively analyzed the techniques and outcome of percutaneous transhepatic management of biliary anastomotic strictures in LDLT patients.

Materials and Methods

Institutional review board approval was taken for this retrospective analysis. We retrieved the hospital records of 400 LDLT recipients between 2007 and 2015 and identified 45 patients (11.3%) with biliary strictures with or without leaks. Among them 17 patients (37.8%) (Male:female = 13:4; mean age, 36.1 ± 17.5 years; range, 10–67 years) treated by various percutaneous transhepatic biliary techniques alone or in combination with endoscopic retrograde cholangiopancreatography (ERCP) were included in the study [Table 1]. Biliary strictures were suspected when there were clinical findings (fever, cholangitis, sepsis), biliary stain in the drainage tube, increased liver biochemical parameters (alkaline phosphatase, total bilirubin), or imaging evidence of biliary obstruction. Clinical records and images were retrieved from electronic medical record and picture archiving and communication system. The patients managed by ERCP alone were excluded [Figure 1]. The technical and clinical success of the percutaneous management was analyzed.

Technique

Broad spectrum intravenous antibiotics (cefoperazone sodium 1 g) were administered to all patients 2–3 hours before the procedure. Procedures were performed under conscious sedation (2.5–5 mg of midazolam and 50–100 micrograms (mcg) of fentanyl, administered intravenously). In children, general anesthesia was employed. Approximately 10–20 mL of 2% lidocaine was administered subcutaneously to achieve local anesthesia. The vital signs of the patient were monitored during the procedure. The bile duct was punctured using a 22 G Chiba needle (Cook Inc., Bloomington, IN, USA) under ultrasound or fluoroscopic guidance. A cholangiogram was performed to study the level and nature of the obstruction/leak. A 0.035-inch guidewire was placed in the system using a Neff-set (Cook Inc, Bloomington, IN, USA.). The crossing of the stricture was then attempted using a combination of 5 Fr Kumpe catheter (Cook Inc., Bloomington, IN, USA) and 0.035-inch Terumo hydrophilic guidewire (Terumo, Tokyo, Japan). If the stricture could not be crossed, an external drainage catheter was placed. After crossing the stricture, if endoscopy was possible, a plastic stent was placed using rendezvous technique. When endoscopy was not feasible, further treatment was completed percutaneously either by dilating the strictures with low profile angioplasty balloons (6 mm to 8 mm size) in multiple sittings, placing the metallic stents (8 mm × 60 mm and 8 mm × 37 mm size) across the stricture if balloon dilatation fails, or by simply placing the internal-external drainage catheter (8.5Fr, 10.2Fr size) across the stricture [Figure 2]. In

Table 1: Clinical presentation and management of the anastomotic strictures

Age (years)	Sex	Transplant lobe	Presentation	Type of anastomosis	Number of anastomosis	Number of strictures	Treatment
36	Male	Right	Stricture + leak	Duct-Duct	2	1	Covered metallic stent
32	Male	Right	Stricture + leak	Duct-Duct	2	1	Rendezvous technique
42	Female	Right	Stricture + leak	Duct-Duct	2	2	PTBD-external drainage[anterior and posterior]
40	Male	Right	Stricture + leak	Duct-Duct	2	1	PTBD-external drainage
10	Male	Left	Stricture + leak	Duct-Duct	1	1	PTBD with histoacryl glue embolization
53	Male	Right	Stricture + leak	Duct-Duct	2	2	PTBD-external drainage[anterior&posterior]
67	Male	Right	Stricture + leak	Duct-Duct	2	2	Rendezvous technique
10.5	Male	Left	Stricture	Hepatico-jejunostomy	1	1	PBBD
51	Male	Right	Stricture + leak	Duct-Duct	2	1	PTBD-external drainage
26	Female	Right	Stricture	Duct-Duct	2	2	Rendezvous technique
35	Female	Right	Stricture + leak	Duct-Duct	2	1	Rendezvous technique
44	Female	Right	Stricture	Duct-Duct	3	2	Covered metallic stent
44	Male	Right	Stricture	Duct-Duct	1	1	Rendezvous technique
59	Male	Right	Stricture + leak	Duct-Duct	2	1	Rendezvous technique
18	Male	Right	Stricture + leak	Duct-Duct	1	1	Percutaneous plastic stent
11	Male	Left	Stricture + leak	Duct-Duct	2	1	PTBD-external drainage
15	Male	Left	Stricture	Duct-Duct	1	1	PTBD Internal-external drainage

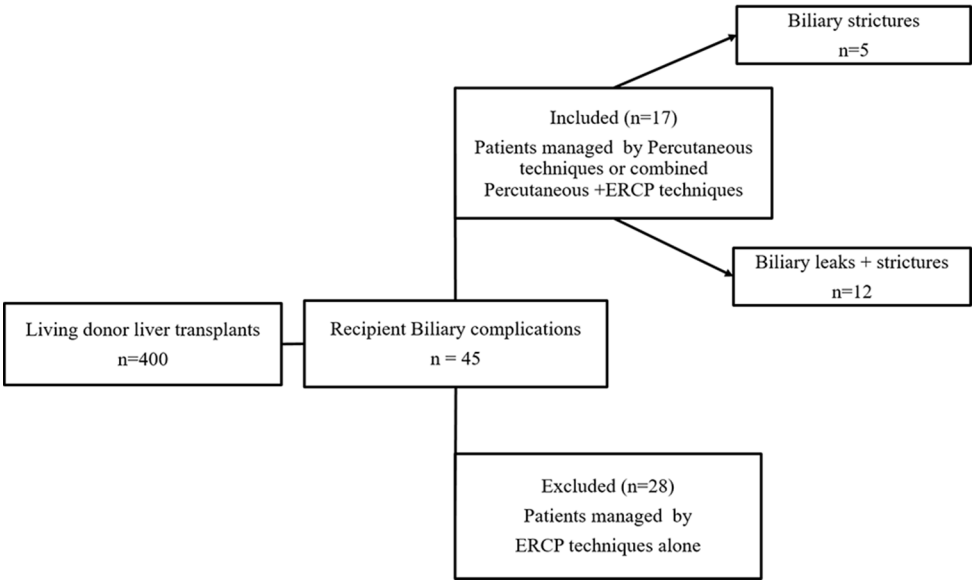

Figure 1: Diagram showing included and excluded patients in the study

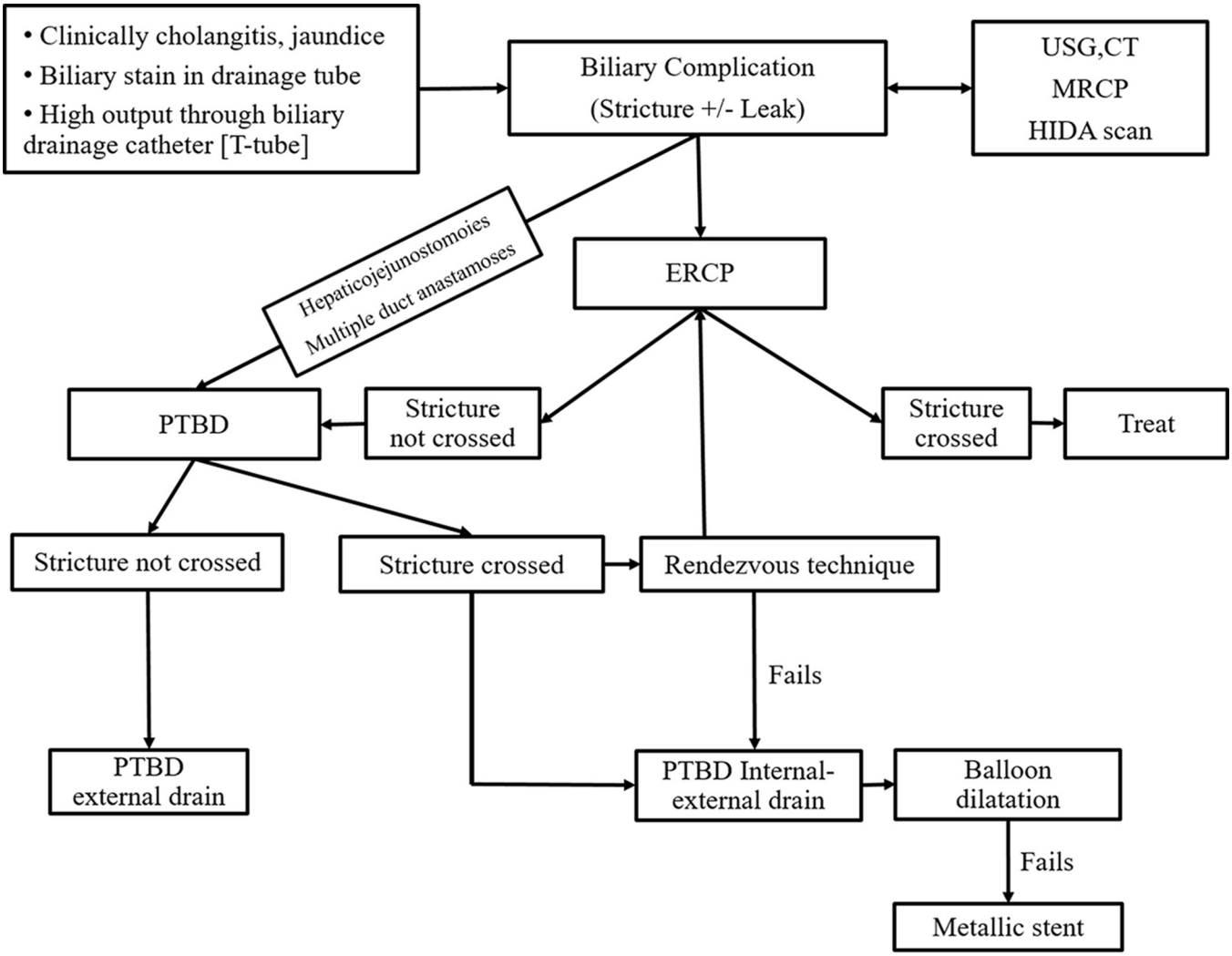

Figure 2: Diagram showing approach to the management of biliary strictures in LDLT recipients

a child with biliary pleural fistula, the fistula was successfully embolized with N-butyl- 2-cyanoacrylate (NBCA) from a percutaneous approach. Complications were classified as major and minor according to the guidelines of the Society of Interventional Radiology Standards of Practice Committee.[8]

Study endpoints terms

Technical success was defined as restoration of normal antegrade bile flow across the stricture and resolution of the stricture on cholangiogram. Technical failure was defined as not able to cross the stricture. Unsatisfactory dilation was defined as residual narrowing or poor/absent flow after dilatation requiring further dilatation sessions in the same treatment period to achieve technical success. A dilatation session is the dilatation of strictures, performed in a single radiological intervention. One treatment can consist of multiple dilatation sessions. One or more dilatation were performed on the initial admission, and thereafter, on follow-up, the patient was admitted again for further dilatation sessions, if needed. The duration of treatment is the time period between the first percutaneous access of the bile duct to complete dilatation sessions, successful metallic stent placement across the stricture, and removal of PTBD drainage catheters. Clinical success was defined by decrease in preprocedural elevated total bilirubin and alkaline phosphatase (ALP) levels to normal values after the intervention, as well as the absence of cholangitis in the first month after treatment. The total bilirubin and ALP levels were measured a day before the procedure and 4–6 weeks after the completion of treatment. Follow-up imaging was done with either a contrast enhanced computed tomography (CT) or magnetic resonance cholangiopancreatography (MRCP), every 6 months or earlier if symptoms recurred.

Statistical analysis

Statistical analysis was performed using the Statistical Package for the Social Sciences version 20.0 software (IBM Co., Armonk, NY, USA). The data was analyzed using descriptive statistical methods. Comparison was done using Mann–Whitney U test. Differences were considered to be significant if $P < 0.05$.

Results

All patients presented with the clinical features suggestive of cholangitis. The average white blood cell (WBC) count before the start of treatment was $11.9 \pm 3.1 \times 10^9$ per liter. Sixteen patients had duct-duct anastomotic strictures and one patient had hepatico-jejunostomy stricture. Twelve out of the 16 (75%) patients with duct-duct anastomoses had more than one anastomoses. Strictures associated with leak were found in 12/17 patients (70.6%). Ten out of 12 (83.3%) patients associated with leak had more than one duct-duct anastomoses (range, 2–3). The average duration of onset of stricture in patients with biliary leak was 3.97 ± 2.68 months (1.3–8 months) and in patients with only strictures was 14.03 ± 13.9 months (4.4–34 months). Seven out of 12 patients (58.3%) initially presented with a leak, and average duration before detection of stricture in these patients was 2.2 ± 1.5 months. In our series, 3 patients had hepatic artery occlusion in the immediate postoperative period and underwent laparotomy and revascularization. Stricture in these patients manifested early at 1.93 ± 0.60 months (1.3–2.5 months). In 6 patients endoscopic-guided plastic stents were placed using rendezvous technique. In 1 patient, plastic stent was placed from a percutaneous approach after crossing the stricture. In 1 patient who underwent LDLT for multifocal hepatocellular carcinoma (HCC) had recurrent HCC in the transplanted liver. He presented with stricture and a completely disrupted bile duct, and hence a covered metallic stent was placed. Post stenting, the patient remained asymptomatic for 20 months. In another patient with poor response to balloon dilatation, two self-expandable metallic stents (SEMS) were placed. Average time before stenting was 3 ± 2.8 months and primary patency was 12 ± 11.3 months. One patient with hepatico-jejunostomy stricture was managed successfully with two sessions of balloon dilatations alone. In a child with bronchopleural fistula, the percutaneous approach was successfully used to embolize the fistula with NBCA. One patient was managed by only internal-external drain. In 5 patients in whom we failed to cross the lesion, only external drain was placed. Four of these patients showed good clinical success. One patient expired 1.5 months later due to sepsis. One of the patients who underwent the PTBD external drainage for 3.5 months and in the follow up period of 60 months remained asymptomatic. In 2 patients, follow up of 6 and 8 months, respectively, was uneventful. One patient underwent hepatico-jejunostomy after 4 months. The average number of attempts to cross the stricture in 5 patients in whom we failed to cross the lesion 3 ± 1 (range, 2–4) and in the remaining 11 patients in whom we successfully crossed the stricture, average number of attempts was 2 ± 1 (range, 1–3). The mean duration of treatment in patients with only stricture was 3.62 ± 2.05 months, and in patients with strictures associated with leaks it was 3.23 ± 2.06 months. Technical success was achieved in 12/17 (70.6%), and clinical success was achieved in 13/17 (76.5%) of the patients. The average pretreatment and posttreatment total bilirubin was 19.7 ± 10.96 mg/dl (3.2–33.6 mg/dl) and 1.21 ± 0.71 mg/dl (0.5–3.2 mg/dl), respectively, and pre-treatment and post-treatment alkaline phosphatase was 533.34 ± 204.86 IU/L (210–977.2 IU/L) and 113.12 ± 22.37 IU/L (77.2–152 IU/L), respectively. Statistically significant decrease in bilirubin ($P < 0.002$) and alkaline phosphatase ($P = 0.012$) was seen in the posttreatment period. Posttreatment mean duration of follow-up was 19.4 ± 13.7 months. Five patients (29.4%) died (two due to acute rejections, one metabolic acidosis, and two due to sepsis). Among the 5, 3 were treated by rendezvous technique/ERCP stent, 1 was treated with covered metallic

stent, and 1 by only PTBD external drainage. No major procedure related complications were encountered.

Discussion

The higher incidence of stricture in LDLT as compared to DDLT can be attributed to injury to bile ducts while resecting the right or left lobe of the liver, smaller diameter of intrahepatic bile ducts in live donor grafts, and frequent need to perform multiple ductal anastomosis.[9-11] Managing strictures in LDLT endoscopically is challenging because multiple duct anastomosis can lead to multiple strictures and intrahepatic strictures, and smaller duct size poses difficulties in accessing and crossing the stricture. Moreover, accessing the hepatico-jejunostomy site stricture by endoscopy is technically difficult due to altered anatomy. Percutaneous transhepatic interventional techniques play an important role in overcoming these challenges. In this series, we studied the outcomes of various percutaneous techniques used in managing these patients.

Biliary strictures in the posttransplant scenario can be anastomotic or non-anastomotic. Anastomotic strictures are short segment fibrotic strictures at the anastomotic site. Early anastomotic strictures may be due to the small diameter of bile ducts, size mismatch between donor and recipient bile ducts, improper surgical technique, excessive cauterization, whereas late onset anastomotic strictures are usually due to ischemic injury and subsequent healing.[12,13] Non-anastomotic strictures are usually multiple, longer, and can involve intra and extrahepatic bile ducts. Non-anastomotic strictures are due to ischemic injury consequent to hepatic artery thrombosis or due to prolonged warm ischemia. Non-anastomotic strictures can occur due to immunological causes such as chronic rejection and primary sclerosing cholangitis.[14,15] In our study, 16/17 (94.11%) were duct-duct anastomotic strictures and 1 patient had hepatico-jejunostomy stricture. The onset of stricture was significantly early (3.97 ± 2.68 months; range: 1.3–8 months) when associated with leak as compared to without leak (14.03 ± 13.9 months; range: 4.4–34 months). Biliary leak induces more inflammatory response around the anastomotic site leading to early onset of stricture formation. Hepatic artery occlusion is usually associated with early onset of strictures due to ischemic injury to the bile duct. In our series also, the onset of stricture in 3 patients who had hepatic artery occlusion was early 1.93 ± 0.60 months (1.3–2.5 months). Another factor that predicts the anastomotic leak rate is the number of duct anastomosis. As expected, 10/12 (83.3%) patients with leak in our study had more than one duct-duct anastomosis (range: 2–3).

Percutaneous biliary balloon dilatation (PBBD) is an effective technique of managing benign biliary strictures.[16] After crossing, the stricture is dilated with increasing size of balloon in multiple sittings. One child suffering from biliary atresia who had undergone left lobe LDLT had developed hepatico-jejunostomy stricture 34 months later. The stricture was treated with graded balloon dilatation with 6 and 8 mm balloons in two sittings over a period of 1.5 months [Figure 3]. The follow-up period of 32 months in this patient was uneventful. PBBD is useful in patients who have only strictures and may not be useful if associated with leak.

Anastomotic leaks are usually managed by biliary diversion techniques such as placing internal-external drainage catheters percutaneously across the leak site or by placing plastic stents endoscopically. However if the leak persists because of severe ductal injury or persistent fistulas they may require major open surgery which is associated high morbidity.[17,18] Alternatively, various embolizing agents such as fibrin, ethanol, and coils have been used to occlude the leak or fistula.[19-22] Recently, NBCA has been used to manage the biliary leak or fistula. NBCA is a low viscosity liquid embolizing agent that immediately polymerizes and solidifies upon contact with body fluids.[23] It provides a permanent biliary chemical embolization. Gorich *et al*. have shown the effectiveness of percutaneous embolization of bile duct fistulas with NBCA in 4 patients.[24] NBCA is injected through a microcatheter at the leak site. Before injecting it is important to ensure the correct concentration of NBCA. At lower concentrations there is a risk of spillage into normal biliary radicals, and at higher concentration there is a risk of premature cast formation. Because of the high risk of nontarget embolization, the use of these embolizing agents should be limited to the persisting leaks from the peripheral small ducts. One of our patients with stricture and leak developed a biliopleural fistula. He was managed by percutaneous biliary drainage and ERCP stenting for 4 months. However,

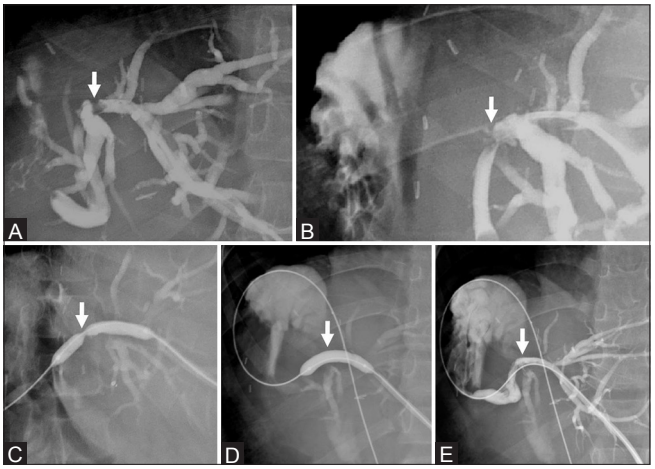

Figure 3 (A-E): A 10.5-year-old male post kasai procedure for biliary atresia underwent LDLT (Left lobe) and hepatico-jejunostomy. He developed anastomotic site stricture after 34 months (A, arrow). Stricture crossed (B, arrow) and graded balloon dilatation done using 6 mm and 8 mm angioplasty balloon (two sessions) (C, D, arrows). Check cholangiogram 2 weeks after the last dilatation shows no residual narrowing and free flow of contrast across anastomosis (E, arrow)

the fistula persisted and was finally treated by injecting NBCA through left duct approach at the fistula site. The follow-up period of 78 months showed no recurrent fistula or symptoms [Figure 4].

There is limited information available regarding the use of metallic stents in treating post transplant biliary strictures and most data suggests use of retrievable covered stent. A recent study using retrievable covered stent showed a success rate of 60–70% for anastomotic strictures in DDLT.[25] Another study showed that retrievable covered stent has patency rate of 100% and plastic stents has patency rate of 80% in the treatment of anastomotic strictures after DDLT [Figure 5]. The main limitations of using metallic stents are stent migration, and early reocclusion.[26] In our series, we used covered metallic stents in 2 patients. Clinical success was achieved in both the patients. No stent migration or recurrent strictures were seen in either patient. One of the patient had two separate anastomosis of anterior and posterior ducts and developed strictures at both the anastomotic sites. Initially they were treated with graded balloon dilatation for two sessions with internal-external drainage catheter across the strictures. However, in view of residual narrowing, two SEMS were deployed across both the strictures [Figure 6]. Another patient had recurrent HCC in the transplanted liver along with stricture and complete duct disruption. Covered stent was placed across the stricture/disrupted duct. One of the problems in patients requiring repeated interventions is the onset and progression of cirrhosis secondary to chronic cholestasis. Percutaneous approach in the presence of cirrhosis and periductal fibrosis can be challenging, and metallic stents, despite their limited patency, may be the only viable option in these patients. However, the nonretrievable metallic stents should be used as a last resort when there are no other treatment options.

LDLT patients may need to undergo multiple duct anastomosis which makes accessibility by ERCP difficult. The other scenarios in which ERCP usually fails is in patients with hepatico-jejunostomies and severe strictures/complete duct disruption associated with leaks. ERCP failed to cross the strictures in all patients in our series. However, in 6 patients in whom ERCP initially failed were managed by rendezvous technique. Percutaneous techniques are complimentary to ERCP.

In 5 patients, strictures could not be crossed either by ERCP or percutaneously, and hence only PTBD-external drainage was performed in these patients [Figure 7]. Though PTBD-external drainage was considered as technical failure for the sake of statistical analysis, it is an important biliary diversion technique. Four out of 5 patients improved clinically after PTBD-external drainage. Though crossing the lesion is an important step, draining the system externally can be lifesaving in critically ill patients with failed ERCP. Biliary diversion decreases the volume of the bile flow across the leak site, decreasing the inflammatory process and allowing healing.

In our study, technical success was achieved in 12/17 (70.6%) patients and clinical success was achieved in 13/17 (76.5%).

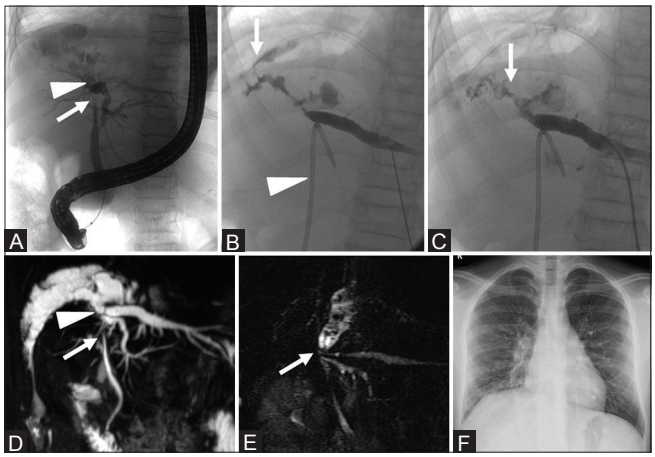

Figure 4 (A-F): A 10-year-old male with Wilsons disease underwent LDLT (Left lobe), developed anastamotic site stricture with biliopleural fistula after 7.5 months. Initially stricture (A, D arrow) with biliopleural fistula (A, D arrowhead) was treated with ERCP plastic stent (B, arrowhead). However, leak persisted (B, arrow). NBCA was injected percutaneously into fistula (C, arrow) through left duct approach. Follow-up MRCP 48 month later shows significant decrease in stricture (E, arrow). Chest radiograph taken 78 months later shows no significant changes in the lungs (F)

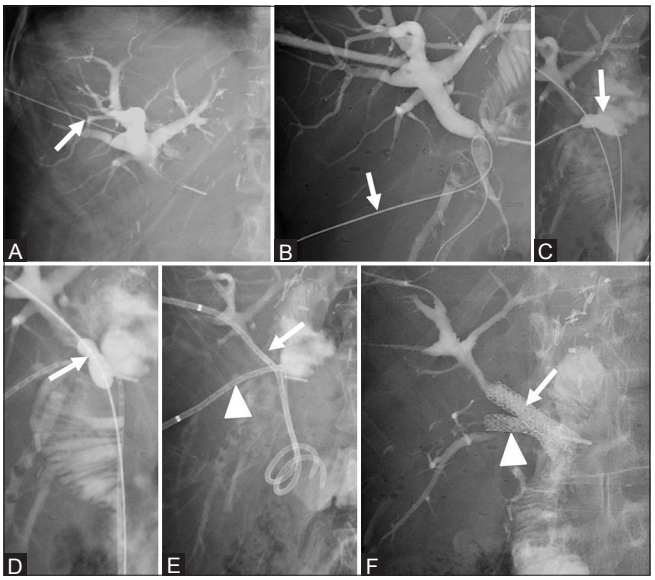

Figure 5 (A-F): A 44-year-old female with fulminant hepatic failure underwent LDLT (right lobe), developed stricture at two anastomotic sites after 13 months. Anterior (A, arrow) and posterior sectoral ducts (B, arrow) separately punctured. The strictures crossed and graded dilatation done using 4 mm and 7 mm balloons (C, posterior duct stricture; D, arrow anterior duct stricture) and internal-external drainage catheters placed (E, arrow, arrowhead). One month later covered metallic were deployed in both anterior (F, arrow) and posterior duct (F, arrowhead) anastomotic strictures

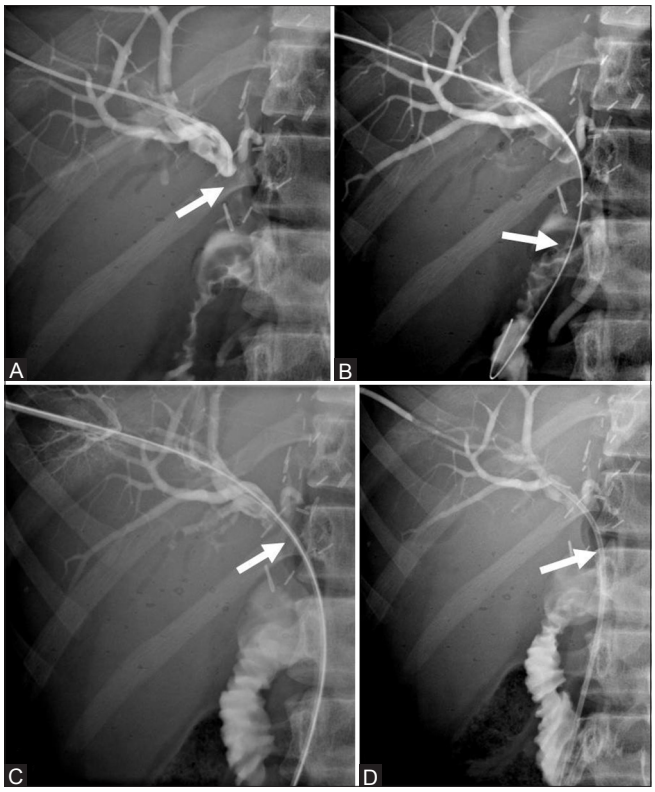

Figure 6 (A-D): A 17-year-old male with Fulminant hepatic failure (Yellow phosphorus poisoning) underwent LDLT (right lobe). He developed anastomotic site stricture with leak at 8 months (A, arrow). Initial attempts to cross the stricture by ERCP failed. Stricture crossed (B, C, arrow) and plastic stent deployed across the stricture site (D, arrow) percutaneously

The overall incidence of strictures and technical success of percutaneous management of these strictures is comparable to other published studies.[27-32] Our study shows the importance of the various percutaneous techniques available as the rescue therapy for the patients with failed ERCP. One of the most critical and difficult step in the management of strictures is to cross the lesion. We looked at the average number of attempts required to cross the stricture. In 5 patients, we failed to cross the lesion and average number of attempts was 3 ± 1 (range, 2–4). In the remaining 11 patients in whom we successfully crossed the stricture, average number of attempts was 2 ± 1 (range, 1–3). Though these numbers are not the true reflections of the effort and time spent on the patients, they give us a fair idea of the technical difficulty.

Posttreatment mean time of follow-up was 19.4 ± 13.7 months and was available in all patients. In our series, only two patients died due to cholangitis and sepsis. Biliary complications if not appropriately managed are associated with high rate of morbidity and mortality. Surgery is not the first line of treatment for patients with bile leaks and biliary stricture because mostly these patients are sick and surgery can have further high complications requiring general anesthesia and intensive postoperative care. Early detection

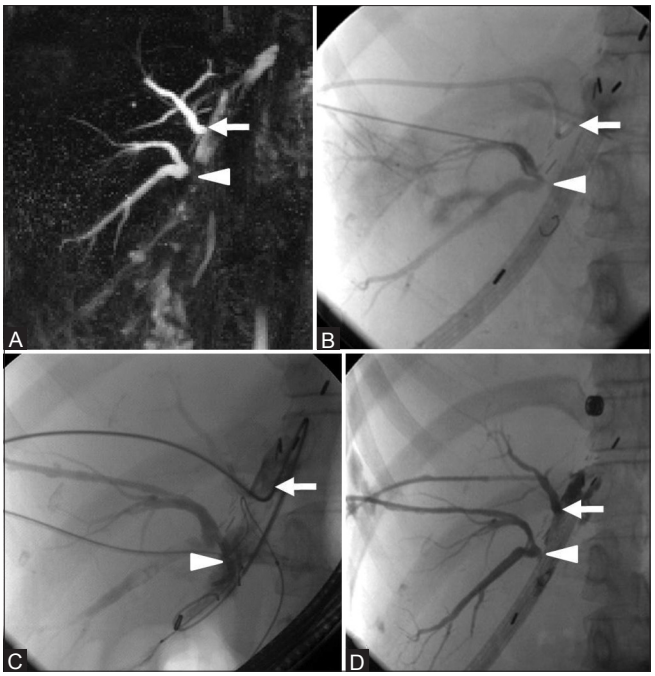

Figure 7 (A-D): A 42-year-old female with autoimmune hepatitis underwent LDLT (right lobe) with two duct-duct anastomosis. Patient developed stricture with leak at anastomotic sites after 3.2 months (A, arrow, arrowhead). Repeated attempts to cross the stricture by the percutaneous approach (B, arrow, arrowhead) and ERCP (C, arrow, arrowhead) failed. External drains placed in both systems (D, arrow, arrowhead). Patient probably developed spontaneous bilioenteric fistulae. Follow-up for 60 months was uneventful

of biliary complications and appropriately managing them either by ERCP or percutaneous transhepatic techniques is crucial to increase the survival of these recipients.

The limitations of the study are its retrospective nature and the lesser number of patients in each category.

Conclusion

In conclusion, percutaneous biliary techniques are effective treatment options with good outcome in LDLT patients with biliary complications and failed ERCP. Percutaneous techniques have a definite complimentary role to ERCP.

Acknowledgments

We would like to acknowledge the invaluable advice and unstinting support of our colleagues in the Departments of Medical and Surgical Gastroenterology and Department of Bio-Statistics. This work would not have been possible without the dedication and skill of our radiology technicians and nursing staff.

Financial support and sponsorship

Nil.

Conflicts of interest

There are no conflicts of interest.

References

1. Yazumi S, Chiba T. Biliary complications after a right-lobe living donor liver transplantation. J Gastroenterol 2005;40:861-5.
2. Verdonk RC, Buis CI, Porte RJ, Van der Jagt EJ, Limburg AJ, Van den Berg AP, *et al*. Anastomotic biliary strictures after liver transplantation: Causes and consequences. Liver Transpl 2006;12:726-35.
3. Greif F, Bronsther OL, Van Thiel DH, Casavilla A, Iwatsuki S, Tzakis A, *et al*. The incidence, timing, and management of biliary tract complications after orthotopic liver transplantation. Ann Surg 1994;219:40-5.
4. Mosca S, Militerno G, Guardascione MA, Amitrano L, Picciotto FP, Cuomo O. Late biliary tract complications after orthotopic liver transplantation: Diagnostic and therapeutic role of endoscopic retrograde cholangiopancreatography. J Gastroenterol Hepatol 2000;15:654-60.
5. Thethy S, Thomson B, Pleass H, Wigmore SJ, Madhavan K, Akyol M, *et al*. Management of biliary tract complications after orthotopic liver transplantation. Clin Transplant 2004;18:647-53.
6. Khuroo MS, Al Ashgar H, Khuroo NS, Khan MQ, Khalaf HA, Al-Sebayel M, *et al*. Biliary disease after liver transplantation: The experience of the King Faisal Specialist Hospital and Research Center, Riyadh. J Gastroenterol Hepatol 2005;20:217-28.
7. Sharma S, Gurakar A, Jabbour N. Biliary strictures following liver transplantation: Past, present and preventive strategies. Liver Transpl 2008;14:759-69.
8. Leoni CJ, Potter JE, Rosen MP, Brophy DP, Lang EV. Classifying complications of interventional procedure: A survey of practicing radiologists. J Vasc Interv Radiol 2001;12:55-9.
9. Gondolesi GE, Varotti G, Flormann SS, Munoz L, Fishbein TM, Emre SH, *et al*. Biliary complications in 96 consecutive right lobe living donor transplant recipients. Transplantation 2004;77:1842-8.
10. Shah SA, Grant DR, McGilvray ID, Greig PD, Selzer M, Lilly LB, *et al*. Biliary strictures in 130 consecutive right lobe living donor liver transplant recipients: Results of a Western center. Am J Transplant 2007;7:161-7.
11. Egawa H, Inomata Y, Uemoto S, Asonuma K, Kiuchi T, Fujita S, *et al*. Biliary anastomotic complications in 400 living related liver transplantations. World J Surg 2001;25:1300-7.
12. Atwal T, Pastrana M, Sandhu B. Post-liver Transplant Biliary Complications. J Clin Exp Heptol 2012;2:81-5.
13. Welling TH, Heidt DG, Englesbe MJ, Magee JC, Sung RS, Campbell DA, *et al*. Biliary complications following liver transplantation in the model for end-stage liver disease era: Effect of donor, recipient, and technical factors. Liver Transpl 2008;14:73-80.
14. Graziadei IW, Schwaighofer H, Koch R, Nachbaur K, Koenigsrainer A, Margreiter R, *et al*. Long-term outcome of treatment of biliary strictures after liver transplantation. Liver Transpl 2006;12:718-25.
15. Guichelaar MMJ, Benson J, Malinchoc M, Krom RAF, Wiesner R, Charlton M. Risk factors for and clinical course of non-anastomotic biliary strictures after liver transplantation. Am J Transpl 2003;3:885-90.
16. Kulkarni CB, Pullara SK, Moorthy S, Prabhu NK, Nazar PK, Kannan RR. Percutaneous transhepatic balloon dilatation of benign bilioenteric strictures: Analysis of technique and long-term outcome. Gastrointest Interv 2015;4:112-9.
17. Ryan ME, Geenen JE, Lehman GA, Aliperti G, Freeman ML, Silverman WB, *et al*. Endoscopic intervention for biliary leaks after laparoscopic cholecystectomy: A multicenter review. Gastrointest Endosc 1998;47:261-6.
18. Bergman JJ, Van den Brink GR, Rauws EA, De Wit L, Obertop H, Huibregtse K, *et al*. Treatment of bile duct lesions after laparoscopic cholecystectomy. Gut 1996;38:141-7.
19. Brady AP, Malone DE, Deignan RW, O'Donovan N, McGrath FP. Fibrin sealant in interventional radiology: A preliminary evaluation. Radiology 1995;196:573-8.
20. Kusano T, Kida H, Nishiwaki Y, Ikematsu Y, Goto K, Kuroda H, *et al*. Percutaneous sclerotherapy for intractable external biliary after hepatectomy. Int Surg 2003;88:72-5.
21. Sadakari Y, Miyoshi A, Ohtsuka T, Kohya N, Takahashi T, Matsumoto K, *et al*. Percutaneous transhepatic portal embolization for persistent bile leakage after hepatic resection: Report of a case. Surg Today 2008;38:668-71.
22. Kyokane T, Nagino M, Sano T, Nimura Y. Ethanol ablation for segmental bile duct leakage after hepatobiliary resection. Surgery 2002;131:111-3.
23. Soehendra N, Nam VC, Grimm H, Kempeneers I. Endoscopic obliteration of large esophagogastric varices with bucrylate. Endoscopy 1986;18:25-6.
24. Görich J, Rilinger N, Sokiranski R, Siech M, Vogel J, Wikström M, *et al*. Percutaneous transhepatic embolization of bile duct fistulas. J Vasc Interv Radiol 1996;7:435-8.
25. Cerecedo-Rodriguez J, Phillips M, Figueroa-Barojas P, Kumer SC, Gaidhane M, Schmitt T, *et al*. Self expandable metal stents for anastomotic stricture following liver transplant. Dig Dis Sci 2013;58:2661-6.
26. Kaffes A, Griffin S, Vaughan R, James M, Chua T, Tee H, *et al*. A randomized trial of a fully covered self-expandable metallic stent versus plastic stents in anastomotic biliary strictures after liver transplantation. Therap Adv Gastroenterol 2014;7:64-71.
27. Civelli EM, Meroni R, Cozzi G, Milella M, Suman L, Vercelli R, *et al*. The role of interventional radiology in biliary complications after orthotopic liver transplantation: A single-center experience. Eur Radiol 2004;14:579-82.
28. Roumilhac D, Poyet G, Sergent G, Declerck N, Karoui M, Mathurin P, *et al*. Long-term results of percutaneous management for anastomotic biliary stricture after orthotopic liver transplantation. Liver Transpl 2003;9:394-400.
29. Sung RS, Campbell DA Jr, Rudich SM, Punch JD, Shieck VL, Armstrong JM, *et al*. Long-term follow-up of percutaneous transhepatic balloon cholangioplasty in the management of biliary strictures after liver transplantation. Transplantation 2004;77:110-5.
30. Zajko AB, Sheng R, Zetti GM, Madariaga JR, Bron KM. Transhepatic balloon dilation of biliary strictures in liver transplant patients: A 10-year experience. J Vasc Interv Radiol 1995;6:79-83.
31. Ozden I, Tekant Y, Bilge O, Acarli K, Alper A, Emre A, *et al*. Endoscopic and radiologic interventions as the leading causes of severe cholangitis in a tertiary referral center. Am J Surg 2005;189:702-6.
32. Ginat D, Saad WE, Davies MG, Saad NE, Waldman DL, Kitanosono T. Incidence of cholangitis and sepsis associated with percutaneous transhepatic biliary drain cholangiography and exchange: A comparison between liver transplant and native liver patients. AJR Am J Roentgenol 2011;196:73-7.