Article published online: 2021-07-30

Primary versus secondary achalasia: New signs on barium esophagogram

Pankaj Gupta, Uma Debi[1], Saroj Kant Sinha[1], Kaushal Kishor Prasad[1]

Departments of Radiology, and [1]Gastroenterology, Post Graduate Institute of Medical Education and Research, Chandigarh, India

Correspondence: Dr. Uma Debi, Department of Gastroenterology, Post Graduate Institute of Medical Education and Research, Chandigarh - 160 012, India. E-mail: debi_uma@yahoo.co.in

Abstract

Aim: To investigate new signs on barium swallow that can differentiate primary from secondary achalasia. **Materials and Methods:** Records of 30 patients with primary achalasia and 17 patients with secondary achalasia were reviewed. Clinical, endoscopic, and manometric data was recorded. Barium esophagograms were evaluated for peristalsis and morphology of distal esophageal segment (length, symmetry, nodularity, shouldering, filling defects, and "tram-track sign"). **Results:** Mean age at presentation was 39 years in primary achalasia and 49 years in secondary achalasia. The mean duration of symptoms was 3.5 years in primary achalasia and 3 months in secondary achalasia. False-negative endoscopic results were noted in the first instance in five patients. In the secondary achalasia group, five patients had distal esophageal segment morphology indistinguishable from that of primary achalasia. None of the patients with primary achalasia and 35% patients with secondary achalasia had a length of the distal segment approaching combined height of two vertebral bodies. None of the patients with secondary achalasia and 34% patients with primary achalasia had maximum caliber of esophagus approaching combined height of two vertebral bodies. Tertiary contractions were noted in 90% patients with primary achalasia and 24% patients with secondary achalasia. Tram-track sign was found in 55% patients with primary achalasia. Filling defects in the distal esophageal segment were noted in 94% patients with secondary achalasia. **Conclusion:** Length of distal esophageal segment, tertiary contractions, tram-track sign, and filling defects in distal esophageal segment are useful esophagographic features distinguishing primary from secondary achalasia.

Key words: Achalasia; barium swallow; pseudoachalasia; secondary achalasia

Introduction

Achalasia is an esophageal motility disorder characterized by absent primary peristalsis and impaired lower esophageal sphincter (LES) relaxation.[1] Primary or idiopathic achalasia is caused by degeneration of the inhibitory ganglion cells in the esophageal myenteric plexuses.[2] Secondary achalasia, also known as pseudoachalasia, is most commonly caused by malignant tumors of gastroesophageal junction (GEJ). Three-fourths of these patients are found to have carcinoma of the cardia.[3] Less common causes include carcinoma of the esophagus, metastatic disease, infective disorders like Chagas disease, and post-surgical states like post fundoplication and gastric banding.[4]

Achalasia is diagnosed based on clinical findings. Patients present with slowly progressive dysphagia, more to liquids than solids. The diagnosis can be made by manometry. Although patients with pseudoachalasia have a different clinical profile (duration of symptoms, age at presentation), there is significant overlap.[5] If not diagnosed early and accurately, pneumatic dilatation of the LES segment may be offered to these patients.[6] This leads to an inadvertent delay in appropriate treatment of the underlying malignancy, progression to an advanced stage, and shortened survival.

Esophageal manometry remains the gold standard investigation in diagnosing achalasia. However, findings can be non-specific with overlap between achalasia and pseudoachalasia.[7] Endoscopy is not very accurate

Access this article online	
Quick Response Code:	Website: www.ijri.org
	DOI: 10.4103/0971-3026.161465

in evaluating esophageal peristalsis and LES. Lack of peristalsis and difficulty negotiating LES are neither sensitive nor specific parameters. Retention of undigested food in the esophagus occurs only with advanced disease.[8] Thus, besides having a poor sensitivity and specificity in the diagnosis of achalasia, it is not always able to exclude pseudoachalasia.

Barium studies show a dilated non-peristaltic esophagus with smooth, tapered, symmetrical narrowing ("bird-beak narrowing") at the GEJ.[9] Though these findings are relatively specific for achalasia, their utility in the early phase of the disease is questionable. Moreover, the differentiation of achalasia and pseudoachalasia based on available criteria on barium esophagogram is imprecise.

Data about the usefulness of barium studies in differentiating primary from secondary achalasia are sparse.[10] Therefore, we performed this retrospective analysis to propose new criteria that could increase the sensitivity and specificity of differentiating achalasia from pseudoachalasia. To the best of our knowledge, this is the largest study till date describing the barium findings in primary and secondary achalasia.

Materials and Methods

We reviewed the radiology files of patients diagnosed with achalasia and pseudoachalasia form April 2011 to June 2013. A total of 80 patients underwent single-contrast barium swallow at presentation. Achalasia was diagnosed in 58 patients and pseudoachalasia in 22 patients. Of these, 33 patients (28 with primary achalasia and 5 with secondary achalasia) were excluded from the study as they had received treatment (balloon dilatation/metallic stents) before the barium study. Thus, 47 patients (30 with achalasia and 17 with pseudoachalasia) were finally recruited for analysis [Chart 1]. Diagnosis was based on clinical presentation, manometry, endoscopy, barium swallow, computed tomography (CT), and surgery. Endoscopic findings taken into consideration were the intraluminal growth, peristalsis, and ability to negotiate endoscope. Endoscopic biopsies from suspicious areas and histopathologic findings were recorded. A minimum of two and maximum of six biopsies were obtained (average 4). In pseudoachalasia group, the diagnoses made were carcinoma esophagus (n = 10), carcinoma cardia of stomach (n = 6), and lymphoma of GEJ (n = 1). In all the patients, the radiology reports documented absent primary peristalsis in the esophagus with a segment of distal esophageal narrowing that extended to the GEJ. The correct diagnosis of pseudoachalasia was mentioned in the reports of 15 patients with secondary achalasia.

Regarding the technique of barium swallow, 25 patients underwent a single-contrast barium swallow with low-density barium (Microbar®) 90% W/V and 10 patients underwent a double-contrast barium swallow with high-density barium (Microbar®-HD) 200%W/V. Of the remaining 12 patients, 7 underwent single-contrast and 5 underwent double-contrast upper gastrointestinal (GI) examinations, with a similar concentration of barium as in the barium swallow studies. Patients were called fasting on the day of examination. No antispasmodics were administered prior to the procedure. Multiple swallows were evaluated under fluoroscopy in supine position. Primary peristalsis and GEJ were evaluated in anteroposterior and oblique positions.

The radiographs were evaluated by two radiologists, PG and UD with 3 and 6 years of experience in Gastrointestinal radiology, respectively. Both were blinded to the clinical, manometric, endoscopic, and surgical findings. Findings recorded were: Esophageal dilatation at its widest point (compared with the vertebral body height, graded as less than one vertebral body height, more than one vertebral body height, and close to the combined height of two vertebral bodies), length of the narrowed distal esophageal segment (documentation similar to that done for dilatation), symmetry of the narrowed segment (concentric or eccentric), shouldering (abrupt proximal borders), filling defects, tram-track appearance, tertiary contractions, and gastric fundus abnormalities (when adequate barium passed into stomach).

All major study variables were subjected to univariate statistical analysis. Statistical analysis was performed using Statistical Package for Social Sciences software (version 17.0; SPSS, Chicago, IL, USA). To compare the differences between two groups (continuous variable), Student's t-test was applied. For nonparametric data, Mann–Whitney test was applied. $P < 0.05$ were considered as significant.

Results

Clinical presentation

Primary achalasia

Incidence was equally divided between males and females (males = 15 and females = 15). The mean age at presentation was 39 years (range, 18-74 years). Dysphagia

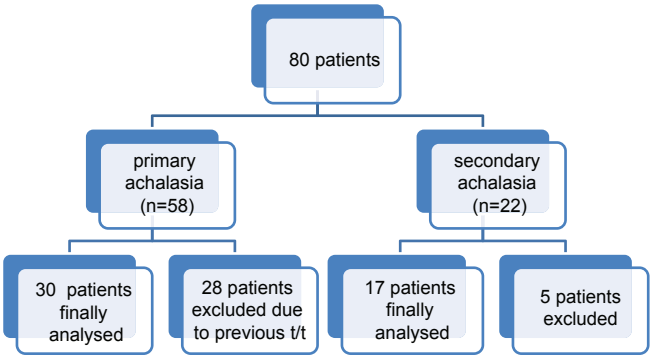

Chart 1: Patient inclusion in the study

was reported at presentation in all patients. Twenty patients clearly had dysphagia more to liquids than solids; rest had comparable dysphagia to both. Mean duration of symptoms was 3.5 years (range, 3 months to 10 years).

Secondary achalasia

Of the 17 patients with secondary achalasia, 9 were men and 8 were women. The mean age was 49 years (range, 31-78 years). All patients presented with dysphagia with a mean duration of 3 months (range, 1-11 months). Distinct history of dysphagia more to liquids was noted only in three patients.

Patients with secondary achalasia had a significantly shorter duration of symptoms ($P < 0.05$) than those with primary achalasia. However, there was no significant difference between the ages of two groups.

Manometric, endoscopic, and surgical findings

Primary achalasia

Typical findings on manometry were noted in 80% patients (n = 24). Esophageal aperistalsis was noted in all cases. Non-relaxing LES was noted in 91.5% cases (n = 22). One patient showed a hypertensive LES (resting pressure > 45 mm Hg). Poorly relaxing LES was noted in one patient. Endoscopy was performed in all patients. Endoscopic findings included a closed LES. In majority of the patients, LES opened in response to the advancing endoscope. Surgery was performed in none of the patients in this group.

Secondary achalasia

Manometry was performed in eight patients with pseudoachalasia. Similar to primary achalasia, all patients in secondary achalasia group had absence of esophageal peristalsis. However, in two patients, peristalsis was present in some swallows. LES was found to be non-relaxing in all patients and there was no significant difference in the pressure waveform between the two groups. Thus, overall, no features distinct from primary achalasia were noted. All patients underwent endoscopy. A closed LES was found in all cases and the endoscope could not be negotiated through the LES into the stomach in 10 patients. Endoscopy revealed carcinoma esophagus (n = 8) and carcinoma cardia of stomach (n = 5). Malignancy was not suspected on endoscopy in four patients. In these patients, aperistalsis was noted and endoscope could be passed. No mucosal abnormality or intraluminal growth was seen. Diagnosis was suggested on CT in these patients. Of these patients, repeat endoscopic biopsy yielded malignancy in three patients. In one patient, diagnosis of malignancy could be made only at surgery. Ten patients in this group underwent surgery. Seven patients were deemed unfit for surgery on the basis of the disease extent or their general medical condition. Of the 10 patients who underwent surgery, 8 underwent transhiatal esophagectomy and diagnosis of carcinoma esophagus and carcinoma cardia was confirmed in 6 and 2 patients, respectively. Two patients underwent palliative surgery for carcinoma cardia.

Findings on barium swallow

Primary achalasia

In all patients, smooth, symmetric, tapered narrowing of the distal esophagus extending till the GEJ was noted [Figure 1]. The length of narrowed segment of esophagus was slightly less than one vertebral body height in majority of patients (n = 16) [Figure 2]. In 14 patients, the length of the narrowed segment was slightly more than one vertebral body height. None of the patients with primary achalasia had length of abnormal segment approaching the combined height of two vertebral bodies. The maximum caliber of dilated segment was more than one vertebral body height in 14 patients. It approached the height of two vertebral bodies in 10 patients and was less than one vertebral body height in 6 patients. Adequate passage of barium into the stomach was noted in 14 patients and fundus showed normal appearance in all these patients. Tram-track appearance of the narrowed segment was noted in 17 (57%) patients [Figure 3]. We propose muscular hypertrophy of the muscularis propria as the most plausible explanation for this sign. Tertiary contractions were noted in 90% patients (n = 27). None of the radiographs showed shouldering or filling defects.

Secondary achalasia

In five patients with secondary achalasia, barium studies revealed smooth, symmetric, tapered narrowing of the distal esophagus, indistinguishable from that of achalasia [Figure 4]. In rest of the patients (n = 12), there was eccentric narrowing [Figure 5]. Length of the distal narrowed segment was more than one vertebral body segment in 41% patients (n = 7), close to the height of two vertebral body heights in 35% (n = 6), and less than one vertebral body height in 24% patients (n = 4). The length of abnormal segment was found to be significantly greater in patients with pseudoachalasia ($P < 0.05$). Maximum caliber of the dilated esophagus was less than one vertebral body height in 11 patients and slightly more than one vertebral body height in 6 patients. None of the radiographs revealed dilatation approaching the combined height of two vertebral bodies in pseudoachalasia patients. Compared to patients with achalasia, esophageal dilatation was found to be significantly less ($P < 0.05$) in patients with pseudoachalasia. Tertiary contractions were noted in only four patients. Shouldering was noted in 15 patients. Filling defects within the narrowed segment were noted in 16 patients (94%) [Figure 6]. Even in radiographs where smooth, symmetric, tapered narrowing was noted, subtle filling defects were discernable in all cases. Evaluation of the gastric fundus was possible in seven patients and abnormalities in the appearance of fundus were noted in four cases. The overall sensitivity and specificity of

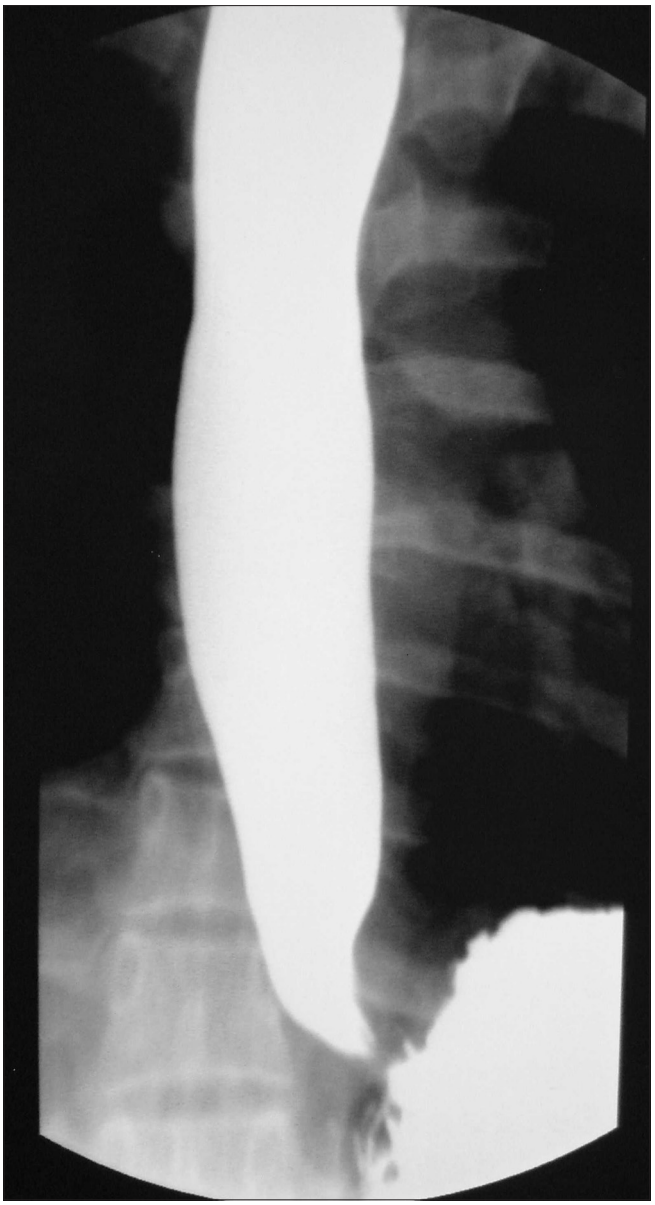

Figure 1: Barium esophagogram in a case of primary achalasia shows a short segment smooth, symmetric, tapered narrowing of the lower end of esophagus

Figure 2: Barium esophagogram in a case of primary achalasia reveals the distal smooth narrowed segment of esophagus with length less than a vertebral body height

six findings (length, symmetry, nodularity, shouldering, filling defects, and "tram-track sign") were found to 90% and 95%, respectively. Salient findings are summarized in Table 1.

Table 1: Salient barium findings in primary achalasia and secondary achalasia

Findings	*n* (%)	
	Primary achalasia	Secondary achalasia
Length of abnormal segment		
Less than one VB height	16 (53)	4 (24)
More than one VB height	14 (27)	7 (41)
Close to two VB height	0	6 (35)
Maximum caliber		
Less than one VB height	6 (20)	11 (65)
More than one VB height	14 (47)	6 (35)
Close to two VB height	10 (23)	0
Tram-track appearance	17 (57)	0
Shouldering	0	15 (88)
Filling defects	0	16 (94)
Symmetry	30 (100)	5 (29.5)
Tertiary contractions	27 (90)	4 (23.5)

VB: Vertebral body

Discussion

Secondary achalasia poses a diagnostic challenge as it simulates primary achalasia both clinically and on investigations (manometry, endoscopy, and radiological studies). Yet, the differentiation of these entities is essential. While primary achalasia is a benign disorder of esophageal motility and responds to balloon dilatations, secondary achalasia is most frequently caused by malignancies. Balloon dilatation in cases of secondary achalasia can prove disastrous as it entails delay in treatment of underlying malignancy.

Figure 3: Distal narrowed esophageal segment shows "tram-track appearance" with a central lucency bounded by barium on either side (arrow) in a case of primary achalasia

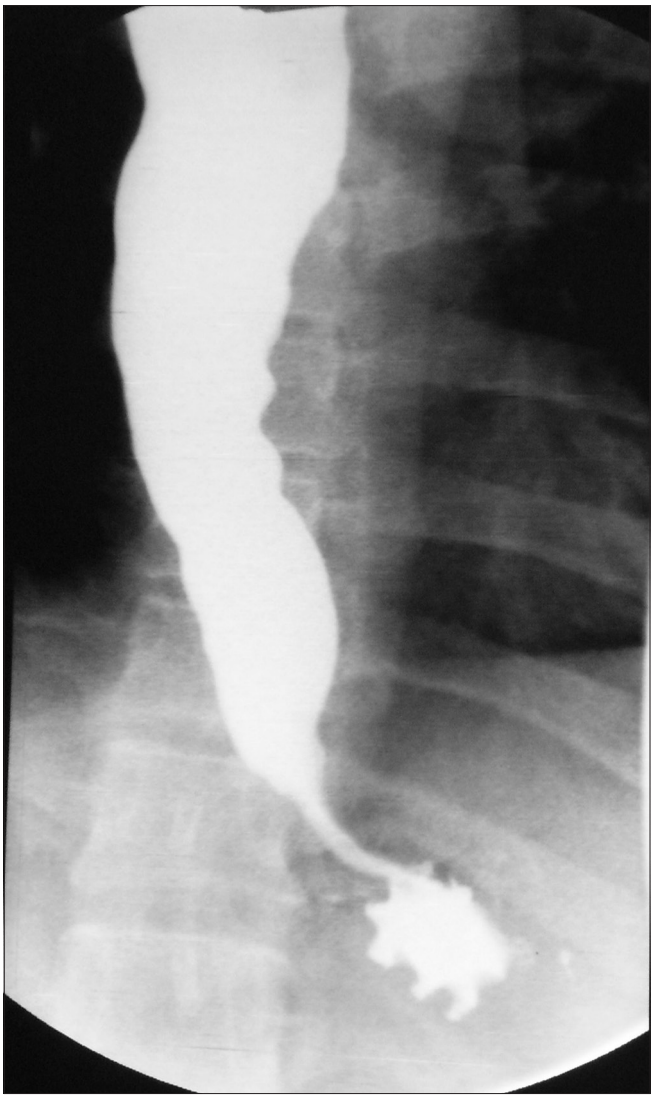

Figure 4: Barium esophagogram in a case of secondary achalasia reveals the morphology of distal esophagus to be similar to that of primary achalasia. Also note tertiary contractions

Attempts have been made to distinguish primary from secondary achalasia using clinical, manometric, endoscopic, and radiological criteria.[10] However, none of these have proved to be completely precise.

Achalasia is characterized by absent primary peristalsis on fluoroscopy. Morphologically, there is smooth, symmetric, tapered narrowing of the distal short segment of esophagus, producing a "bird-beak appearance." However, similar fluoroscopic and morphologic pattern can be seen in secondary achalasia. This makes a confident diagnosis of achalasia based on barium swallow difficult, and cases where secondary achalasia produced by malignancy was reported as primary achalasia are well documented in literature.[10] Researchers have attempted to lay criteria that allow a diagnosis of secondary achalasia on barium studies with a greater sensitivity and specificity.[10] This is important because diagnosis of secondary achalasia is based on combination of results (manometric, endoscopic, radiological, and surgical) rather than any single modality. No specific manometric pattern differentiating achalasia from pseudoachalasia is available.[7] Similarly, endoscopy can be misleading in cases where no obvious growth is noted. Evaluation of esophageal peristalsis and LES status during endoscopy is not very accurate. Even lack of peristalsis and difficulty negotiating LES are neither sensitive nor specific. Retention of undigested food in the esophagus, though more specific, occurs only in patients with advanced disease.[6]

Tracey *et al.* reviewed clinical, endoscopic, manometric, barium esophagographic, and CT data of five patients with secondary achalasia due to malignant disease.[11] As a control group, 10 patients with primary achalasia were evaluated. Though patients with secondary achalasia had shorter duration of dysphagia, substantial overlap with primary achalasia group was noted. Barium studies showed no features of malignant stricture. Endoscopic biopsy diagnosed cancer in only two patients, though difficult

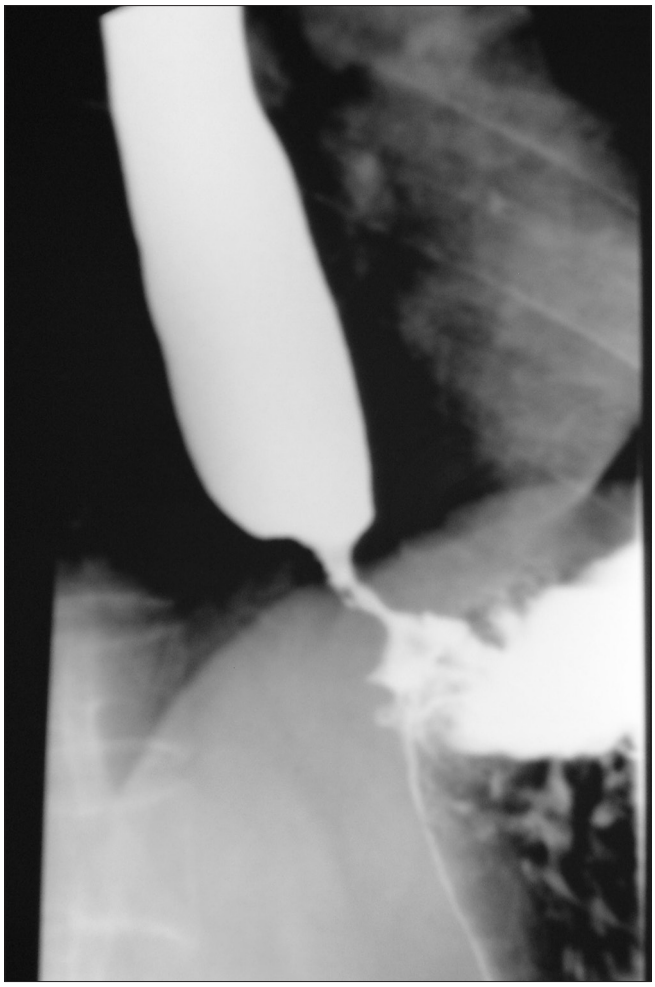

Figure 5: Distal esophageal segment shows asymmetry, shouldering, and irregularity suggesting a diagnosis of secondary achalasia

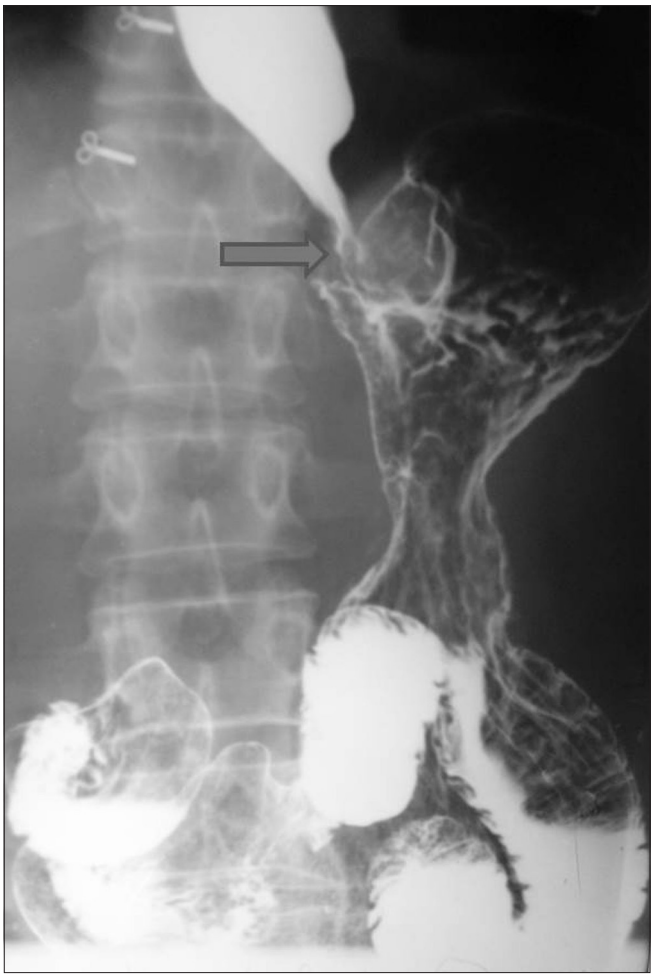

Figure 6: Distal esophageal segment in a case of secondary achalasia showing a subtle filling defect (arrow)

passage of endoscopy across the stricture was noted in all patients with secondary achalasia. Additionally, no obvious features to suggest the diagnosis were noted on CT scans and manometry in the secondary achalasia group. In a meta-analysis comprising 5 patients with secondary achalasia and 174 patients with primary achalasia, Gockel *et al.* found no distinctive manometric, endoscopic, and esophagographic features to distinguish primary from secondary achalasia.[12] Similar to the study by Tracey *et al*., Gockel *et al.* found the clinical features of shorter duration of symptoms and older age as the most useful criteria to suspect secondary achalasia. Kahrilas *et al*. evaluated six patients with secondary achalasia and 161 patients with primary achalasia.[10] They reviewed the clinical, manometric, endoscopic, and radiological data of these patients. They noted a higher age at presentation for secondary achalasia patients. Conventional esophageal manometry failed to discriminate achalasia from pseudoachalasia. Endoscopy with biopsy yielded a diagnosis of pseudoachalasia in five patients. They also noted that esophagography with amyl nitrate inhalation was useful in differentiating secondary from primary achalasia. We also found clinical criteria to be quite useful in differentiating secondary form primary achalasia. The mean age at presentation for primary achalasia in our study group was 39 years (range, 18-74 years) compared to 49 years for secondary achalasia group, though the difference between the two groups was not statistically significant. Mean duration of symptoms was 3.5 years (range, 3 months to 10 years) in primary achalasia group versus 3 months in secondary achalasia group and this difference was statically significant. Similar to previous studies, no distinctive features were recorded in eight patients who underwent manometry in the secondary achalasia group. Endoscopy with biopsy yielded false-negative results in four patients. However, repeat endoscopy and biopsy was positive in three patients. In one patient, even repeat endoscopies were negative.

Only a single large retrospective study reviewing the barium findings in primary and secondary achalasia is available. In this study, Woodfield *et al*. reviewed the records of 29 patients with primary achalasia and 10 patients with secondary achalasia.[9] They reviewed the radiographs to determine the morphologic features of the narrowed

distal esophageal segment and gastric cardia and fundus. They proposed that pseudoachalasia should be strongly considered if esophagograms reveal a narrowed distal esophageal segment longer than 3.5 cm with little or no proximal dilatation. The degree of esophageal dilatation above the narrowed segment was also found to be a significantly important criterion differentiating secondary achalasia from primary achalasia. Classic findings of secondary achalasia (eccentric stricture with nodularity and shouldering) were found in only 40% of patients. In our study, classic findings of secondary achalasia were noted in 70% of patients. The remaining 30% showed distal esophageal segment indistinguishable from primary achalasia. We also confirm the statistical significance of length of abnormal distal esophageal segment and caliber of the esophagus above the stricture in differentiating cases of primary from secondary achalasia. However, rather than measuring the absolute esophagus length and caliber (in cm), we compared these with the vertebral body height (in the same radiograph) as this method seems to be easily applicable and less cumbersome.[10] We propose new radiological signs not described in the literature. Though tertiary contractions are a common phenomenon on barium esophagograms in patients with motility disorders and have been described previously, their significance in the context of differentiation of primary from secondary achalasia has not been discussed. Tertiary contractions were noted in 25% patients with secondary achalasia, while they were noted in 90% patients with primary achalasia. However, the limitation of this sign is that in patients with long-standing achalasia, the tertiary contractions may not be seen. Moreover, there finding is rather non-specific. We described tram-track sign in patients with primary achalasia. We found this sign in almost 60% patients with primary achalasia. This finding has not been described previously. This correlates with the muscular hypertrophy of muscularis propria at histopathology. Yet another finding having a high positive predictive value was presence of filling defects noted in the distal esophageal segment in more than 90% patients of secondary achalasia. Nodularity at the proximal aspect of the stricture (shouldering) is an established sign of malignancy; however, the filling defects within the strictured segment have not been discussed previously. The latter two signs may be better seen on double-contrast barium study. We did not evaluate the diagnostic utility of double-contrast esophagogram in the present study. However, we believe that it has a definite role in cases that appear equivocal on a single-contrast esophagogram.

In the present study, in the secondary achalasia group, the condition was entirely due to malignant causes. However, there are few non-neoplastic causes of secondary achalasia. These include infective causes like Chagas disease, scleroderma, and post-surgical states like fundoplication. The differentiating esophagograhic features discussed in the present study are not applicable in these conditions. Chagas disease resembles primary achalasia on routine esophagogram; however, a study attempted to differentiate the two conditions based on the response of the proximal esophagus to wet swallows.[13] Scleroderma is another condition that may resemble primary achalasia. Barium esophagogram findings may overlap those of primary achalasia with dilatation and loss of peristaltic contractions. The upper one-third of the esophagus, however, is characteristically spared. Gastroesophageal reflux from patulous LES is an important component of scleroderma. It leads to reflux esophagitis and peptic strictures.[14]

There were several limitations in our study. The patient number was limited in each group, particularly, the secondary achalasia group. This could affect the statistical significance of the findings. We had a limited follow-up of patients in both the groups. Double-contrast esophagogram were not compared with single contrast esophagograms. Manometric data were not available for all patients in the secondary achalasia group. Moreover, we did not evaluate high-resolution manometry (HRM), the current technique for evaluation of esophageal motility disorders.[15] CT data were not evaluated in the present study. Histopathologic explanation for tram-track sign could not be obtained as all our patients in the primary achalasia group were subjected to balloon dilatation without obtaining endoscopic biopsy.

Conclusion

Barium study is reliable in distinguishing patients with secondary achalasia from those with primary achalasia. This holds significance considering the fact that manometric and endoscopic results can be equivocal in the former group, though we did not evaluate the role of HRM. In addition to confirming the significance of previously described signs (length of the distal esophageal segment and maximum caliber of the esophagus), we propose new signs with a high discriminatory value in differentiating the two conditions. These signs include the absence of tertiary contractions and presence of filling defects in secondary achalasia and the presence of tram-track sign in primary achalasia.

References

1. Achem SR, Gerson LB. Distal esophageal spasm: An update. Curr Gastroenterol Rep 2013;15:325.
2. Ghoshal UC, Daschakraborty SB, Singh R. Pathogenesis of achalasia cardia. World J Gastroenterol 2012;18:3050-7.
3. Katzka DA, Farrugia G, Arora AS. Achalasia secondary to neoplasia: A disease with a changing differential diagnosis. Dis Esophagus 2012;25:331-336.
4. Portale G, Costantini M, Zaninotto G, Ruol A, Guirroli E, Rampado S, *et al*. Pseudoachalasia: Not only esophago-gastric cancer. Dis Esophagus 2007;20:168-172.
5. Sandler RS, Bozymski EM, Orlando RC. Failure of clinical criteria to distinguish between primary achalasia and achalasia secondary to tumor. Dig Dis Sci 1982;27:209-213.

6. Pohl D, Tutuian R. Achalasia: An overview of diagnosis and treatment. J Gastrointestin Liver Dis 2007;16:297-303.
7. Tucker HJ, Snape WJ Jr, Cohen S. Achalasia secondary to carcinoma: Manometric and clinical features. Ann Intern Med 1978;89:315-318.
8. Ott DJ, Richter JE, Chen YM, Wu WC, Gelfand DW, Castell DO. Esophageal radiography and manometry: Correlation in 172 patients with dysphagia. AJR Am J Roentgenol 1987;149:307-311.
9. Woodfield CA, Levine MS, Rubesin SE, Langlotz CP, Laufer I. Diagnosis of primary versus secondary achalasia: Reassessment of clinical and radiographic criteria. AJR Am J Roentgenol 2000;175:727-731.
10. Kahrilas PJ, Kishk SM, Helm JF, Dodds WJ, Harig JM, Hogan WJ. Comparison of pseudoachalasia and achalasia. Am J Med 1987;82:439-446.
11. Tracey JP, Traube M. Difficulties in the diagnosis of pseudoachalasia. Am J Gastroenterol 1994;89:2014-2018.
12. Gockel I, Eckardt VF, Schmitt T, Junginger T. Pseudoachalasia: A case series and analysis of the literature. Scan J Gastroenterol 2005;40:378-385.
13. Ramos RI, Varrica LM, Dantas RO. Differences in response of the proximal esophagus to wet swallows in patients of Chagas' disease and idiopathic achalasia. Dis Esophagus 2006;19:401-405.
14. Santra S. Scleroderma esophagus. J Assoc Physicians India 2009;57:37.
15. Kahrilas PJ, Sifrim D. High-resolution manometry and impedance-pH/manometry: Valuable tools in clinical and investigational esophagology. Gastroenterology 2008;135:756-769.

Cite this article as: Gupta P, Debi U, Sinha SK, Prasad KK. Primary versus secondary achalasia: New signs on barium esophagogram. Indian J Radiol Imaging 2015;25:288-95.

Source of Support: Nil, **Conflict of Interest:** None declared.