Article published online: 2021-07-30

Blunt traumatic diaphragmatic hernia: Pictorial review of CT signs

Ravinder Kaur, Anuj Prabhakar[1], Suman Kochhar[1], Usha Dalal[2]

Departments of Radiodiagnosis, and [2]General Surgery, GMCH, [1]Department of Radiodiagnosis, PGIMER, Chandigarh, India

Correspondence: Dr. Ravinder Kaur, Associate Professor, Department of Radiodiagnosis, GMCH, Chandigarh 160030, India.
E-mail: drravinder1967@gmail.com

Abstract

Blunt diaphragmatic rupture rarely accounts for immediate mortality and may go clinically silent until complications occur which can be life threatening. Although many imaging techniques have proven useful for the diagnosis of blunt diaphragmatic rupture, multidetector CT (MDCT) is considered to be the reference standard for the diagnosis of diaphragmatic injury. Numerous CT signs indicating blunt diaphragmatic rupture have been described in literature with variable significance. Accurate diagnosis depends upon the analysis of all the signs rather than a single sign; however, the presence of blunt diaphragmatic rupture should be considered in the presence of any of the described signs. We present a pictorial review of various CT signs used to diagnose blunt diaphragmatic injury. Multiplanar reconstruction is very useful; however, predominantly axial sections have been described in this pictorial review as the images shown are from dual-slice CT.

Key words: Computed tomography, diaphragm, hernia, injury, trauma

Introduction

The incidence of blunt traumatic diaphragm hernia in patients undergoing surgical exploration ranges between 3 and 8%.[1] The diagnosis is usually missed initially because of concurrent severe abdominal and thoracic visceral injuries and lack of awareness of various signs of diaphragmatic injury on imaging. Blunt diaphragmatic injuries usually present late with intrathoracic herniation of abdominal viscera and carry a mortality rate of 30-60%.[2,3] Rapid and accurate diagnosis is essential as progressive herniation of visceral organs into the thoracic cavity can result in significant morbidity and mortality. In addition, preoperative identification allows for diaphragmatic repair during the initial exploratory laparotomy. Currently, multidetector CT (MDCT) is the modality of choice for detection of diaphragmatic injury with a sensitivity and specificity of 61-87% and 72-100%, respectively.[2,4-6] On MDCT, various signs indicating diaphragmatic hernia have been described. These should be meticulously looked for in patients undergoing imaging for blunt trauma.

Access this article online	
Quick Response Code:	Website: www.ijri.org
	DOI: 10.4103/0971-3026.161433

Embryology and Anatomy

The diaphragm is a dome-shaped muscular structure which serves as a boundary between the thorax and the abdomen. Embryologically, it is formed by four major structures:

- Septum transversum
- Pleuroperitoneal membrane
- Dorsal mesentery of the esophagus
- Body wall.

The diaphragm has a central tendon and a peripheral muscular component. The central tendon arises from the septum transversum, while the muscular component arises from the pleuroperitoneal membrane. Anteriorly, the diaphragm attaches to the posterior margins of the lower sternum and xiphoid process. The lateral or costal parts attach to the inner margins of the 6th through 12th ribs. Posteriorly, the lumbar part attaches to the medial and

lateral arcuate ligaments. The right crus is attached to the first, second, and third lumbar vertebrae, while the left crus is attached to the first and second lumbar vertebrae [Figure 1A and B]. The fibrous margin of the right and left crura forms the median arcuate ligament.[7]

The main function of the diaphragm is to act as a muscle of respiration. It acts along with the other accessory muscles of respiration including the sternocleidomastoid, scalene, and intercostal muscles to decrease the intrathoracic pressure during respiration. The diaphragm also aids in emesis, urination, and prevention of gastroesophageal reflux.

The normal openings in the diaphragm include the aortic hiatus at the thoraco-abdominal junction, the esophageal hiatus at the 10th thoracic vertebral level, and the hiatus for the inferior vena cava at the 8th thoracic vertebral level.[8]

Epidemiology

Diaphragmatic injury may occur due to both penetrating and blunt traumas. The frequency with which either of these mechanisms leads to diaphragmatic injury varies according to the geographic location.[9] The incidence of post-traumatic blunt diaphragmatic injury varies from 0.16 to 5%.[10] However, in patients undergoing surgery, the incidence of diaphragmatic injury increases to 3-8%.[1,11] Diaphragmatic tears are uncommon in children, with a reported prevalence of 0.07-6%.[12,13] The most common cause of blunt diaphragmatic rupture is road traffic accidents.[10] Other rare causes are fall from height or a crushing blow. The mortality rate following acute diaphragm injury varies from 5.5 to 51%.[10,14] Up to 70% of diaphragmatic tears are missed initially[15] and 7.2% of injuries that are missed in acute stage end up with complications.[16] Complications are mostly due to herniation of the viscera through the rent in the diaphragm and the resulting respiratory compromise.[16] Visceral incarceration may occur with or without strangulation or perforation. If strangulation occurs with herniation of viscera through the ruptured diaphragm, then the mortality rate varies from 30 to 80%.[9]

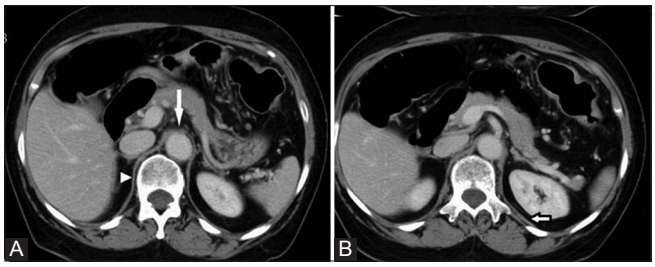

Figure 1 (A and B): (A) Normal diaphragmatic crura: (A) The crura (arrowhead) are noted on either side of the vertebra and are well delineated when in contact with fat. The medial arcuate ligament (arrow) is seen as a thin isodense band superior to the celiac axis (B) The lateral arcuate ligament (arrow) may be visible on CT scans as it courses toward the 12th rib

Many different modalities including conventional radiography, fluoroscopy, CT, and magnetic resonance imaging (MRI) have been used to evaluate the diaphragm; however, CT is the most commonly used modality.

Location and Mechanism of Injury

The left hemidiaphragm is injured in 50-80% of blunt diaphragmatic rupture and the right hemidiaphragm in 12-40% of cases [Figure 2]. Injury to the left hemidiaphragm is more common due to an area of congenital weakness in its posterolateral aspect. Also, the liver plays a protective role in the right diaphragm injuries by preventing herniation of the abdominal viscera.[16] Anteroposterior elongation and shearing of diaphragm in lateral thoracoabdominal impact and transmission of abdominal pressure to diaphragm in frontal impact are the possible mechanisms resulting in blunt traumatic diaphragmatic hernia.[17]

Presentation

Traumatic diaphragmatic hernias are classified into three types depending upon the time interval for diagnosis:[18]

- Type 1 hernia - when the diagnosis is made immediately following trauma
- Type 2 hernia - when the diagnosis is made within the recovery period
- Type 3 hernia - when the diagnosis is made when the patient presents with ischemia or perforation of herniated organs.

Imaging Findings on CT

CT scan has been accepted as the modality of choice in adults as well as pediatric patients whenever there is clinical or radiological suspicion of diaphragmatic injury.

Figure 2: Right diaphragmatic hernia. A 77-year-old male patient with history of a road side accident 3 years ago presented with breathlessness. Contrast-enhanced axial CT image shows herniation of the liver (White arrow) and the colon (Black Arrow) through a right-side diaphragmatic rupture

The various significant signs which have been described in literature for blunt diaphragmatic rupture are as follows:

- Diaphragm discontinuity
- Segmental non-recognition of diaphragm
- "Dangling diaphragm" sign
- "Dependent viscera" sign
- Intrathoracic herniation of abdominal contents
- "Collar sign"
- Elevated abdominal organs
- Thickened diaphragm
- Thoracic fluid abutting intra-abdominal viscera
- Hypoattenuated hemidiaphragm and associated fractured ribs.

These signs have been divided into direct and indirect signs and signs of uncertain or controversial origin [Table 1] according to Desir and Ghaye.[17]

- Diaphragmatic discontinuity: This is the most frequent sign observed in blunt traumatic diaphragmatic hernia (95.7%).[1] The sensitivity and specificity of a directly visualized diaphragmatic tear are 36-82.7% and 88-95%, respectively.[16] This sign represents direct visualization of the injury and the free edge of the disrupted diaphragm is noted demarcating the defect [Figure 3]. The defect may be central or peripheral in location. Free edge may be thickened due to hemorrhage or muscle retraction
- Segmental non-visualization of diaphragm: Segmental non-visualization of diaphragm is distinct from diaphragmatic discontinuity. This manifests as an isolated absence of a section of the injured diaphragm [Figure 4]. Sensitivity and specificity of this finding are 85.9% and 67.7%, respectively[16] for blunt diaphragmatic rupture. This sign may be falsely positive in elderly patients in whom segmental non-visualization of diaphragm may be a normal variant and in patients with basal atelectasis and hemothorax in whom the diaphragmatic margins may be blurred[2,16]
- Dangling diaphragm sign: The "dangling diaphragm" is a conspicuous sign of diaphragmatic injury. Free edge of the torn diaphragm is visible as it curls inward toward the center of the abdomen away from the chest wall at near right angle [Figure 3]. The sign differs from diaphragmatic discontinuity in that it results in comma-shaped fragment of the diaphragm, whether or not a gap in the diaphragm is appreciated. The dangling diaphragm sign has a sensitivity of 54% and a specificity of 98%.[18,19] This sign is linked to the segmental diaphragmatic defect
- Dependent viscera sign: Normally, the diaphragm prevents the upper abdominal viscera from coming

Table 1: CT signs of diaphragmatic injuries

Direct signs
Direct discontinuity of the diaphragm
Dangling diaphragm sign
Indirect signs
Collar sign
Intrathoracic herniation of viscera
Dependent viscera sign
Contiguous injury on either side of the diaphragm
Sinus cut-off sign
Signs of uncertain origin
Thickening of the diaphragm
Hypoattenuated diaphragm
Fractured rib
Diaphragmatic/peridiaphragmatic contrast extravasation

Modified from Bodanapally *et al.* (16) and Desir and Ghaye (17)

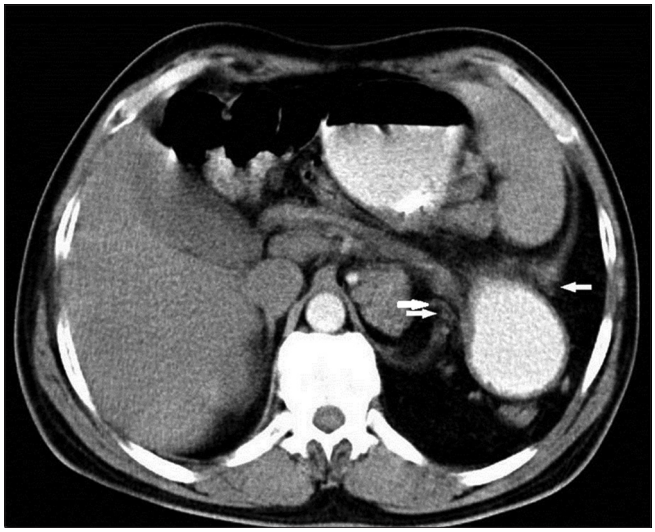

Figure 3: Diaphragm discontinuity sign and dangling diaphragm sign: A 45-year-old male patient with history of motor bike accident 4 months ago presented with pain chest and cough. Axial contrast-enhanced CT image of upper abdomen reveals diaphragm discontinuity sign (white arrows) and dangling diaphragm sign (double white arrows)

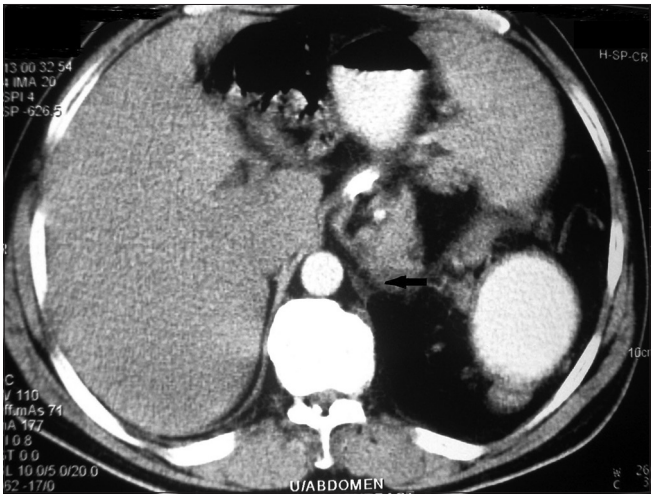

Figure 4: Segmental non-visualization of diaphragm. A 35-year-old female patient with history of fall from height 1 year ago presented with pain and vomiting. Axial contrast-enhanced CT image of upper abdomen reveals segmental non-visualization of diaphragm - only a part of the left crus is noted (arrow) and the rest of the diaphragm is not visualized

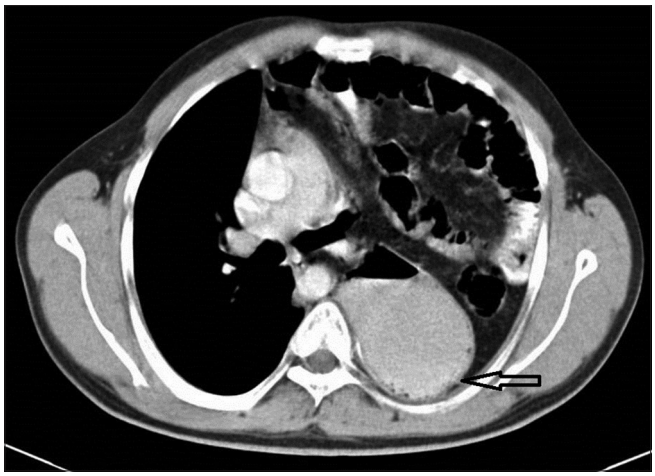

Figure 5: Dependent viscera sign. A 62-year-old male patient with history of motor bike accident 6 months ago presented with dyspnea. Axial contrast-enhanced CT image of chest reveals the stomach and bowel loops herniating into the thorax. The contrast-filled stomach is in direct contact with the posterior thoracic wall (Black arrow) (dependent viscera sign)

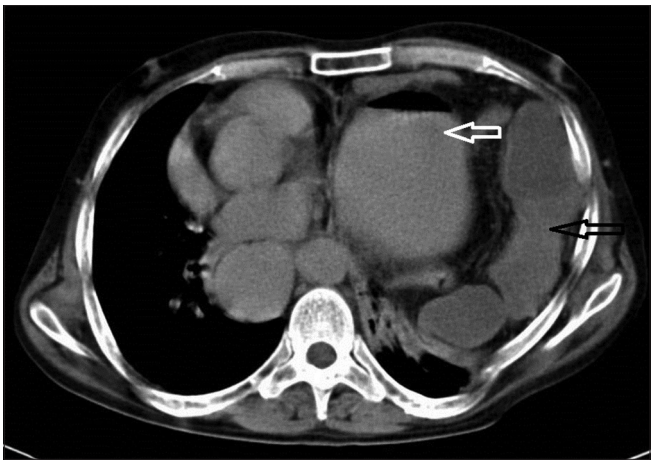

Figure 6: Intrathoracic herniation of the abdominal viscera. A 40-year-old male patient with history of motor vehicle accident 6 months ago presented with breathlessness. Axial CT image of chest reveals intrathoracic herniation of bowel loops (Black arrow) and stomach (White arrow) into the left hemithorax secondary to post-traumatic diaphragmatic rupture

in contact with the posterior chest wall in the supine position. When the diaphragmatic integrity is lost, the viscera herniate and shift posteriorly to lie in a "dependent" position against the chest wall [Figure 5]. On the left, the stomach or bowel either abuts the posterior ribs or is situated posterior to the spleen and on the right, the upper-third of the liver contacts the posterior chest wall. Some authors have emphasized that this sign has low sensitivity for the detection of small diaphragmatic ruptures, ruptures in an atypical location (e.g., an anterior location), and ruptures associated with a large pleural effusion[20]

- Intrathoracic herniation of abdominal contents: When the diaphragm ruptures, the negative intrathoracic pressure may lead to herniation of abdominal viscera into the thoracic cavity. The specificity of this sign has been reported to be 94.1-100%, while its sensitivity is only 8-81%.[16] If only left-sided injury is taken into account, the sensitivity improves to 90.9%.[16] On the left, the stomach and the colon are most likely to herniate into the thorax [Figure 6], while on the right it is the liver that shows intrathoracic herniation [Figure 2]. Other intra-abdominal contents, including small bowel, omentum, and spleen, may also herniate [Figure 7]. This sign may be absent if the intrathoracic pressure is increased due to any reason (e.g., hemothorax or positive pressure ventilation)
- Collar sign: When the abdominal contents herniate into the diaphragm, luminal narrowing is noted at the site of the diaphragm rent. This appearance is known as the "collar sign" on imaging[4] [Figure 8]. Multiple organs may combine to manifest this sign. This sign has a sensitivity of 25-85% and a specificity of 80-100%. The collar sign is less valuable for right-sided injuries
- Elevated abdominal organs: When the left-sided abdominal organs are visible 4 cm or more above the dome of the right hemidiaphragm or the right-sided abdominal organs are visible 5 cm or more above the dome of the left hemidiaphragm, they are considered to be abnormally elevated [Figure 9]. The sensitivity and specificity for this sign are 78.1% and 92.8%, respectively[3]
- Thickened diaphragm: Post-traumatic thickening occurs secondary to edema and haemorrhage within the substance of the diaphragm. The sensitivity and specificity of thickened hemidiaphragm are 36-60% and 58.4-77%, respectively.[16] The traumatized hemidiaphragm is compared with the opposite side to confirm the presence or absence of thickening. The measurement is taken 10 mm from the midline on both sides[2,16]
- Thoracic fluid abutting abdominal viscera: Post-traumatic diaphragmatic rupture may be associated with pleural effusion. The herniating viscera may come in contact with this fluid [Figure 10]. The sensitivity of this sign is 44.4%, while its specificity is 68.5%[3]
- Hypoattenuated hemidiaphragm and associated rib fractures: A hypoattenuated hemidiaphragm found in association with other features of blunt diaphragmatic rupture like segmental non-recognition and thickening of the diaphragm may indicate devascularization of the diaphragmatic muscle [Figure 11].[2] Rib fractures are also an indicator of diaphragmatic rupture, as a fractured rib may lead to diaphragmatic laceration; however, this sign has poor sensitivity.

There are various other signs described in literature like "hump and band sign" seen in right diaphragmatic hernia. Hump is due to herniation of liver and band sign is due to a

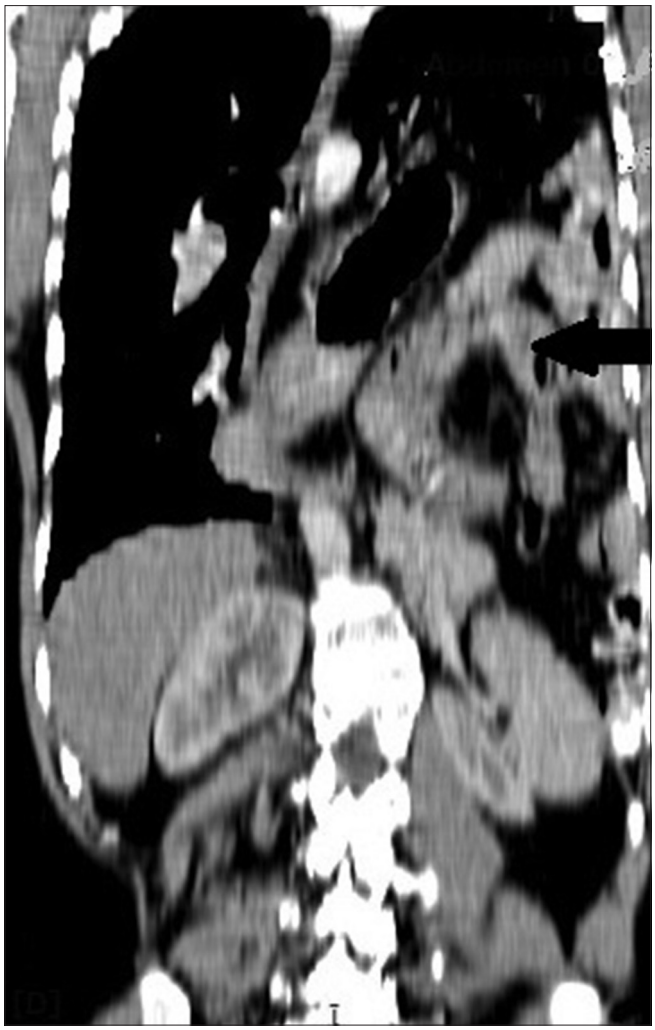

Figure 7: A 35-year-old man with history of blunt trauma 12 years ago presented with breathlessness. Coronal CT image reveals herniation of stomach and small bowel loops (black arrow) in the left hemithorax through the large defect in the left diaphragm due to its rupture

linear area of hypoattenuation that transects the herniated liver between the torn edges of the diaphragm."Sinus cut-off sign" occurs in the presence of blunt diaphragmatic hernia with pleural effusion and is a variant of dependent viscera sign. Dependent abdominal contents like small bowel, spleen etc., which are peripheral to the diaphragm due to herniation, prevent the normal layering of pleural fluid. As a result, the posterior costophrenic angle or sulcus appears cut off abruptly.[17]

Role of MRI

MR imaging may be used in more stable patients or where the CT examinations are equivocal. All the CT signs of diaphragmatic injury apply to MR also. MR imaging additionally provides excellent soft-tissue resolution and demonstrates the diaphragm as a thin sheet of muscle separating the thoracic and abdominal cavities. It has low

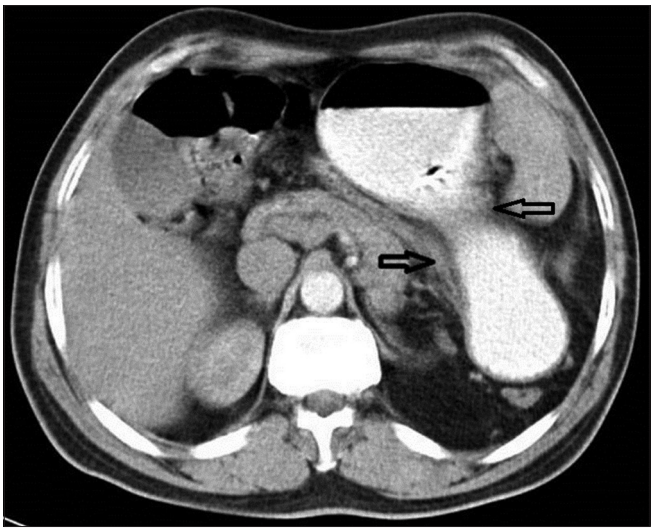

Figure 8: Collar sign: Same patient as in Figure 3. Axial CECT image of upper abdomen shows luminal narrowing of the herniated stomach at the site of the diaphragmatic tear (arrows)

signal intensity relative to that of other skeletal muscles with all MR imaging sequences.[21]

Role of Ultrasonography

USG is a good modality to assess the diaphragm function, especially in critically ill patients, and has replaced fluoroscopy in many institutions because of portability, lack of ionizing radiation, visualization of structures above and below the diaphragm, and ability to quantify diaphragmatic motion.[22]

Complications of Blunt Diaphragmatic Rupture

Intrathoracic herniation of abdominal viscera through a ruptured diaphragm may lead to various complications as follows:

- Compression of the viscera at the site of herniation
- Abnormal location of the viscera relative to the mesentery, leading to abnormal rotation.

The various complications observed in our patients were: gastric outlet obstruction, large bowel obstruction, small bowel obstruction, volvulus, and tension gastrothorax.

Gastric outlet large and small bowel obstruction occurs in patients in whom diaphragmatic injury has been missed in the acute stage. On CT, gastric outlet obstruction is seen as a dilated stomach with no distal passage of oral contrast. Obstruction of large and small bowel loops leads to dilatation of the proximal bowel loops with multiple air fluid levels. CT topogram and plain radiograph of abdomen demonstrates these findings [Figure 12]. The axial sections also show multiple dilated bowel loops with luminal narrowing at the site of herniation.

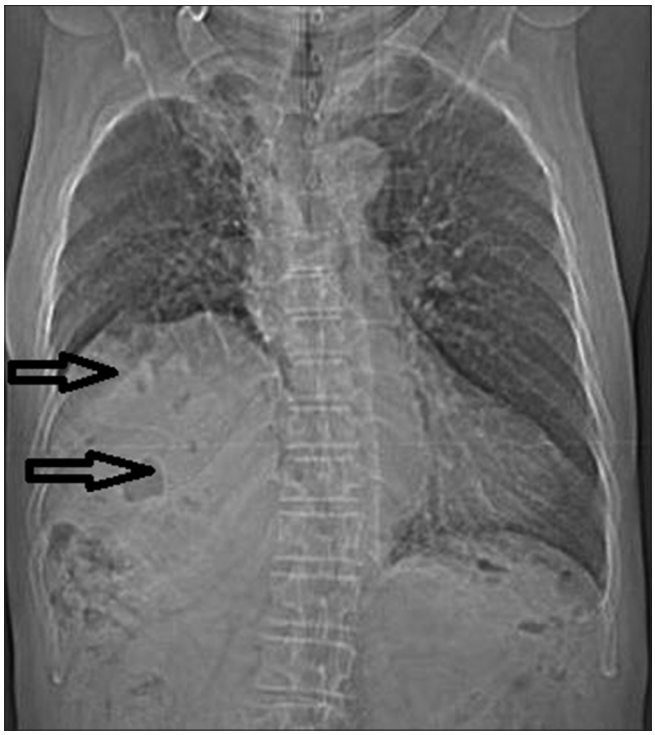

Figure 9: Elevated abdominal organs: Same patient as in Figure 2. CT topogram reveals elevation of liver and large bowel loops (Black arrows) on the right side

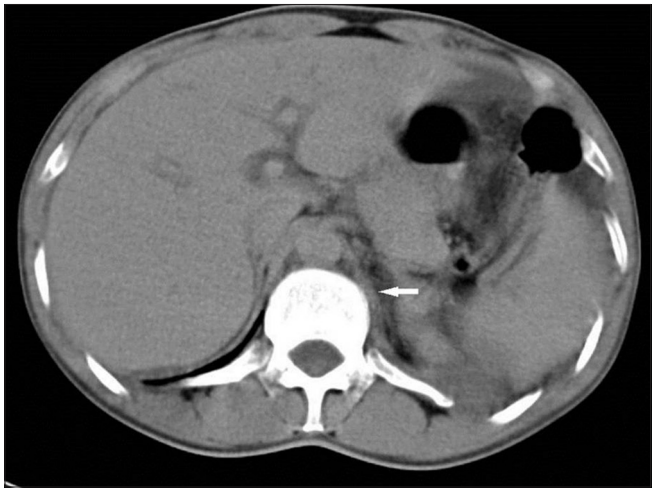

Figure 11: Hypoattenuated hemidiaphragm: Same patient as in Figure 6. Axial plain CT image of abdomen reveals hypodense and thickened left crus (white arrow) as compared to the right crus

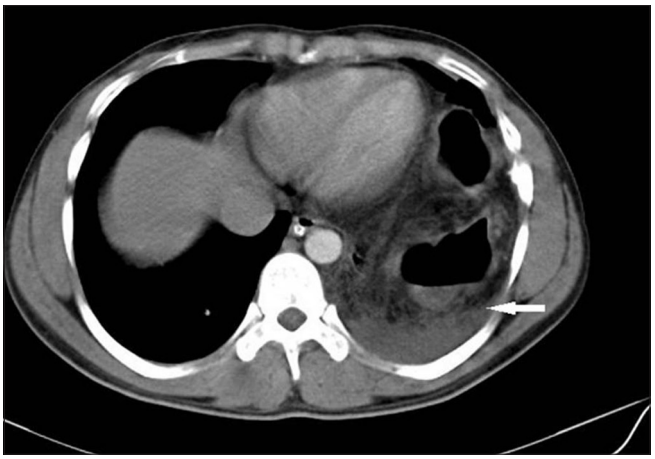

Figure 10: Thoracic fluid abutting abdominal viscera. A 37-year-old male patient with history of trauma few days ago presented in the emergency with features of intestinal obstruction. Axial contrast-enhanced CT image of upper abdomen reveals left pleural effusion that is abutting the herniated bowel (arrow)

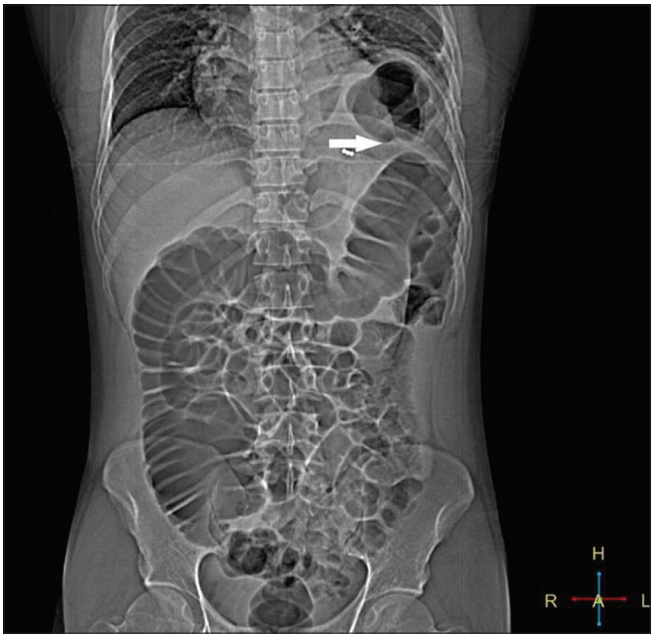

Figure 12: A 37-year-old male patient with history of trauma few days ago presented in the emergency with features of intestinal obstruction. CT topogram reveals a dilated air-filled large bowel herniating into the left hemithorax. The site of obstruction (arrow) is seen as an abrupt cut-off of the air column at the level of the diaphragm

Gastric volvulus occurs in diaphragmatic rupture as the gastro-oesphageal junction remains at its normal location in the abdomen while the rest of the stomach rotates up through the defect into the thoracic cavity.

Tension gastrothorax is another complication of gastric herniation following diaphragmatic rupture. The obstructed stomach continues to dilate due to air entry leading to collapse of the ipsilateral lung and mediastinal shift to the opposite side. The clinical picture and imaging appearance are similar to tension pneumothorax [Figure 13].

Diagnostic Pitfalls

The potential diagnostic pitfalls are numerous and include anatomic variants, congenital and acquired abnormalities. There are a few confounding factors that may prevent normal visualization of the diaphragm:

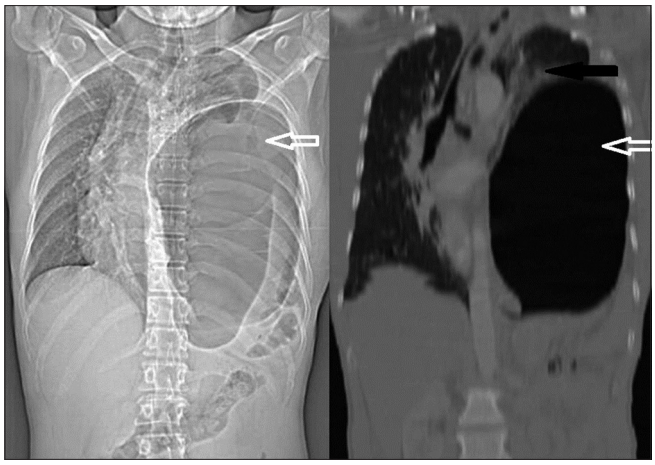

Figure 13: Tension gastrothorax. A 30-year-old male patient with history of trauma a month ago presented with vomiting and breathlessness. CT topogram and coronal image show evidence of air within the left hemithorax (air in dilated stomach) (white arrow) with absence of lung markings within, collapse of underlying lung, and mediastinal shift, similar to pneumothorax. However, in this case, the collapsed lung is pushed superiorly (black arrow) suggesting a diaphragmatic hernia, as opposed to a pneumothorax in which the lung is pushed inferiomedially

- Portions of the diaphragm may abut structures of similar attenuation like liver and spleen normally
- Few segments of the diaphragm may be parallel to the normal axial planes that are used in CT
- Normal variants like diaphragmatic humps and areas of apparent discontinuity where the diaphragm inserts on the costal margins
- Localized thinning (eventration) with maintenance of diaphragmatic continuity.

Conclusion

In conclusion, familiarity with all CT signs of diaphragmatic injury is required in establishing the diagnosis of diaphragmatic rupture and identifying its complications so that the patient can be adequately managed. Presence of a single sign should alert the radiologist to examine the diaphragm more closely and presence of two or more signs increases the probability of traumatic diaphragmatic hernia.

References

1. Panda A, Kumar A, Gamanagatti S, Patil A, Kumar S, Gupta A. Traumatic diaphragmatic injury: A review of CT signs and the difference between blunt and penetrating injury. Diagn Interv Radiol 2014;20:121-8.
2. Nchimi A, Szapiro D, Ghaye B, Willems V, Khamis J, Haquet L, *et al*. Helical CT of blunt diaphragmatic rupture. AJR Am J Roentgenol 2005;184:24-30.
3. Chen HW, Wong YC, Wang LJ, Fu CJ, Fang JF, Lin BC. Computed tomography in left-sided and right-sided blunt diaphragmatic rupture: Experience with 43 patients. Clin Radiol 2010;65:206-12.
4. Murray JG, Caoili E, Gruden JF, Evans SJ, Halvorsen RA Jr, Mackersie RC. Acute rupture of the diaphragm due to blunt trauma: Diagnostic sensitivity and specificity of CT. AJR Am J Roentgenol 1996;166:1035-9.
5. Killeen KL, Mirvis SE, Shanmuganathan K. Helical CT of diaphragmatic rupture caused by blunt trauma. AJR Am J Roentgenol 1999;173:1611-6.
6. Bodanapally UK, Shanmuganathan K, Mirvis SE, Sliker CW, Fleiter TR, Sarada K, *et al*. MDCT diagnosis of penetrating diaphragm injury. Eur Radiol 2009;19:1875-81.
7. Chavhan GB, Babyn PS, Cohen RA, Langer JC. Multimodality imaging of the pediatric diaphragm: Anatomy and pathologic conditions. Radiographics 2010;30:1797-817.
8. Nason LK, Walker CM, McNeeley MF, Burivong W, Fligner CL, Godwin JD. Imaging of the diaphragm: Anatomy and function. Radiographics 2012;32:E51-70.
9. Reber PU, Schmied B, Seiler CA, Baer HU, Patel AG, Büchler MW. Missed diaphragmatic injuries and their long-term sequelae. J Trauma 1998;44:183-8.
10. Mihos P, Potaris K, Gakidis J, Paraskevopoulos J, Varvatsoulis P, Gougoutas B, *et al*. Traumatic rupture of the diaphragm: Experience with 65 patients. Injury 2003;34:169-72.
11. Shanmuganathan K, Killeen K, Mirvis SE, White CS. Imaging of diaphragmatic injuries. J Thorac Imaging 2000;15:104-11.
12. Koplewitz BZ, Ramos C, Manson DE, Babyn PS, Ein SH. Traumatic diaphragmatic injuries in infants and children: Imaging findings. Pediatr Radiol 2000;30:471-9.
13. Brandt ML, Luks FI, Spigland NA, DiLorenzo M, Laberge JM, Ouimet A. Diaphragmatic injury in children. J Trauma 1992;32:298-301.
14. Rodriguez-Morales G, Rodriguez A, Shatney CH. Acute rupture of the diaphragm in blunt trauma: Analysis of 60 patients. J Trauma 1986;26:438-44.
15. Stark P, Jacobson F. Radiology of thoracic trauma. Curr Opin Radiol 1992;4:87-93.
16. Sliker CW. Imaging of diaphragm injuries. Radiol Clin North Am 2006;44:199-211, vii.
17. Desir A, Ghaye B. CT of blunt diaphragmatic rupture. Radiographics 2012;32:477-98.
18. Carter BN, Giuseffi J, Felson B. Traumatic diaphragmatic hernia. Am J Roentgenol Radium Ther 1951;65:56-72.
19. Desser TS, Edwards B, Hunt S, Rosenberg J, Purtill MA, Jeffrey RB. The dangling diaphragm sign: Sensitivity and comparison with existing CT signs of blunt traumatic diaphragmatic rupture. Emerg Radiol 2010;17:37-44.
20. Larici AR, Gotway MB, Litt HI, Reddy GP, Webb WR, Gotway CA, *et al*. Helical CT with sagittal and coronal reconstructions: Accuracy for detection of diaphragmatic injury. AJR Am J Roentgenol 2002;179:451-7.
21. Shanmuganathan K, Mirvis SE, White CS, Pomerantz SM. MR imaging evaluation of hemidiaphragms in acute blunt trauma: Experience with 16 patients. AJR Am J Roentgenol 1996;167: 397-402.
22. Gerscovich EO, Cronan M, McGahan JP, Jain K, Jones CD, McDonald C. Ultrasonographic evaluation of diaphragmatic motion. J Ultrasound Med 2001;20:597-604.

Cite this article as: Kaur R, Prabhakar A, Kochhar S, Dalal U. Blunt traumatic diaphragmatic hernia: Pictorial review of CT signs. Indian J Radiol Imaging 2015;25:226-32.

Source of Support: Nil, **Conflict of Interest:** None declared.