

# Superior thyroid artery pseudoaneurysm and arteriovenous fistula following attempted internal jugular venous access and its management

Pushpinder Singh Khera, Vinu Moses, Munawwar Ahmed, Shailesh Kakde<sup>1</sup>

Departments of Radiology and <sup>1</sup>Nephrology, Christian Medical College, Vellore, Tamil Nadu, India

**Correspondence:** Dr. Pushpinder Singh Khera, Department of Radiology, All India Institute of Medical Sciences, Jodhpur - 342 005, Rajasthan, India. E-mail: pushpinderkhera@gmail.com

## Abstract

Vascular injury during common jugular venous (IJV) access is a rare complication, usually involving injury to the common carotid artery. We describe a previously unreported complication of iatrogenic injury of IJV access involving a branch of the superior thyroid artery, and its endovascular management.

**Key words:** Arterio-venous fistula; IJV access; internal jugular venous access; pseudoaneurysm; superior thyroid artery

## Introduction

Complications during central venous catheter placement are uncommon and their incidence has decreased further with the use of ultrasound (USG) guidance for venous puncture.<sup>[1,2]</sup> Common vascular complications described during this procedure include common carotid artery (CCA) injury leading to bleeding, dissection, pseudoaneurysm, and thrombosis, internal jugular vein (IJV) dissection, and venous pseudoaneurysm formation.<sup>[1,2]</sup> Injury to external carotid artery branches is extremely rare. We describe one such case, along with its endovascular management.

## Case Report

A 50-year-old lady with advanced chronic renal disease was referred to the Interventional Radiology (IR) suite

for placement of an IJV dialysis access catheter. Her International Normalized Ratio (INR) was 1.5 and serum platelet count was 80,000/mm<sup>3</sup>. Before referral, unsuccessful attempts to cannulate the right IJV access were made in the dialysis laboratory. In the IR suite, a screening USG of the neck (Logiq E; GE Healthcare, Milwaukee, Wisconsin, USA; 10 MHz linear probe) revealed a moderate hematoma in the lower right neck compressing the IJV, with complete thrombosis of the right IJV. Multiple large collaterals were seen in the lower right neck. The left IJV was also partially thrombosed with thrombus distending the vein, suggesting an acute thrombus.

As there were relatively large and well-formed collaterals in the right lower neck draining into the subclavian vein, we did an USG-guided puncture and venogram of one of these collaterals, but decided not to attempt insertion of a dialysis cannula due to the tortuous anatomy.

As the patient had no other significant venous access for dialysis (femoral veins were also thrombosed and partly recanalized), we decided to recanalize the left IJV and insert a dialysis catheter. A non-thrombosed segment of left IJV was punctured under USG guidance, the thrombosed segment traversed with a 0.035-inch, 180-cm J-tip glide wire (Radifocus; Terumo, Tokyo, Japan), and balloon

### Access this article online

#### Quick Response Code:



**Website:**  
www.ijri.org

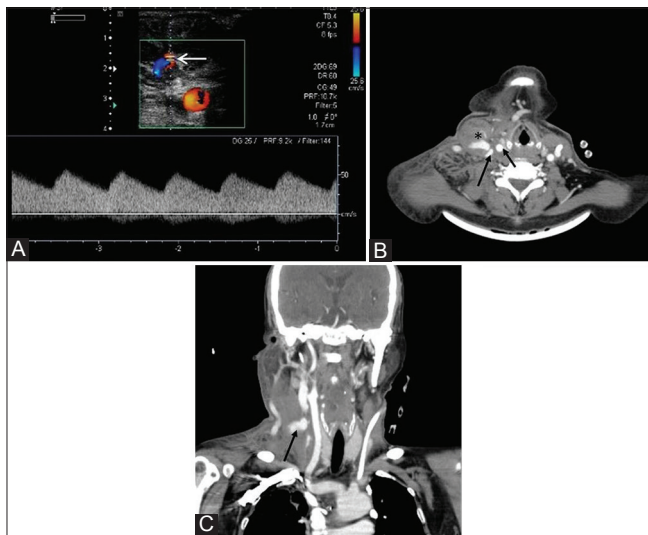
**DOI:**  
10.4103/0971-3026.150131

angioplasty was done with a 10 mm x 2 cm balloon (OPTA Pro PTA dilatation catheter, Cordis, Miami, USA) following which antegrade flow was established in the left IJV. We placed an 11-Fr IJV dialysis catheter (Bard, Salt Lake City, Utah, USA) with its tip within the left subclavian vein.

The patient went back to the dialysis laboratory for dialysis. One day after insertion of the left IJV dialysis catheter, the patient was found to have pain and an increasing swelling on the right side of the neck with ecchymosis. Doppler evaluation of the swelling showed a large hematoma anterior to the neck vessels with a pseudoaneurysm formation [Figure 1A]. The spectral waveforms of the right CCA, right internal carotid artery (ICA), and the right IJV were normal.

Computed tomographic (CT) angiography of the neck vessels (Philips Brilliance 6 CT scanner, Philips, Cleveland, Ohio, USA) showed a large hematoma in the right lower neck with an area of contrast extravasation adjacent to the hematoma, corresponding to the pseudoaneurysm. The pseudoaneurysm was in close relation to the right IJV and right CCA, but no definitive communication with either vessel could be demonstrated on the CT angiogram [Figure 1B and C].

As the pseudoaneurysm was recently formed, with a narrow neck on Doppler, we attempted USG-guided graded compression of the pseudoaneurysm (15 min of compression with slow release of pressure at the end of this period to assess outcome, with a 1 min break after which the compression was repeated once more) for two consecutive days in an attempt to obliterate the pseudoaneurysm. But the pseudoaneurysm persisted.

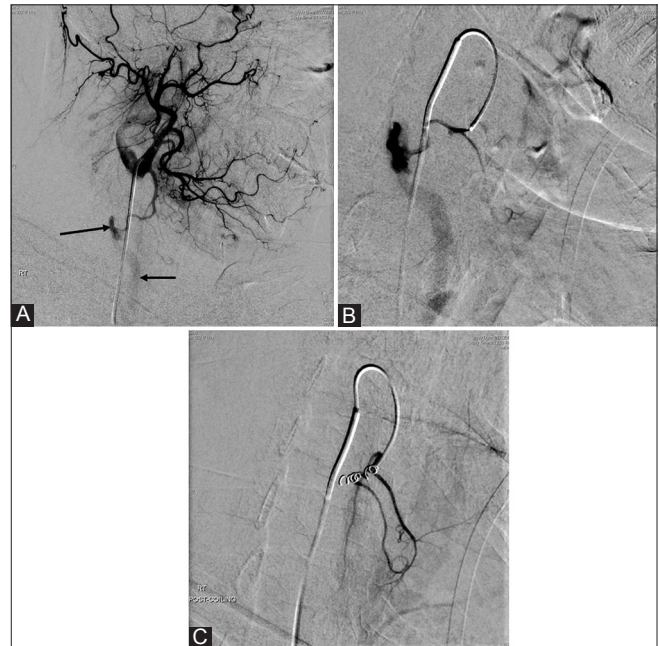

**Figure 1 (A-C):** Doppler and CT images of the neck. (A) Doppler image showing aliasing and low-resistance arterial flow within the pseudoaneurysm (arrow) (B) Axial contrast-enhanced CT of the neck showing a hematoma (asterisk) with contrast pooling anterior to the right IJV (long arrow) and the right CCA (small arrow) (C) Coronal CT image of the neck showing contrast pooling (arrow) in the right lower neck

As the hematoma and ecchymosis in the right lower neck continued to enlarge in size clinically, we decided to perform a digital subtraction angiogram (DSA) evaluation of the neck vessels.

Under local anesthesia, through a right transfemoral arterial access (4 Fr, 11 cm introducer sheath; Cordis, Miami, FL, USA), a right CCA angiogram was done (Artis Zee Biplane; Siemens, Erlangen, Germany) using a 100-cm, 4-Fr head-hunter catheter (Radifocus; Terumo, Tokyo, Japan).

Common and selective right external carotid artery angiograms showed a small pseudoaneurysm arising from the sternocleidomastoid branch of the right superior thyroid artery, with associated arteriovenous fistula [Figure 2A and B] draining into a venous collateral. The involved artery was superselectively cannulated with a microcatheter (Progreat Microcatheter System; Terumo, Tokyo, Japan) and embolized with two 2 mm x 2 cm, 0.18-inch fibered platinum pushable coils (Hilal; Cook, Washington, USA). Post-embolization check angiogram showed complete occlusion of the pseudoaneurysm and the arteriovenous fistula [Figure 2C]. The neck hematoma started reducing over the next 48 h and was almost completely resolved clinically by the end of 1 week.



**Figure 2 (A-C):** Pseudoaneurysm and arteriovenous fistula treated with coiling. (A) Right ECA angiogram, lateral projection (late arterial phase) showing a pseudoaneurysm (long arrow) arising from a branch of the right superior thyroid artery. Early filling of a venous channel is also seen (short arrow), confirming the presence of a fistula (B) Superselective angiogram of the right superior thyroid artery demonstrating the pseudoaneurysm and the arteriovenous fistula (C) Post-coiling angiogram of the right superior thyroid artery showing complete occlusion of the pseudoaneurysm and the arteriovenous fistula

## Discussion

The right IJV access is the standard practice for placing a central venous catheter/IJV catheter due to an in-line flow-directed placement and less chances of pneumothorax compared to a subclavian access.<sup>[2]</sup> Inadvertent arterial puncture during IJV cannulation is rare (0.1-0.4%) and usually involves injury to the CCA.<sup>[1,3]</sup>

The most common etiology leading to carotid artery injury and pseudoaneurysm formation is neck trauma,<sup>[4]</sup> with majority of the cases involving the ICA. Very few cases of external carotid artery pseudoaneurysm have been described,<sup>[5-8]</sup> either due to trauma or due to iatrogenic injury.

Arterial pseudoaneurysms usually increase in size over a course of few days and present as a pulsatile mass. However, our case manifested as a neck swelling and ecchymosis (due to subcutaneous bleeding), which may have been due to the relatively small pseudoaneurysm.

Duplex USG (Doppler) is a useful screening modality for initial assessment of an arterial injury. Subsequent confirmation can be done using CT angiography. In our case, Doppler and CT demonstrated the pseudoaneurysm, but precise localization of the injured vessel could be ascertained only on conventional angiography. This is likely due to the small branch of ECA which was injured.

Treatment options for pseudoaneurysm closure include surgical ligation, USG-guided compression, percutaneous thrombin injection, and endovascular techniques such as coil embolization and injection of liquid embolic agents.<sup>[3]</sup>

USG-guided compression did not succeed in our case, probably due to the lack of an underlying hard bony structure against which the pseudoaneurysm neck could have been compressed. We attempted it first only because it was a relatively non-invasive treatment option. However, USG-guided compression is not the preferred choice of treatment for neck pseudoaneurysms.<sup>[9]</sup>

USG-guided thrombin injection for pseudoaneurysm closure which was first described in 1986<sup>[10]</sup> is potentially risky in the head and neck territory due to the possibility

of inadvertent thrombin embolization to the intracranial circulation.

In our case, as the vascular anatomy was favorable, the injured artery could be selectively cannulated and embolized with coils.

## Conclusion

To our knowledge, there are no other case reports of superior thyroid artery branch pseudoaneurysm and arteriovenous fistula following attempted IJV access. This case report also highlights the importance of recognizing a vascular complication after jugular access.

## References

1. Randolph AG, Cook DJ, Gonzales CA, Pribble CG. Ultrasound guidance for placement of central venous catheters: A meta-analysis of the literature. *Crit Care Med* 1996;24:2053-8.
2. Sneff M. Central venous catheters. In: Rippe JM, Irwin RS, editors. *Intensive Care Medicine*. 2<sup>nd</sup> ed. Boston: Little Brown; 1991. p. 17-37.
3. Bernik TR, Friedman SG, Scher LA, Safa T. Pseudoaneurysm of the subclavian-vertebral artery junction --case report and review of the literature. *Vasc Endovascular Surg* 2002;36:461-4.
4. Kraus RR, Bergstein JM, DeBord JR. Diagnosis, treatment and outcome of blunt carotid arterial injuries. *Am J Surg* 1999;178:190-3.
5. Yuen JC, Gray DJ. Endovascular treatment of a pseudoaneurysm of a recipient external carotid artery following radiation and free tissue transfer. *Ann Plast Surg* 2000;44:656-9.
6. Campbell AS, Butler AP, Grandas OH. A case of external carotid artery pseudoaneurysm from hyoid bone fracture. *Am Surg* 2003;69:534-5.
7. Rhee CS, Jinn TH, Jung HW, Sung MW, Kim KH, Min YG. Traumatic pseudoaneurysm of the external carotid artery with parotid mass and delayed facial nerve palsy. *Otolaryngol Head Neck Surg* 1999;121:158-60.
8. Karas DE, Sawin RS, Sie KC. Pseudoaneurysm of the external carotid artery after tonsillectomy. A rare complication. *Arch Otolaryngol Head Neck Surg* 1997;123:345-7.
9. Li SH, Hsu SW, Wang SL, Chen HC, Huang CH. Pseudoaneurysm of the external carotid artery branch following radiotherapy for nasopharyngeal carcinoma. *Jpn J Clin Oncol* 2007;37:310-3.
10. Cope C, Zeit R. Coagulation of aneurysms by direct percutaneous thrombin injection. *AJR Am J Roentgenol* 1986;147:383-7.

**Cite this article as:** Khera PS, Moses V, Ahmed M, Kakde S. Superior thyroid artery pseudoaneurysm and arteriovenous fistula following attempted internal jugular venous access and its management. *Indian J Radiol Imaging* 2015;25:15-7.

**Source of Support:** Nil, **Conflict of Interest:** None declared.