Article published online: 2021-08-02

Transient angioedema of small bowel secondary to intravenous iodinated contrast medium

Kirankumar N Kulkarni, Rahul G Hegde, Ankit Balani, Anagha R Joshi

Department of Radiology, Lokmanya Tilak Municipal Medical College and Lokmanya Tilak Municipal General Hospital, Mumbai, Maharashtra, India

Correspondence: Dr. Rahul G Hegde, B-302, Shreenath Plaza, LT Road, Mulund (East), Mumbai - 400 081, Maharashtra, India.
E-mail: rahulhegde@gmail.com

Abstract

We report the clinical details and imaging findings of a case of transient angioedema of the small bowel following intravenous administration of non-ionic iodinated contrast material in a 17 year old female with no predisposing risk factors. Findings included long segment, symmetric, circumferential, low-density, bowel wall thickening involving the duodenum, jejunum, and most of the ileum on computed tomography scan obtained at 7 min following intravenous contrast material injection. This entity is self-limiting with a favourable clinical outcome and requires no specific treatment but only aggressive clinical monitoring.

Key words: Anaphylaxis; CECT; transient angioedema

Introduction

Acute allergy-like reactions subsequent to use of iodinated contrast material are well known, with urticaria being the most common adverse reaction. The spectrum varies from transient minor cutaneous reactions to severe life-threatening reactions such as cardiac arrhythmia and cardiac arrest.[1] Gastrointestinal manifestations are uncommon, with transient angioedema of bowel being a rarely reported entity.[2] This article illustrates the imaging findings of transient angioedema of the bowel on computed tomography (CT) examination.

Case Report

A 17 year old female was referred for CT of the abdomen and pelvis for evaluation of generalized abdominal pain of 6 months. There was no history of altered bowel movements. Clinical and USG examinations of the abdomen and pelvis were unremarkable.

Access this article online	
Quick Response Code:	Website: www.ijri.org
	DOI: 10.4103/0971-3026.137065

CT of the abdomen and pelvis was performed on a 64-detector row CT scanner (Brilliance CT; Philips, Best, the Netherlands) after giving 1.0 L of 20% diluted non-ionic iodinated oral contrast material (300 mg I/ml, Ultravist; Bayer Pharma AG, Berlin, Germany) 1 h before and 300 ml of the same just before the scan. After obtaining a non-enhanced CT, 70 ml of intravenous non-ionic iodinated contrast material (300 mg I/ml, Ultravist; Bayer Pharma AG, Berlin, Germany) was administered at a rate of 3 ml/sec via an automated pressure injector. CT scans of the abdomen and pelvis were obtained at 1 and 7 min following the administration of intravenous contrast material. CT revealed long segment, symmetric, circumferential, low-density, bowel wall thickening involving the duodenum, jejunum, and most of the ileum on the delayed scan obtained at 7 min following intravenous contrast material injection. The presence of low-density thickened submucosa sandwiched between the enhancing mucosa and serosa gave an appearance referred to as the "target sign" [Figure 1]. There was no such thickening of the bowel wall on the non-enhanced scan or on the scan obtained at 1 min post injection [Figure 2]. There was neither

free fluid nor mesenteric fat stranding. The mesenteric vessels were of normal caliber with no filling defects. The colon appeared normal in all the scans.

The patient experienced mild abdominal discomfort post procedure. Clinical examination revealed mild tachycardia with no skin rash or pruritus. A repeat delayed scan obtained at 45 min revealed reduction in the bowel wall edema [Figure 3]. The patient became asymptomatic in a few hours following the scan, with no delayed symptoms. The patient was monitored over a period of 1 h for vital parameters including pulse, blood pressure, and cutaneous reactions. No medications were given. Follow-up evaluation after 24 h revealed no significant clinical findings.

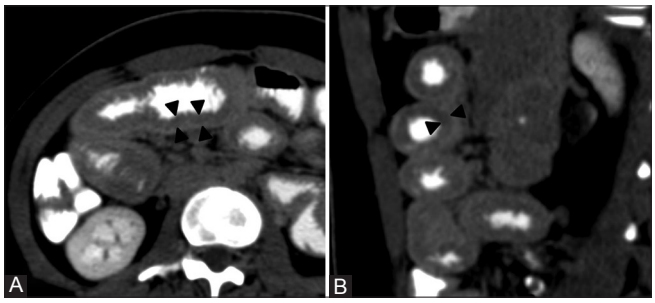

Figure 1 (A and B): Axial (A) and parasagittal (B) images from CT of the abdomen and pelvis reveal long segment, circumferential, small bowel wall thickening. Note the pattern of the bowel wall with the low-density submucosa (outlined by black arrowheads) surrounded by enhancing mucosa and serosa giving a "target" appearance

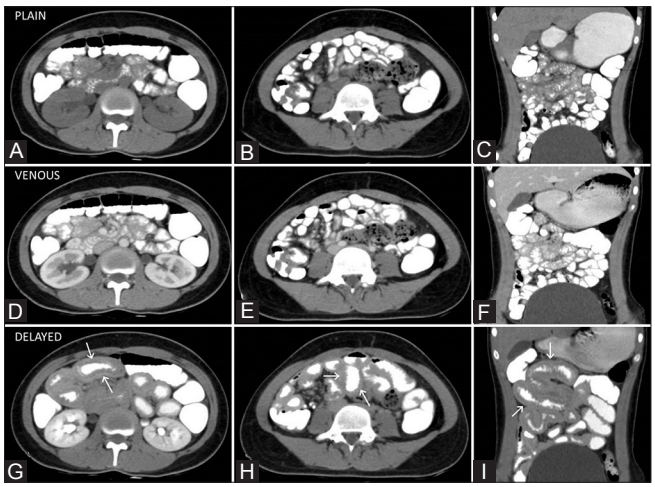

Figure 2 (A and I): Axial and coronal CT of the abdomen and pelvis in the unenhanced (A-C) venous (D-F) and delayed phases (G-I) revealing circumferential regular wall thickening (white arrows) of the small bowel on the delayed phase (G-I) which was not present on the unenhanced and venous phases (A-F)

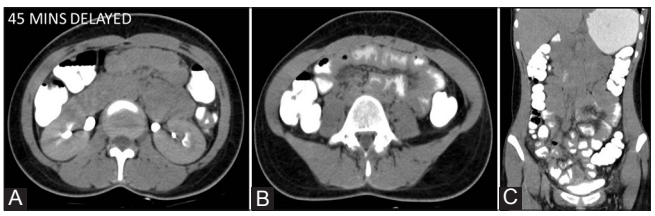

Figure 3 (A and C): Axial (A and B) and coronal (C) CT of the abdomen obtained 45 min following the administration of intravenous material shows reduction of previously identified bowel wall thickening. This was accompanied by clinical recovery of the patient

Discussion

The American College of Radiology has classified adverse contrast reactions according to degree of severity [Table 1].[3]

Mild reactions usually do not require any specific treatment. These reactions, however, can progress into a more severe category and, hence, aggressive clinical monitoring is warranted. Cutaneous allergy-like reactions are well known, but transient angioedema of the small bowel as an adverse contrast reaction is rarely documented, with less than eight cases reported in English literature.[2,4,5] The incidence of post iodinated contrast angioedema of the skin and upper airway mucosal membranes is 0.01%.[6] However, the exact incidence of bowel wall angioedema is not known as it is an underreported entity. However, we believe that the incidence of bowel wall angioedema should be similar to that. The basic underlying pathophysiology is of non-allergic, contrast material-induced immediate hypersensitivity reaction.

Angioedema of small bowel has also been associated with a variety of diseases, including hereditary and acquired C1-esterase inhibitor deficiency, drugs like angiotensin converting enzyme inhibitors, and food. Deregulation of the complement and kallikrein-kinin systems results from either a deficiency or a dysfunction of the C1-esterase inhibitor, resulting in angioedema.[7]

Angioedema of the bowel wall is characterized by long segment, symmetric, circumferential, low-density, bowel wall thickening which indicates edema in the submucosa of the bowel wall and gives a target appearance to the bowel wall referred to as the "target" sign. The differential diagnosis of target sign on CT includes Crohn's disease, intestinal tuberculosis, ischemic bowel disease, vasculitis like Henoch-Schönlein purpura and radiation enteritis, apart from angioedema of the bowel.[8]

Skip areas of bowel wall thickening, hyperemic vasa recta (comb sign), sinus, and fistulae point toward Crohn's disease.[8,9] Irregular, shaggy enhancement of the asymmetrically thickened bowel wall, omental thickening, and mesenteric and peritoneal inflammation with necrotic lymphadenopathy are suggestive of intestinal tuberculosis.[10] Occluding thrombus may be apparent in case of ischemic bowel disease. Radiation enteritis is suggested by the clustered bowel loops in the radiation field.[8] Other less common causes of submucosal intestinal edema include hypoproteinemia, congestive heart failure, portal hypertension, and lymphatic obstruction.

Table 1: Classification of contrast media induced reactions as per severity

Mild	Moderate	Severe
Self-limited without any evidence of progression	Not immediately life-threatening, but requires treatment	Life-threatening
Nausea, vomiting, mild abdominal discomfort, itching and pruritus, cough, headache, sweat, rash, anxiety, chills, flushing	Tachycardia, bradycardia, hypertension, hypotension, dyspnea, pronounced cutaneous reaction, laryngeal edema, pulmonary edema	Convulsion, profound hypotension, severe or progressive laryngeal edema, arrhythmias, cardiopulmonary arrest

Adapted from the American College of Radiology (ACR) Manual on Contrast Media-Version 9, 2013

In this case, there was long segment submucosal edema of the small bowel that was seen 7 min post injection of non-ionic iodinated contrast material, but was not seen on the unenhanced and venous phase CT. There were no associated inflammatory changes such as mesenteric fat stranding, peritoneal fluid, or lymphadenopathy. Mesenteric vessels showed normal contrast opacification. Bowel edema was seen to have reduced on the 45 min delayed phase scan. The absence of bowel thickening on unenhanced scan and its reduction on 45 min delayed scan distinguish this entity of transient angioedema of small bowel from other pathological conditions causing submucosal bowel wall edema. It has been hypothesized that proximal small bowel is predisposed to angioedema because of its richer blood supply, larger mucosal folds, and loose connective tissue.[2]

Conclusion

Angioedema of the small bowel is rare following intravenous administration of iodinated contrast medium. Characteristic imaging findings such as rapid change in bowel wall thickening not associated with inflammatory changes and follow-up imaging to assess resolution are helpful in distinguishing this entity from other pathological conditions. Treatment is symptomatic. Furthermore, such patients should be evaluated for other associated allergic diathesis and should be carefully monitored when intravenous contrast media are given to them in future.

References

1. Wang CL, Cohan RH, Ellis JH, Caoili EM, Wang G, Francis IR. Frequency, outcome, and appropriateness of treatment of nonionic iodinated contrast media reactions. AJR Am J Roentgenol 2008;191:409-15.
2. Hu, XH, Gong XY, Hu P. Transient small bowel angioedema due to intravenous iodinated contrast media. World J Gastroenterol 2012;18:999-1002.
3. Adapted from the ACR Manual on Contrast Media-Version 9, 2013. Published by the American College of Radiology. Available from: http://www.acr.org/quality-safety/resources/contrast-manual. [Last accessed on 2014 Mar 10].
4. Polger M, Kuhlman JE, Hansen FC 3rd, Fishman EK. Computed tomography of angioedema of small bowel due to reaction to radiographic contrast medium. J Comput Assist Tomogr 1988;12:1044-6.
5. Kim SH, Cho JY, Lim HK. CT findings of isolated small bowel angioedema due to iodinated radiographic contrast medium reaction. Abdom Imaging 1999;24:117-9.
6. Chen CK, Chang HT, Chen CW, Lee RC, Sheu MH, Wu MH, *et al*. Dynamic computed tomography of angioedema of the small bowel induced by iodinated contrast medium: Prompted by coughing-related motion artifact. Clin Imaging 2012;36:386-9.
7. De Backer AI, De Schepper AM, Vandevenne JE, Schoeters P, Michielsen P, Stevens WJ. CT of angioedema of the small bowel. AJR Am J Roentgenol 2001;176:649-52.
8. Macari M, Megibow AJ, Balthazar EJ. A pattern approach to the abnormal small bowel: Observations at MDCT and CT enterography. AJR Am J Roentgenol 2007;188:1344-55.
9. Sinha R, Murphy P, Sanders S, Ramachandran I, Hawker P, Rawat S, *et al*. Diagnostic accuracy of high-resolution MR enterography in Crohn's disease: Comparison with surgical and pathological specimen. Clin Radiol 2013;68:917-27.
10. Sinha R, Rajesh A, Rawat S, Rajiah P, Ramachandran I. Infections and infestations of the gastrointestinal tract. Part 1: Bacterial, viral and fungal infections. Clin Radiol 2012;67:484-94.

Cite this article as: Kulkarni KN, Hegde RG, Balani A, Joshi AR. Transient angioedema of small bowel secondary to intravenous iodinated contrast medium. Indian J Radiol Imaging 2014;24:303-5.

Source of Support: Nil, **Conflict of Interest:** None declared.