Article published online: 2021-08-02

Pseudomalignant myositis ossificans involving multiple masticatory muscles: Imaging evaluation

Muralidhar G Kamalapur, Pritam B Patil, Shyamsundar Joshi, Dinesh Shastri[1]

Departments of Radiodiagnosis and Imaging, and [1]Pathology, SDM College of Medical Sciences and Hospital, Dharwad, Karnataka, India

Correspondence: Dr. Muralidhar G Kamalapur, Departments of Radiodiagnosis and Imaging, SDM College of Medical Sciences and Hospital, Manjushree Nagar, Sattur, Dharwad - 580007, Karnataka, India. E-mail: mgkamalapur@gmail.com

Abstract

Myositis ossificans is a rare cause of trismus. We present a case of pseudomalignant myositis ossificans involving medial pterygoid, lateral pterygoid, and temporalis muscles. Patient presented with gross limitation in mouth opening. There was no history of trauma. Computed tomography (CT) images revealed a bone density mass located in the region of medial and lateral pterygoid muscles on the right and temporalis muscle on the left. Magnetic resonance imaging (MRI) showed similar findings. Radiological diagnosis was pseudomalignant myositis ossificans. The masses were resected and histopathologic examination confirmed the above diagnosis. This report describes the characteristic CT and MRI features. The unique feature of this case is the absence of history of trauma with involvement of multiple masticatory muscles, which, to the best of our knowledge, has not been reported before.

Key words: Pseudomalignant myositis ossificans; pterygoid muscles; temporal muscle

Introduction

Myositis ossificans is a condition associated with heterotrophic bone formation within a muscle. Incidence in the head and neck region is rare and it is usually found in muscles of the extremity.[1] In the head and neck region, involvement of temporalis, masseter, buccinator, platysma, and sternocleidomastoid muscles is known. Fifty-one cases of myositis ossificans traumatica involving the head and neck region have been reported so far. There is a male predominance of 3:1 and masseter is the most commonly affected muscle.[2] To the best of our knowledge, this is a unique case of pseudomalignant myositis ossificans with involvement of multiple masticatory muscles.

Access this article online	
Quick Response Code:	Website: www.ijri.org
	DOI: 10.4103/0971-3026.130706

Case Report

A young woman aged 20 years presented with chief complaints of progressive painful limitation of jaw opening for 4 years. There was no history of trauma to the region. Past medical and family history was noncontributory.

Physical examination revealed a well-nourished woman without obvious developmental abnormalities. Maximal incisal opening (MIO) at presentation was 3 mm. Patient was unable to protrude jaw or produce left lateral excursion. The right lateral excursion was measured at 2 mm. Palpation and auscultation of temporomandibular joints was unremarkable. Palpation of masseter muscle and temporalis muscle was also normal. The occlusion was stable. Intraoral examination was incomplete due to limited mouth opening.

Patient was then advised computed tomography (CT) examination for evaluation of trismus. Axial and coronal CT scans of head and neck were obtained which revealed a high-attenuation mass [1200-1400 Hounsfield units (HU)] seen extending from the right lateral pterygoid plate to the ramus of mandible, replacing the entire medial pterygoid

muscle. Another similar mass was seen extending from the lateral pterygoid plate to condylar neck, involving the lateral pterygoid muscle [Figure 1A-D]. A linear high-attenuation band was seen in the inferior portion of left temporalis muscle connecting with the coronoid process [Figure 1 D and E]. Volume-rendered technique (VRT) showed a bony bar connecting the right lateral pterygoidplate to the ramus of the mandible [Figure 1F]. Magnetic resonance imaging (MRI) of head and neck on a 1.5 T magnet [with axial T1-weighted (T1W), T2-weighted (T2W), coronal T1W, and multiple-echo recombined gradient echo (MERGE) sequences] revealed ahypointense mass extending from the right lateral pterygoid plate to the ramus of mandible; coronal T1W and MERGE images showed a hypointense mass extending from the right lateral pterygoidplate to the condylar neck, involving the lateral pterygoid muscle [Figure 2A-D]. No abnormal hyperintense signals were seen in these regions or in the adjacent soft tissue on T2WI and short T1 inversion recovery (STIR) images. No abnormality was seen in rest of the head and neck on CT and MR images. Bilateral temporomandibular joints were normal on MR images. Laboratory tests that included serum calcium, phosphate, alkaline phosphatase, and parathyroid hormone were within normal limits. Based on CT, MRI, laboratory findings, and clinical history of absence of trauma, a diagnosis of pseudomalignant myositis ossificans involving medial and lateral pterygoid muscles on the right and temporalis muscle on the left was made. Patient underwent surgery for removal of these ossifications.

Histopathology report showed distinct zonal pattern of innermost immature loosely textured richly vascularized fibroblastic zone with mild degree of pleomorphism intermingled with sparse inflammatory cells with fibrinous material and few multinucleated giant cells. An intermediate zone of ill-defined trabeculae and a peripheral zone of osteoid showing calcification and, at places, mature lamellar bone was seen Figure 3A-C. Areas of focal hemorrhage, fibrin, and entrapped muscle fibers were also seen Figure 3D. These findings are consistent with myositis ossificans.

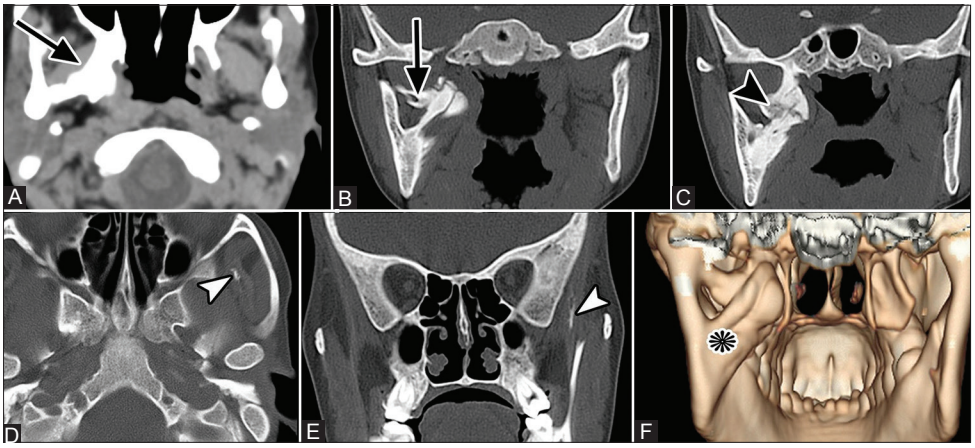

Figure 1 (A-F): (A) Axial and (B) coronal CT reveals a high-attenuating mass (1200-1400 HU) extending from the right pterygoid plate to the condyloid process of mandible replacing lateral pterygoid muscle. Bone window (C) shows a high-density lesion extending from the right pterygoid plate to the ramus of mandible involving medial pterygoid muscle (arrowhead). (D and E) show a linear band of ossification involving the left temporalis muscle inserting into the coronoid process (arrowhead). 3D VRT (F) shows a bony bar connecting the right lateral pterygoid plate to the ramus of the mandible (asterisk)

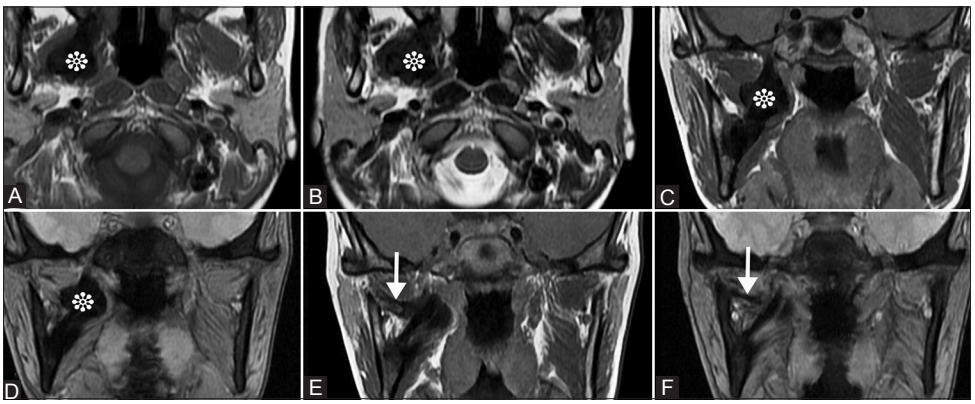

Figure 2 (A-F): MRI - axial T1W (A) T2W (B) coronal T1W (C) and MERGE (D) images show a darkly hypointense mass extending from the lateral pterygoid plate to the ramus of mandible on the right side (asterisk). Coronal T1W (E) and MERGE (F) images show a hypointense band extending from the lateral pterygoid plate to the condylar neck on the right side (arrow)

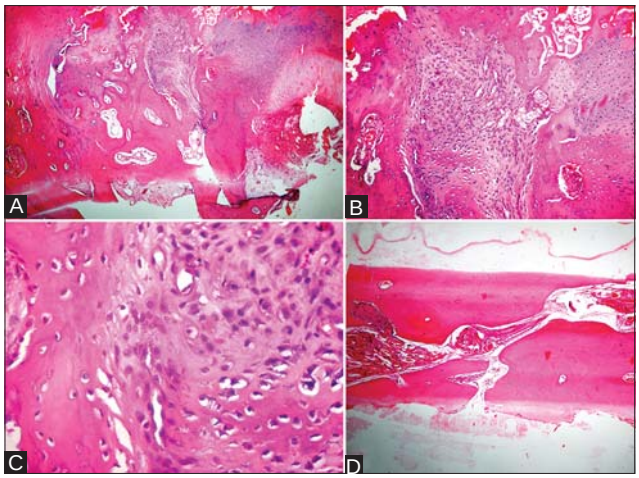

Figure 3 (A-D): Histopathology slide shows distinct zonal pattern of innermost immature loosely textured richly vascularized fibroblastic zone with mild degree of pleomorphism intermingled with sparse inflammatory cells, fibrinous material, and few multinucleated giant cells. An intermediate zone of ill-defined trabaculae and a peripheral zone of osteoid showing calcification and, at places, mature lamellar bone is seen (A-C). Areas of focal hemorrhage, fibrin, and entrapped muscle fibers are also seen (D)

After, surgery patient underwent intensive physiotherapy and maximum spontaneous mouth opening recovered from pre-operative 03 mm to 30 mm.

Discussion

Myositis ossificans is a bone-forming condition within a muscle. Four types of myositis ossificans have been described by Steiner *et al*.[3]

The most common form is myositis ossificans circumscripta which is a localized, self-limiting form secondary to blunt, penetrating, thermal, or iatrogenic trauma. This type is usually seen in the flexor muscles of the upper arm the quadriceps femoris and adductor muscle of the thigh in adolescent and young adults.[4] Involvement of craniofacial muscles is rare. Among the masticatory muscles, masseter is most commonly involved due to its superficial nature and being more prone to trauma.[5] Injury is followed by swelling of the soft tissue, and as the swelling subsides, a painful firm mass starts growing after 1 or 2 months. After a year, the mass gradually becomes small. The second variety is associated with neurological disorders such as closed head or spinal cord injury.[4]

The third type is pseudomalignant myositis ossificans of unknown origin presenting without history of trauma. This type may be confused with malignant tumors.[6] The fourth type is a rare genetic disease called fibrodysplasia ossificans progressiva which is an unusual autosomal dominant inherited disease characterized by congenital malformations and osseous metaplasia of the facial muscles and connective tissue, leading to ossifications. This is fatal and, on an average, death occurs around the age of 35 years.[7] The present case belonged to the third type as there was no history of trauma.

The pathophysiology of myositis ossificans is not clear and several hypotheses have been offered. The most accepted involves exposure of perivascular mesenchymal cells to bone morphogenic proteins. The release of bone morphogenic proteins may be a result of trauma.[8]

Imaging evaluation

Radiographically, lesions can have any of several appearances depending on the maturity. Early lesions appear as amorphous calcifications within soft tissue; mature lesions appear as well-circumscribed lesions with a ring of calcification surrounding a radiolucent central portion and longstanding lesions may appear diffusely calcified.[9] Plain radiographs can only detect signs of ossification after 6-12 months of progression.[7]

CT is very sensitive for identifying calcification and ossification. The pathognomonic appearance is a well-circumscribed high-attenuating periphery with a low-attenuating central portion that mimics a histological zonal architecture. Lesions are generally separated from neighboring native bone by a thin radiolucent cleavage plane; however, older lesions can appear attached to the adjacent bone by a broad calcified stalk.[10] Three-dimensional CT is also very useful for planning surgical treatment.

MRI reveals various characteristics depending on the stage of the lesion. In the early stage, the lesion is usually isointense on T1W images and hyperintense on T2W images. The signal intensity may change depending upon the blood products and surrounding edema, with heterogeneous enhancement also being seen. Hence, myositis ossificans in the early stage may mimic an aggressive soft tissue neoplasm or inflammatory mass. In subacute or intermediate stage, a hypointense border corresponding to peripheral calcification is observed, whereas in the late stage, the intensity is decreased due to dense ossification and fibrosis.[11] The present case was in the late stage as dense ossification was observed.

Ultrasonography(USG) is useful in early superficial lesions and shows presence of soft tissue with a central echogenic zone surrounded by a well-defined hypoechoic zone. These changes are seen 3 months before the calcification can be visualized on conventional radiographs. As the disease progresses, USG reveals hyperechoic nodules.[7] Kirkpatrick *et al*. preferred USG examination in very early cases of suspected myositis ossificans. They stated that techniques such as conventional radiography and CT do not typically disclose characteristic findings before calcification.[12]

Scintigraphy may reveal abundant isotope uptake at the level of ectopic ossification sites at the onset of disease.

Since scintigraphy gives a planar whole body image, known foci of ossification can be monitored and new sites which are undetectable by radiographic examination can be identified.[7]

The differential diagnosis of myositis ossificans includes parosteal or periosteal osteosarcoma, juxtacortical osteoma, osteochondroma, chondroma, chondrosarcoma, and nodular fasciitis.[13] It is important to differentiate this entity form soft tissue osteosarcoma and chondrosarcoma. Soft tissue osteosarcomas are rarely encountered as they are seen in middle-aged and elderly and grow slowly. They are seen in shoulders, thigh, and retroperitoneum. Lesions present as soft tissue masses with calcification or ossification. They have high malignant potential with widespread metastasis to bone. Lesions donot show zonal pattern as seen in myositis ossificans. MRI findings are not specific; lesions may contain cystic, solid, and hemorrhagic contents.[14]

Soft tissue chondrosarcomas are rare. They are divided into myxoid, mesenchymal, and well-differentiated extraskeletalchondrosarcoma based on histology. Myxoid is the most common type seen in themiddle-aged and elderly. The most common locations are thigh and popliteal fossa. Lesions are predominantly located in deep tissues. Myxoid tumors are of low-grade variety but associated with tumor recurrence and distant metastasis. Mesenchymal variety is aggressive and has poor prognosis. Mesenchymal variety shows low signal intensity onT1W and increased signal intensity on T2W and post-contrast sequences. Myxoid variety shows similar changes with variability on T1W sequences.[14]Radiographically, mature bone forms at the periphery of the lesion in myositis ossificans, while foci of ossification are located centrally in osteogenic sarcoma.[15] Osteogenic sarcoma arising in myositis ossificans has been rarely reported.[3] Very rarely, ossifying muscle metastasis from adenocarcinomas involving the esophagus, colon, stomach, and small bowel may mimic myositis ossificans.[16] Wiesenfeld*et al*. reported that in 20% of published cases, there have been diagnostic problems distinguishing a benign from a malignant lesion like osteosarcoma.[6] Histologically, osteoblastic activity is sometimes observed which is similar to osteogenic sarcoma.[2]

Ackerman recognized and described the "zonal phenomena" of histological changes in myositis ossificans. He emphasized that this zonal phenomena permits reorganization of this disease as benign, as this pattern is not typically found in soft tissue sarcoma. Zone 1 represents the central region of lesion, showing mitotic activity, variation in size and shape of the cells, and high level of cellularity. The middle or intermediate zone is considered zone 2, in which immature osteoid formation may be present. Zone 3 is situated at the outer aspect of the lesion and shows mature bone with more collagenous fibrous stroma.[9]

Treatment

In the maxillofacial region, treatment of myositis ossificans is generally surgical excision of the ossified lesion. It is accepted that surgical treatment should not be attempted until the bone mass is mature and the bone scan activity has diminished, usually between 6 and 12 months, so as to prevent recurrence.[17] However, many authors believe that many lesions will regress over time.So, it is recommended that surgery be attempted when the lesion does not regress or it becomes a functional handicap.[5] The secondary effects of post-surgical scarring should not be ignored and intensive physiotherapy should be a part of postoperative care. In addition, disodium etidronate, biphosphonates, nonsteroidal anti-inflammatory drugs, indomethacin, corticosteroid, low-dose radiation, warfarin, and retinoids are the other alternatives attempted in the treatment of myositis ossificans.[5]

Conclusion

Myositis ossificans involving multiple masticatory muscles without history of trauma is a rare entity. Present imaging modalities like CT and MRI can diagnose this condition and may also help in ruling out other differential diagnoses.

References

1. Kruse AL, Dannemann C, Grätz KW. Bilateral myositis ossificans of the masseter muscle after chemoradiotherapy and critical illness neuropathy--report of a rare entity and review of literature. Head Neck oncol 2009;1:30.
2. St -Hilaire H, Weber WD, Ramer M, Lumerman H. Clinicopathologic conference: Trismus following dental treatment.Oral Surg Oral Med Oral Pathol Oral Radiol Endod 2004;98:261-6.
3. Steiner M, Gould AR, Kushner GM, Lutchka B, Flint R. Myositis ossificanstraumatica of the masseter muscle: Review of the literature and report of two additional cases. Oral Surg Oral Med Oral Pathol Oral RadiolEndod 1997;84:703-7.
4. Wang SY, Lomasney LM, Demos TC, Hopkinson WJ. Radiologic case study. Traumatic myositis ossificans. Orthopedics 1999;22:1000,991-5.
5. Kim DD, Lazow SK, Har-El G, Berger JR. Myositis ossificanstraumatica of masticatory musculature: A case report and literature review.J Oral MaxillofacSurg2002;60:1072-6.
6. Wiesenfeld D, Evans FJ, Johnson N. Pseudomalignant osseous tumor of the temporalis muscle. J Oral MaxillofacSurg 1985;43:786-9.
7. Debeney-Bruyerre C, Chikhani L, Lockhart R, Favre-Dauvergne E, Weschler B, Bertrand JC, *et al*. Myositis ossificans progressiva: Five generations where the disease was exclusively limited to the maxillofacial region: A case report. Int J Oral MaxillofacSurg 1998;27:299-302.
8. Arima R, Shiba R, Hayashi T. Traumatic myositis ossificans in the masseter muscle. J Oral MaxillofacSurg 1984;42:521-6.
9. Ackerman LV. Extra-osseous localized non-neoplastic bone and cartilage formation (so-called myositis ossificans): Clinical and pathological confusion with malignant neoplasms. J Bone Joint Surg Am 1958;40-A: 279-98.
10. Dorfman HD. Bone Tumors. St Louis, MO: Mosby; 1998. p. 1120.
11. Kransdorf MJ, Meis JM, Jelinek JS. Myositis ossificans: MR appearance with Radiologic-Pathologic correlation. AJR Am J Roentgenol1991;157:1243-8.

12. Kirkpatrick JS, Koman LA, Rovere GD. The role of ultrasound in the early diagnosis of myositis ossificans. A case report. Am J Sports Med 1987;15:179-81.
13. Stoller WD, TirmanPF, Bredella MA, Beltran S, Branstetter RM, Blease SC.Bone tumors.In: Stoller WD, editor.Diagnostic Imaging Orthopedics. 1st ed. Canada: AmirsysPublishers; 2004. p. 8-2 to 8-34.
14. Resnick D, Kransdorf M. Tumor and tumor like lesions of soft tisues.In: Resnick D, Kransdorf M, editors. Bone and Joint Imaging. 3rd ed. Philadelphia: Elsevier; 2004. p. 1199-244.
15. Kagan AR, Steckel RJ. Diagnostic oncology case studies.Heterotopic new bone formation: Myositis ossificans versus malignant tumor. AJRAm J Roentgenol 1978;130:773-6.
16. Geukens DM, Vande Berg BC, Malghem J, DeNayer P, Galant C, Lecouvet FE. Ossifying muscle metastases from an esophageal adenocarcinoma mimicking myositis ossificans.AJRAm J Roentgenol 2001;176:1165-6.
17. Manzano D, Silván A, Saez J, Moreno JC. Myositis ossificans of the temporalis muscle.Case report. Med Oral PatolOral Cir Bucal 2007;12:E277-80.

Cite this article as: Kamalapur MG, Patil PB, Joshi S, Shastri D. Pseudomalignant myositis ossificans involving multiple masticatory muscles: Imaging evaluation. Indian J Radiol Imaging 2014;24:75-9.

Source of Support: Nil, **Conflict of Interest:** None declared.