Article published online: 2021-08-02

Variations in superior thyroid artery: A selective angiographic study

Pankaj Gupta, Ashu Seith Bhalla, Sanjay Thulkar, Atin Kumar, Bidhu Kalyan Mohanti[1], Alok Thakar[2], Atul Sharma[3]

Departments of Radiodiagnosis, [1]Radiation Oncology, [2]Otorhinolaryngology, and [3]Medical Oncology, All India Institute of Medical Sciences, New Delhi, India

Correspondence: Dr. Ashu Seith Bhalla, Room No. 81, Department of Radiodiagnosis, All India Institute of Medical Sciences, New Delhi - 110 029, India. E-mail: Ashubhalla2@gmail.com

Abstract

Aim: To investigate variations in superior thyroid artery (STA) based on digital subtraction angiography (DSA). **Materials and Methods:** Twenty five angiography studies of 15 pts performed between June 2010 and December 2012 were retrospectively evaluated. These patients underwent DSA of the head and neck region as a part of their superselective neoadjuvant intra-arterial chemotherapy protocol for treatment of laryngeal and hypopharyngeal cancers. Depending upon the location of the tumor, unilateral or bilateral arteriograms of common carotid artery (CCA), external carotid artery (ECA), and STA were performed. Arteriograms were evaluated for the site of origin and branching pattern of STA. STA anatomy was ascribed to one of the three branching patterns. **Results:** A total of 25 angiograms were evaluated, including 14 right and 11 left. On the right side, STA was noted to arise from ECA in 10 (71.5%), bifurcation of CCA in 3 (21.5%), and CCA in 1 (7%) patient. Left STA was seen to arise from ECA in 8 (72.5%), bifurcation of CCA in 2 (18.5%), and internal carotid artery (ICA) in 1 (9%) patient. Type III branching pattern (non-bifurcation, non-trifurcation) was found to be the most frequent (52%). Infrahyoid branch was found to be the most consistent in terms of its origin from STA. **Conclusions:** Origin of STA is predictable, arising from ECA in more than 70% cases. Branching pattern of STA, following origin from ECA, is, however, highly variable. Knowledge concerning the origin and branching pattern of STA is essential in enhancing precision and decreasing morbidity related to the surgical and interventional radiological head and neck procedures.

Key words: Anatomic variations; digital subtraction angiography; superior thyroid artery

Introduction

Superior thyroid artery (STA) is the main arterial supply to the larynx, thyroid gland, muscles (sternocleidomastoid, thyrohyoid, sternothyroid, sternohyoid, omohyoid, and platysma) and the overlying skin. Head and neck surgeons deal with this artery or its branches in a variety of surgical procedures. Neck vasculature, in general, and STA, in particular, is prone to several variations. These variations assume importance in surgical procedures in the neck region, such as radical neck dissection, cricothyroidotomy, diagnostic and therapeutic catheterization, plastic surgery, to name a few. Several autopsy studies have provided an insight into the anatomic variations of STA. However, to the best of our knowledge; no superselective angiographic studies of STA have addressed this issue.[1-4] With the ever-increasing use of angiographic interventions, this knowledge is expected to be of significant clinical impact. As suggested by recent studies, ethnicity plays its part in variations of STA.[5,6] A thorough literature search yielded no angiographic studies of anatomic variation of STA in the Indian population.

We conducted a retrospective study in patients with laryngeal and hypopharyngeal carcinoma who underwent angiography of head and neck and selective angiography of STA during neoadjuvant intra-arterial chemotherapy.

Access this article online	
Quick Response Code:	Website: www.ijri.org
	DOI: 10.4103/0971-3026.130701

Materials and Methods

Study design

To evaluate the role of neoadjuvant intra-arterial chemotherapy in 15 patients with advanced laryngeal and hypopharyngeal cancer, a study was undertaken at our institute from June 2010 to December 2012. The study was approved by the Institutional Ethics Committee and informed consent was taken from all the patients. This protocol comprised digital subtraction angiography (DSA) of the common carotid artery (CCA) and external carotid artery (ECA), followed by identification of STA (as described below) and administration of intra-arterial injections of cisplatin (40 mg/m^2) in two sessions 15 days apart. The response assessment was done using contrast-enhanced computed tomography (CECT) performed at day 25 of the protocol. The present study is a retrospective evaluation of the data, relevant to the subject in discussion (details of the STA anatomy on angiography).

Digital subtraction angiography

Technique of angiography

A brief description of the angiographic technique that was followed during intra-arterial chemotherapy is provided.

After obtaining arterial access through a right femoral artery puncture, CCA and ECA angiograms were obtained in anteroposterior (AP) and lateral projections following hand injection of water-soluble non-ionic contrast (Iomeron®400;Bracco, Milano, Italy). Superselective cannulation of STA followed, using a co-axial system comprising 4F VERT catheter (Slip-Cath® Beacon® Tip Catheter, Cook®, Bloomington, Indiana, USA) and 2.7 F microcatheter (Progreat™, Terumo®; Terumo Corporation, Tokyo, Japan). Continuous saline flush around the microcatheter was employed to prevent thrombus formation. STA anatomy was studied by slow injection of the contrast. The anatomy of STA was evaluated in AP and lateral projections.

Analysis of images

The images were analyzed retrospectively by P.G with 2 years and A.S.B with 15 years of experience respectively in neck angiographyusing commercial workstation (Inturis Viewer Lite Suite; Philips Medical Systems, Veenpluis, Best, Nederland B.V.). The findings recorded included the level of origin of STA and the branching pattern of STA. Five major branches of STA were evaluated including infrahyoid, superior laryngeal, cricothyroid, anterior glandular, and sternomastoid. The smaller glandular branches were not specially sought after. The identification of individual branches was as follows. Infrahyoid artery was identified as the one that traversed along the inferior border of hyoid bone. Vessel showing a downward course toward the larynx from its origin was labeled as superior laryngeal artery. Sternomastoid branch showed a lateral course across the carotid artery. Cricothyroid and anterior glandular branches were identified as those coursing transversely (inferior to infrahyoid artery) and vertically, respectively, along the lateral border of thyroid gland.

Branching patterns were categorized into three types: Type I (bifurcation), type II (trifurcation), and type III (non-bifurcation, non-trifurcation). Type I pattern was defined as the one in which the STA divided to give two major branches with rest of the branches arising from these branches [Figure 1]. Similarly, type II pattern was said to be present when the STA gave three major branches [Figure 2]. In type III pattern, there was random origin of the branches, not conforming to either of the former two patterns [Figure 3].

Results

A total of 25 selective STA angiograms were evaluated in 15 Indian patients. The study population comprised 13 male and 2 female patients. Patients' age ranged from 40 to 69 years with a mean age of 58.1 years.

Visualization of STA origin and its five major branches was possible in all 25 arteriograms. A total of 14 right STA and 11 left STA were evaluated. Of these, bilateral angiograms were performed in 10 patients, right angiogram alone in 4 and left alone in 1 patient. STA on both sides originated most frequently from ECA [Figure 4]. Ten (71.5%) patients had right STA origin from ECA, while 8 (72.5%) patients

Figure 1: Type I branching pattern. Two major branches (arrows) arise from the superior thyroid artery (short arrow)

had left STA origin from ECA. The next most common site of origin of STA was bifurcation of CCA [Figure 3] accounting for 3 (21%) right STA and 2 (18.5%) left STA. Least common sites of origin were CCA (right STA) and internal carotid artery (ICA)[Figure 5] (left STA) accounting for one case each.

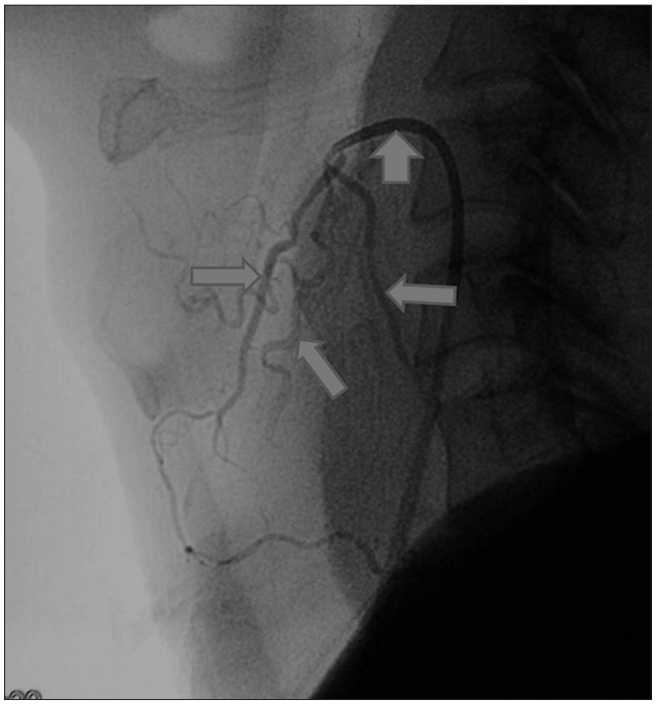

Figure 2: Type II branching pattern. The superior thyroid artery (thick arrow) trifurcates (arrows) close to its origin from ECA

Figure 3: Type III branching pattern and origin of STA from CCA bifurcation. The superior thyroid artery (short arrows) shows no bifurcation or trifurcation following its origin from CCA bifurcation (arrow)

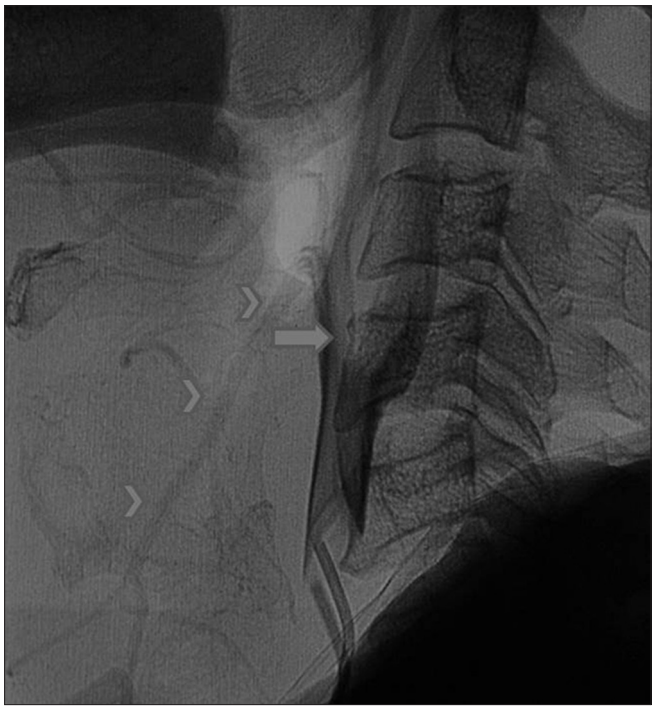

Figure 4: Origin of STA from ECA. The right STA (short arrows) arises from the right ECA (arrow). This represents the most common pattern of origin of STA

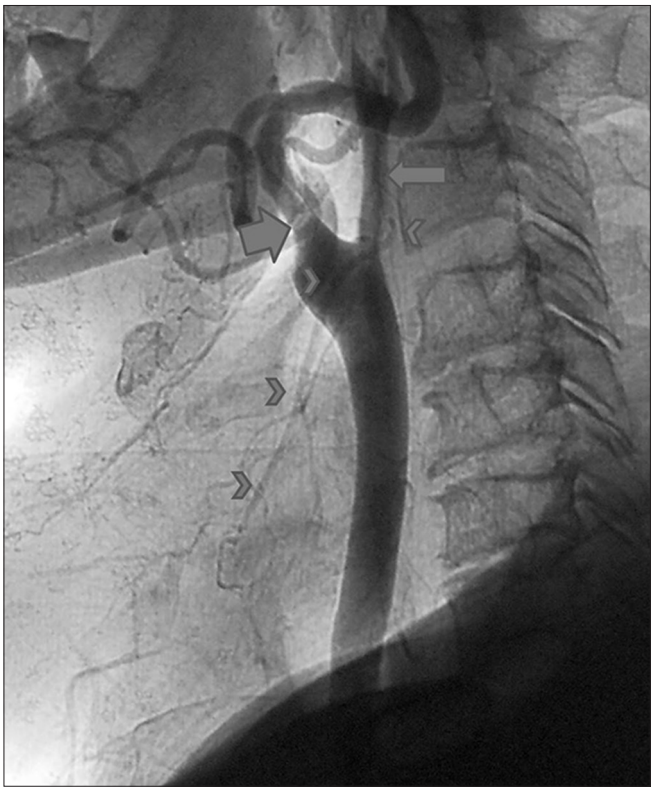

Figure 5: Origin of STA from ICA. The right STA is seen to course anteriorly (short arrows) following its origin from ICA (arrow). ECA is also shown (thick arrow). This is the least common form of origin

Figure 6: Anteromedial course. Anteroposterior selective STA arteriogram reveals the medial course of right STA

Type III branching pattern was most common, noted in 13 (52%) patients. Based on the side, type III pattern was noted in seven cases on the right side and six cases on the left side. Type I pattern was the next most common, noted in 7 (28%) patients (four on the right side and three on the left side). Type II pattern was the least common, seen in 5 (20%) patients (three on the right and two on the left side).

Other observations made in the study included the relationship of STA to ECA and presence of a long common trunk of STA. STA course was categorized as anteromedial and anterolateral after evaluation of both AP and lateral arteriograms. Anteromedial relation [Figure 6] was noted to be more common than anterolateral [Figure 7], with the former noted in 19 STA and the latter in 6 STA. On the right side, 10 arteriograms revealed anteromedial course, while on the left side, 9 arteriograms demonstrated anterolateral course. Anterolateral relation was noted in four cases on the right and one on the left. Long common trunk was considered to be present when there was no branching for the initial 2 cm of the course [Figure 1]. A total of 11 STA revealed long common trunk. Of these, five right and sixleft STA demonstrated the long common trunk. Table 1 shows the salient observations of our study.

Discussion

Considering the surgical importance of STA including its origin and branching pattern, several studies have been performed to explore this issue. Available data have been

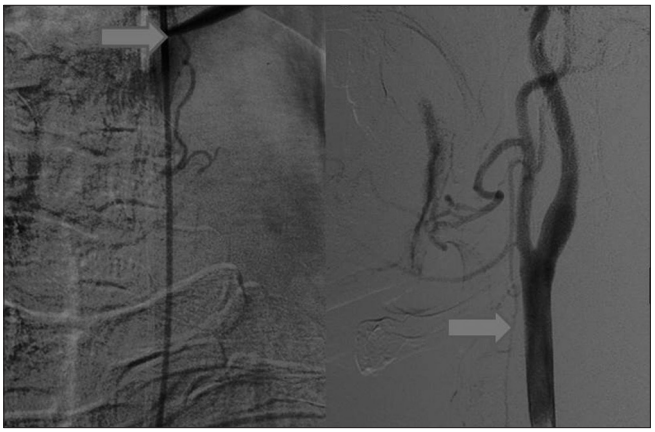

Figure 7: Anterolateral course. Left STA (arrow) is seen to course laterally on this anteroposterior arteriogram. Lateral projection reveals the anterior course of STA (arrow)

Table 1: Important study characteristics

Characteristic	No.
Age (years)	
Range	40-69
Mean	58.1
Sex	
Male	13
Female	2
No. of STA	25
Right	14
Left	11
Origin	
ECA	18
Right	10
Left	8
Bifurcation	5
Right	3
Left	2
ICA	1
Right	0
left	1
CCA	1
Right	1
Left	0
Pattern	
Type I	7
Right	4
Left	3
Type II	5
Right	3
Left	2
Type III	13
Right	7
Left	6

STA: Superior thyroid artery, ECA: External carotid artery, ICA: Internal carotid artery, CCA: Common carotid artery

obtained from autopsy studies.[1,3,4,7,8] Data from angiographic studies are sparse.[7] To the best of our knowledge, none of the selective angiographic studies have addressed STA anatomy. With the increasing use of interventional radiology both in the oncologic and non-oncologic patients, and refined techniques of neck dissection, accurate knowledge of the anatomy of STA assumes significance.

We found that STA originates most commonly from ECA; both right and left STA followed this origin. This is supported by several cadaveric studies,[7] including Indian studies by Sanjeev *et al.* and Anitha *et al.*[8,9] Ozgur *et al.*, however, did not confirm the same.[1] They conducted a study to demonstrate the surgical anatomy of STA in 20 adult Anatolian preserved cadavers between the age of 40 and 70 years. The origin of the STA according to the carotid bifurcation was found to be above (i.e. arising from ECA) (25%), below (35%), and at the same level (40%). This difference could point to the ethnic variations that are also quoted by recent studies.[5,6] We found carotid bifurcation as the second most common site of origin of STA (21.5% on the right and 18.5% on the left side). In a study by Lucev *et al*., the origin of STA from CCA bifurcation was found in 22.5% of cases.[3] Vazquez *et al*.[2] in their autopsy study on 330 heminecks reported CCA bifurcation as the most common site of STA origin (49%). In an Indian study by Anitha *et al.*, STA origin from CCA bifurcation was noted in 19% of cases, figures close to our observation.[9] STA origin from other arteries has been documented in the literature. We noted the origin of STA from ICA and CCA in one patient each. Origin of STA from ICA in the presence of well-developed ECA is extremely rare. Aggarwal *et al*. reported a rare case of variant origin of STA, occipital artery, and ascending pharyngeal artery from the cervical segment of ICA.[10] Compared to origin from ICA, origin from CCA is relatively common and reported by various studies. Adachi *et al*. reported the origin of STA from CCA in 4.7% of STA on the right side, but in 22% of STA on the left side.[11] Lucev *et al*.[3] documented the origin of STA from CCA in 47.5% of cases; Hollinshead *et al*.[12] found the same in 16% cases and Banna *et al*.[4] in 10% cases. Sanjeev *et al*.[8] and Anitha *et al*.,[9] in their study on Indian population, documented the origin of STA from CCA in 35.14% and 21% of cases, respectively. Other rare origins of STA have also been documented in literature. Poynter *et al*. and Livini found the STA origin from SCA in 7% and 9% of cases, respectively.[13,14] Livini observed the common origin of STA, facial and lingual arteries in 1.5% of cadavers.[14] The common origin of STA and lingual artery (thyro-lingual trunk) was observed in 3.5% of cases by Shintani *et al*.[15]

In contrast to the data concerning the origin of STA, only a few studies have addressed the branching pattern of STA. Besides, these classifications were proposed for cadaveric studies. To the best of our knowledge, none of the angiographic studies have focused on the branching pattern of STA. Ozgur *et al*. classified STA into six types depending on the branching pattern.[1] In the most common pattern, the sternomastoid branch divided from ECA and infrahyoid branch represented the first branch from STA, followed by superior laryngeal artery (SLA) and glandular branches. Two patterns that were found to be the second most common (17.5%) included the division of infrahyoid branch and SLA, followed by the sternomastoid artery and the glandular branches; and division of infrahyoid branch followed by trifurcation into SLA, glandular, and sternomastoid branches. In 15% of cases, three patterns were noted: One in which the infrahyoid branch divided followed by sternomastoid artery, SLA, and the glandular branches; in the other group, the SLA originated from the ECA and the sternomastoid artery arose from the SLA; and finally, in yet another subset, infrahyoid branch originated from ECA and SLA divided first followed by sternomastoid artery and glandular branches. Similar branching pattern was reported by Hu *et al*.[16] However, we believe that such a classification is too complicated for use during angiography and propose a simplified classification where the STA branching pattern is classified into three types: Bifurcation, trifurcation, and the third pattern (non-bifurcation, non-trifurcation).

In the present study, no attempt was made to measure the size of the main trunk or branches of STA due both to inherent errors in measuring small branches and the relative ease of catheterization of the branches using the current microcatheter techniques.

Conclusion

The branching pattern of STA is highly variable. Knowledge concerning the origin and branching pattern of STA is essential in enhancing precision and decreasing morbidity related to the surgical and interventional radiological head and neck procedures.

References

1. Ozgur Z, Govsa F, Celik S, Ozgur T. Clinically relevant variation of the superior thyroid artery: An anatomic guide for surgical neck dissection. Surg Radiol Anat 2009;31:151-9.
2. Vazquez T, Cobiella R, Maranillo E, Valderrama FJ, McHanwell S. Anatomic variations of the superior thyroid and superior laryngeal arteries. Head Neck 2009;31:1078-85.
3. Lucev N, Babinac D, Maric I, Drescik I. Variations of the great arteries in the carotid triangle. Otolaryngol Head Neck Surg 2000;122:590-1.
4. Banna M, Lasjaunias P. The arteries of the lingual thyroid: Angiographic findings and anatomic variations. Am J Neuroradiol 1990;11:730-2.
5. Natsis K, Raikos A, Foundos I, Noussios G, Lazaridis N, Njau SN. Superior thyroid artery origin in Caucasian Greeks: A new classification proposal and review of the literature. Clin Anat 2011;24:699-705.
6. Ongeti KW, Ogeng'o JA. Variant origin of the superior thyroid

artery in a Kenyan population. Clin Anat 2012;25:198-202.

7. Toni R, Della Casa C, Castorina S, Malaguti A, Mosca S, Roti E, *et al*. A meta-analysis of superior thyroid artery variations in different human groups and their clinical implications. Ann Anat 2004;186:255-62.
8. Sanjeev IK, Anita H, Aswini M, Mahesh U, Rairam GB. Branching pattern of external carotid artery in humans. J Clin Diagn Res 2010;4:3128-33.
9. Anitha T, Dombe D, Asha K, Kalbande S. Clinically relevant variations of the superior thyroid artery: An anatomic guide for neck surgeries. Int J Pharm Biomed Sci 2011;2:51-4.
10. Aggarwal RN, Krishnamoorthy T, Devasia B, Menon G, Chandrasekhar K. Variant origin of superior thyroid artery, occipital artery and ascending pharyngeal artery from a common trunk from the cervical segment of internal carotid artery. Surg Radiol Anat 2006;28:650-3.
11. Adachi B. The arterial system of Japanese. Vol. 1. Kyoto: Kenkyusha; 1929. p. 58-62.
12. Hollinshead WH. Anatomy for surgeons. Vol. 1. Head and Neck. Hoeber Harper International, Philadelphia: 1966. p. 564-76.
13. Poynter CWM. Congenital anomalies of the arteries and veins of the human bodies with bibliography. The University studies of the University of Nebraska, Lincoln, 1922;22:101-6.
14. Livini studio morfologicadelle arteria tiroidee sperm. Arg Biel Norma Patol 1900;34:42.
15. Shintani S, Terakado N, Alcalde RE, Tomizawa K, Nakayama S, Ueyama Y, *et al*. An anatomical study of the arteries for intra -arterial chemotherapy of Head and Neck cancer. Int J Clin Oncol 1999;4:327-30.
16. Hu KS, Song WC, Kim SH, Choi SW, Han SH, Paik DJ, *et al*. Branching patterns of the arterial branches supplying the middle vascular pedicle of the sternocleidomastoid muscle: A topographic anatomical study with surgical applications for the use of pedicles osteomuscular flaps. Surg Radiol Anat 2006;28:7-12.

Cite this article as: Gupta P, Bhalla AS, Thulkar S, Kumar A, Mohanti BK, Thakar A, *et al*. Variations in superior thyroid artery: A selective angiographic study. Indian J Radiol Imaging 2014;24:66-71.

Source of Support: Nil, **Conflict of Interest:** None declared.