

A rare pleural mucinous cystadenocarcinoma mimicking loculated empyema initially: A case report

Sung Min Moon, Hyun Ju Seon¹, Yoo-Duk Choi², Sang-Yun Song³

Department of Radiology, Chonnam National University Hospital, ¹Department of Radiology, ²Department of Pathology, ³Department of Thoracic and Cardiovascular Surgery, Chonnam National University Medical School, Gwangju, South Korea

Correspondence: Dr. Hyun Ju Seon, Department of Radiology, Chonnam National University Hospital, #8 Hack-dong, Dong-gu, Gwangju-501-757, South Korea. E-mail: seonHJ@jnu.ac.kr

Abstract

We report a case of pleural mucinous cystadenocarcinoma which was mistaken to be a loculated empyema on chest CT. To the best of our knowledge, this entity has never been previously reported in literature.

Key words: Colloid adenocarcinoma; mucinous neoplasm; pleura; pleuropulmonary mucinous cystadenocarcinoma; pulmonary mucinous cystadenocarcinoma

Introduction

Primary pulmonary mucinous cystadenocarcinoma (PMC) is a form of colloid adenocarcinoma of the lung.^[1] It is an extremely rare disease with only 21 cases being reported so far.^[2,3] The cases reported in English literature so far have been intrapulmonary cystic masses. Mucinous cystadenocarcinoma involving the pleura (primary or secondary) has never been reported, to the best of our knowledge.

Case Report

A 35-year-old male presented with upper respiratory symptoms and dyspnea for 3 days, along with right flank pain. He had been smoking for around 10 years. There was no significant past medical history. Laboratory tests showed an elevated white blood cell (WBC)

count of 182,000/mm³ and C-reactive protein (CRP) level of 12.4 mg/dL. Chest radiograph revealed a large soft tissue opacity in the medial aspect of right lower hemithorax. It had smooth lobulated lateral margins whereas the medial margin merged with the mediastinal silhouette [Figure 1A]. Contrast-enhanced chest CT showed a large, well-defined, ovoid, non-enhancing low attenuation lesion with mild peripheral rim-like enhancement in right posterior hemithorax (maximal diameter about 10 × 8 cm). Adjacent to the intrapleural low attenuation lesion, there was peribronchial consolidation in right posterior basal lung containing low attenuation area and fluid bronchogram with focal communication into adjacent pleural space [Figure 1B and C]. Small amount of free pleural effusion was also detected. Neither mediastinal nor hilar lymphadenopathy was detectable. Initial CT diagnosis was a large loculated empyema with adjacent focal necrotizing pneumonia. Insertion of chest tube was performed for the drainage of pleural fluid and the resultant pleural cytology showed malignant cells. With the impression of intrapleural cystic malignancy, patient underwent open thoracotomy with decortication and right lower lobe (RLL) wedge resection. At surgery, a huge gelfoam like mass was found mainly occupying the pleural space in right posterior hemithorax. The specimen including pleural cystic mass and subpleural parenchyma, was of size 10 × 7 × 3 cm. Histologically, most of the tumor was composed of dissecting mucin material. The peripheral portion of the tumor showed mucinous

Access this article online

Quick Response Code:



Website:
www.ijri.org

DOI:
10.4103/0971-3026.125568

epithelial cell nests with stratification and mild nuclear atypia. The mucinous epithelial cells had immunoreactivity for cytokeratin 7 (CK7) [Figure 1D]. Photomicroscopic image revealed the tumor cells in fibrotic tissue. Mucinous material was attached to pleural fibrotic tissue [Figure 1E]. Follow-up chest CT and ^{18}F -fluorodeoxyglucose (FDG) positron emission tomography (PET)-CT were performed a couple of weeks after the operation for the evaluation of residual lesion or extrathoracic primary site of metastasis. Imaging findings revealed remnant subpleural multiloculated cystic lesion in RLL, with postoperative changes along the resection site. There was no evidence of extrathoracic malignancy [Figure 1F]. Patient received four cycles of gemcitabine and cisplatin chemotherapy. But the residual cystic mass in RLL increased on the follow-up chest CT scan after 7 months [Figure 1G]. Reoperation with RLL wedge resection of the growing intrapulmonary cystic mass was done and pathological examination confirmed intrapulmonary mucinous cystadenocarcinoma. In 1 year follow-up after postoperative radiotherapy, the patient is stable.

Discussion

PMC is pulmonary “cystic adenocarcinoma” producing plentiful mucin as in a mucinous cystadenocarcinoma

observed in other organs such as the ovary, breast, and pancreas.^[4] In 1989, Devaney *et al.* first used the term “pulmonary mucinous cystadenocarcinoma.”^[5] The 2004 WHO classification of lung tumors categorizes PMC as a subtype of adenocarcinoma variants.^[6] However, multidisciplinary classification by 2011 International Association for the Study of Lung Cancer/American Thoracic Society/European Respiratory Society for lung adenocarcinoma describes PMC in the category of colloid adenocarcinomas.^[1]

PMC was first described by Gowar as a mucinous cystic neoplasm in 1978.^[7] However, PMC is distinct from other types of pulmonary mucinous neoplasms such as mucinous cystadenoma and mucinous carcinoma.^[8]

Primary PMC is very rare, and there are about 21 reported cases including the most recent report.^[2] However, majority of the prior reported cases are intrapulmonary cystic mass without pleural invasion or metastasis. Pleural mucinous cystadenocarcinoma is extremely rare and has not been reported in literature, to our knowledge. This case presented as a large intrapleural cystic mass with consolidation in adjacent lung parenchyma. The consolidation had internal focal, round, low-attenuated portion communicating with the adjacent pleural space. These findings were

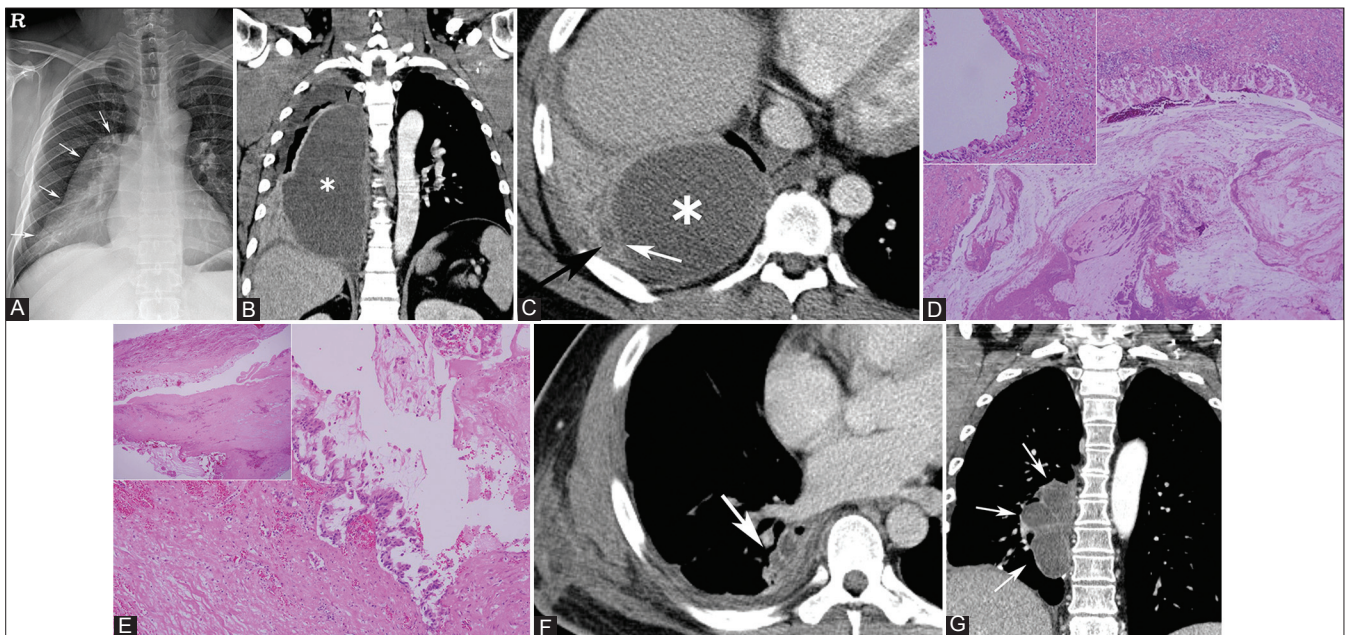


Figure 1 (A-G): 35-year-old male with pleuropulmonary mucinous cystadenocarcinoma. (A) Initial chest radiogram showed a 10 × 13 cm, well-defined, elongated, and lobulated increased opacity (arrows) in the medial aspect of right hemithorax. (B, C) Coronal and axial contrast-enhanced CT images showed large, ovoid, non-enhancing low attenuation lesion (asterisk) in the right posterior hemithorax, with mild peripheral rim-like enhancement. Peribronchial consolidation was noted in adjacent lung parenchyma containing low attenuation area (black arrows in C) with focal communication (white arrows in C) into adjacent pleural space. There was subtle enhancing wall in the superior aspect of the cystic mass separating the mass from the remnant pleural space (arrowhead in B). (D) On histopathologic examination, most of the tumor was composed of dissecting mucin materials. The peripheral portion of the tumor showed mucinous epithelial cell nests with stratification and mild nuclear atypism (inset) (Hematoxylin and Eosin staining). (E) Photomicroscopic image shows the tumor cells in fibrotic tissue. Mucinous material was attached to pleural fibrotic tissue (inset) (Hematoxylin and Eosin staining). (F) Postoperative follow-up CT revealed remnant subpleural multiloculated cystic lesion in RLL. (G) On the last follow-up, residual multiloculated cystic mass with mild septal enhancement in RLL increased

misinterpreted initially as a pleuroparenchymal fistula associated with focal necrotizing pneumonia and a resultant empyema. However, the low attenuated portion can be considered as a mucin-containing, subpleural cystic tumor which had been spilled into the pleural space. It is well known that pleural space has large potential space. This probably allowed the spilled tumor cells to form a large cystic mass in the pleural space. On the other hand, intrapulmonary cystic lesion may be more unlikely to form large mass due to adjacent parenchymal structures.

The large cystic mass was misdiagnosed as a loculated fluid collection with the split pleural sign. However, there were several findings suggesting that it was an intrapleural cystic mass on a retrospective review of the image. First, the pleura in upper hemithorax did not show enhancement. Second, the maximum width of the cystic mass was similar in axial, coronal, and sagittal reformatted images. And third, coronal reformatted image showed thin, enhancing wall separating superior margin of the cystic mass from the pleural effusion in upper hemithorax [Figure 1B].

On follow-up contrast-enhanced CT study after surgery, the lesion in pleural space near-completely resolved without recurrence. On the other hand, remnant lung parenchymal lesion increased and showed as an intraparenchymal lobulated, multiloculated cystic mass. Septa of the cystic mass showed mild contrast enhancement on CT and mild hypermetabolism on FDG PET-CT. These findings were compatible with prior reports of PMC. Imaging finding of PMC is a well-demarcated, multilocular or unilocular, homogeneous, low attenuated or cystic lesion with partial septal or mural enhancement on CT.^[2,8,9] These findings suggest the spillage of malignant cells from primary PMC into the pleural space rather than primary pleural mucinous cystadenocarcinoma with adjacent parenchymal invasion.

The most affected age group of PMC is not established. However, variable age range of 29-75 years has been

reported.^[3] Thus, it seems to involve relatively younger age group than the other adenocarcinomas. Our case was also a relatively young patient of 35 years of age, which made it more difficult to think of a malignant condition.

In conclusion, whenever there is a large cystic space-occupying lesion in the hemithorax, radiologists should include cystic neoplasms in the differential diagnosis, even if they appear benign-looking on imaging.

References

1. Travis WD, Brambilla E, Noguchi M, Nicholson AG, Geisinger KR, Yatabe Y, *et al.* International association for the study of lung cancer/american thoracic society/european respiratory society international multidisciplinary classification of lung adenocarcinoma. *J Thorac Oncol* 2011;6:244-85.
2. Choi YA, Lee HY, Han J, Choi JY, Kim J, Kwon OJ, *et al.* Pulmonary Mucinous Cystadenocarcinoma: Report a Case and Review of CT Findings. *Korean J Radiol* 2013;14:384-8.
3. Iwasaki T, Kawahara K, Nagano T, Nakagawa K. Pulmonary mucinous cystadenocarcinoma: An extremely rare tumor presenting as a cystic lesion of the lung. *Gen Thorac Cardiovasc Surg* 2007;55:143-6.
4. Travis WD, Corrin B, Shimosato Y, Brambilla E. WHO international histology classification of tumours: Histological typing of lung and pleural tumours. Berlin: Springer; 1999. p. 39.
5. Devaney KP, Travis WD. Mucinous cystadenocarcinoma of the lung: A tumor of low malignant potential. *Am J Clin Pathol* 1989;92:254.
6. Beasley MB, Brambilla E, Travis WD. The 2004 World Health Organization classification of lung tumors. *Semin Roentgenol* 2005;40:90-7.
7. Sambrook Gowar FJ. An unusual mucous cyst of the lung. *Thorax* 1978;33:796-9.
8. Chhieng DC. Fine-needle aspiration cytology of pulmonary mucinous cystadenocarcinoma. *Diagn Cytopathol* 2008;36:581-5.
9. Raza SA, Alexakis C, Creagh M, Lawrence DR, Wood M. Primary pulmonary mucinous cystadenocarcinoma presenting as a complex bronchocele: A case report. *J Med Case Rep* 2009;3:8581.

Cite this article as: Moon SM, Seon HJ, Choi Y, Song S. A rare pleural mucinous cystadenocarcinoma mimicking loculated empyema initially: A case report. *Indian J Radiol Imaging* 2013;23:301-3.

Source of Support: Nil, **Conflict of Interest:** None declared.