

HRCT evaluation of microtia: A retrospective study

Aruna R Patil, Ashu Bhalla, Pankaj Gupta, Deepali Goyal, Sreenivas Vishnubhatla¹, Anurag Ramavat², Suresh Sharma²

Departments of Radiodiagnosis, ¹Bio-Statistics, and ²Otorhinolaryngology and Head-Neck Surgery, All India Institute of Medical Sciences, Ansari Nagar, New Delhi, India

Correspondence: Dr. Ashu Seith Bhalla, Department of Radiodiagnosis, All India Institute of Medical Sciences, New Delhi - 110 029, India. E-mail: ashubhalla2@gmail.com

Abstract

Purpose: To determine external, middle, and inner ear abnormalities on high-resolution computed tomography (HRCT) of temporal bone in patients with microtia and to predict anatomic external and middle ear anomalies as well as the degree of functional hearing impairment based on clinical grades of microtia. **Materials and Methods:** It was a retrospective study conducted on Indian population. Fifty-two patients with microtia were evaluated for external, middle, and inner ear anomalies on HRCT of temporal bone. Clinical grading of microtia was done based on criteria proposed by Weerda *et al.* in 37 patients and degree of hearing loss was assessed using pure tone audiometry or brainstem-evoked response in 32 patients. Independent statistical correlations of clinical grades of microtia with both external and middle ear anomalies detected on HRCT and the degree of hearing loss were finally obtained. **Results:** The external, middle, and inner ear anomalies were present in 93.1%, 74.5%, and 2.7% patients, respectively. Combined cartilaginous and bony external auditory canal atresia (EAC) was the most common anatomic abnormality in our group of microtia patients. Hypoplastic mesotympanum represented the commonest middle ear anomaly. The incidence of combined ossicular dysplasia and facial canal anomalies was lower as compared to other population groups; however, we recorded a greater incidence of cholesteatoma. Both these factors can have a substantial impact on outcome of patients planned for surgery. We found no significant association between grades of microtia and external or middle ear anomalies. Similarly, no significant association was found between lower grades of microtia (grade I and II) and degree of hearing loss. However, association between grade III microtia and degree of hearing loss was significant. A significant association between congenital cholesteatoma and degree of pneumatization of atretic plate and mastoid process not previously studied was also recorded in our study.

Key words: External auditory canal, high-resolution computed tomography, microtia, middle ear anomalies, temporal bone

Introduction

Microtia, also called congenital aural atresia, has an incidence of 1.5 in 10,000 to 15,000 with a male predominance.^[1] The condition is bilateral in 15% cases; right side is more commonly involved in unilateral cases.^[1] Microtia comprises anomalies of variable severity

involving pinna, external acoustic canal, middle ear structures, and occasionally inner ear, leading to hearing impairment of varying degrees. Clinically, microtia may be graded based on the morphology of the pinna.^[2] Most patients with microtia have a well-preserved inner ear; however, before a successful recanalization of the atretic external ear is undertaken, knowledge of the middle ear structures including ossicles, facial canal, grade of pneumatization of atretic plate, and mastoid process is required. High-resolution computed tomography (HRCT) of temporal bone is an indispensable preoperative investigation to accomplish this crucial goal.^[3]

The correlation between clinical grades of microtia and degree of hearing loss as well as severity of middle ear abnormalities as seen on HRCT has been reported in

Access this article online

Quick Response Code:



Website:
www.ijri.org

DOI:
10.4103/0971-3026.107181

previous studies with controversial results. Similarly, the degree of hearing loss has not been found to correlate consistently with clinical grade of microtia.^[3-5]

We conducted this study to assess microtia and its association with severity of hearing loss and anatomic abnormalities of ear in Indian population, as no similar study is available in this population to the best of our knowledge. The results were also compared with existing studies, to strengthen the evidence favoring or refuting these associations, in general population.

Materials and Methods

This was a retrospective study comprising of 73 ears in 52 Indian patients with clinical diagnosis of microtia over a period from 2008 to 2011. HRCT temporal bone data of these patients were analyzed. The clinical details regarding the grades of microtia and level of hearing loss (in decibels) were obtained in 37 individuals (55 ears) and 32 individuals (47 ears), respectively. The clinical grading of microtia (grade I-III) was done based on the criteria proposed by Weerda *et al.*^[2] Hearing loss in terms of decibels (dB) was assessed using conventional audiometry and or brainstem-evoked response audiometry.

HRCT temporal bone

The HRCTs of the temporal bone were acquired using either Siemens Sensation 40 or Siemens Sensation 128 slice CT scanner. The images were acquired using 0.6-mm detector collimation in axial plane, parallel to the orbitomeatal line. The parameters used were 120 kV, 80 mA, and 512 × 512 matrix. Coronal and sagittal reformations of 1-mm thickness were obtained for all patients with additional post processing including surface shaded display (SSD) and volume rendered (VRT) images in selected individuals.

Image analysis

Images were viewed using bone algorithm with window width of 4000 HU and window center of 700 HU. The images were analyzed independently by two radiologists (A. S. B. with 15 years and A. R. P. with 5 years experience in the concerned field). In each scan, details regarding the status of external auditory canal (EAC), middle ear size, and its pneumatization, presence or absence of cholesteatoma, status of ossicles, atretic plate, and mastoid pneumatization, facial nerve course, inner ear structures, temporomandibular joint, and other associated anomalies were recorded. Middle ear was considered small if the distance between the promontory and atretic plate was ≤3 mm on coronal plane.^[6]

Statistical analysis

Statistical analysis was done using Stata 11.2 software. The prevalence of associated anomalies in microtia was

expressed as proportions (%) along with 95% confidence intervals. Correlations were done between the clinical grades of microtia and external ear anomalies using trend Chi-square test. The association between grades of microtia and size of mesotympanum (normal or small) and ossicles (normal, dysplastic, or absent) was assessed using a trend Chi-square test. Fisher's exact test was used to study the association of cholesteatoma with the pneumatization patterns of atretic plate and mastoid air cells. Linear regression analysis was used in relating the clinical grading of microtia with the degree of hearing loss. Statistical significance was assumed when $P < 0.05$.

Results

Of the total 52 patients with microtia, 36 were males (male: female ratio 2.3:1; age range: 5 months to 32 years). Bilateralism was seen in 21 patients (40.38%), with right predominance in 56.16% cases. Of the 37 patients (55 ears) in whom microtia grading was obtained, majority had grade II microtia [Table 1].

Table 1: Clinical grading of microtia (n=55)

Clinical grade of microtia	Number of cases
I	7
II	31
III	17

Table 2: Prevalence of associated anomalies in microtia (n=73)

Anomalies	Number	Percentage	95% CI*
External ear	68	93.15	84.74-97.74
Both cartilaginous and bony atresia	60	88.23	
Isolated cartilaginous atresia	4	5.88	
Isolated bony canal atresia	2	2.94	
Stenotic cartilaginous EAC	2	2.94	
Middle ear	51	69.86	58.0-80.06
Small capacity	43	84.31	
Dysplastic ossicles (all three)	38	74.51	
Absent stapes	9	17.65	
Malleoincudal fusion	4	7.84	
Cholesteatoma	28	38.4	
Facial canal anomalies	9	12.33	5.80-22.18
Anterior location	6	8.22	
Canal dilatation	1	1.37	
Close to round window	2	2.74	
Inner ear	2	2.74	0.03-9.54
Cochlear anomalies	2	2.74	
Others			
Aberrant carotid canal	1	1.37	
Absent carotid canal	1	1.37	
High riding jugular bulb	2	2.74	
Bifid mandibular condyle	1	1.37	
IAC narrowing	1	1.37	

Table 2 summarizes the external, middle, inner ear, and other anomalies in 73 ears detected on HRCT of temporal bone.

The overall incidence of external ear anomalies in our study was 93.15%. Of the 73 ears, 60 had absence of both cartilaginous and bony EAC [Figure 1A, B]. Isolated cartilaginous or bony atresia was found in four and two ears, respectively. Two ears had stenotic cartilaginous part [Figure 1C, D]. Tympanic membrane was absent in 59 ears. There was no significant association between the clinical grading of microtia and the occurrence of EAC anomalies.

Small capacity mesotympanum was the most common middle ear anomaly found in 84.3% patients [Figure 2A]. The commonest ossicular abnormality was dysplasia involving the entire ossicular chain noticed in 74.51% patients [Figure 2B]. Cholesteatoma was present in 38.4% patients. Absent stapes was more common (17.65%) than malleoincudal fusion (7.84%) [Figure 2C and D]. Like for external ear, no significant association was found between clinical grading of microtia and various middle ear

abnormalities [Table 3].

Facial canal abnormalities were present in 12.33% patients, with anteriorly displaced facial canal [Figure 3A and B] being the commonest. Facial canal very closely related to the round window [Figure 3C], and dilated canals were less commonly encountered.

Internal auditory canal (IAC) narrowing was seen in one ear [Figure 4A, B]. Cochlear anomalies were seen in two ears in which there were decreased turns of cochlea producing a bulbous appearance [Figure 4C, D]. No round window, oval window, or semicircular canal abnormalities were seen in our study.

Vascular anomalies in our study included one case each of aberrant carotid artery course [Figure 5A, B] and absent carotid canal [Figure 5C] and two ears with high-riding jugular bulb [Figure 5D].

One case of bifid mandibular condyle was also documented [Figure 6A, B].

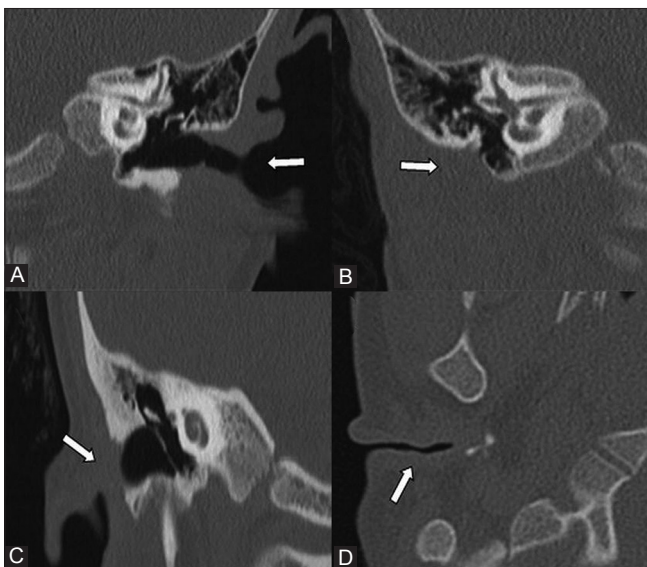


Figure 1 (A-D): EAC anomalies. (A) Coronal HRCT shows EAC with cartilaginous and bony component in a normal ear (arrow). (B) Coronal HRCT of grade I microtia shows combined cartilaginous and bony EAC atresia (arrow). (C) Coronal HRCT shows isolated atresia of cartilaginous EAC (arrow). (D) Axial HRCT section shows stenotic cartilaginous EAC (arrow)

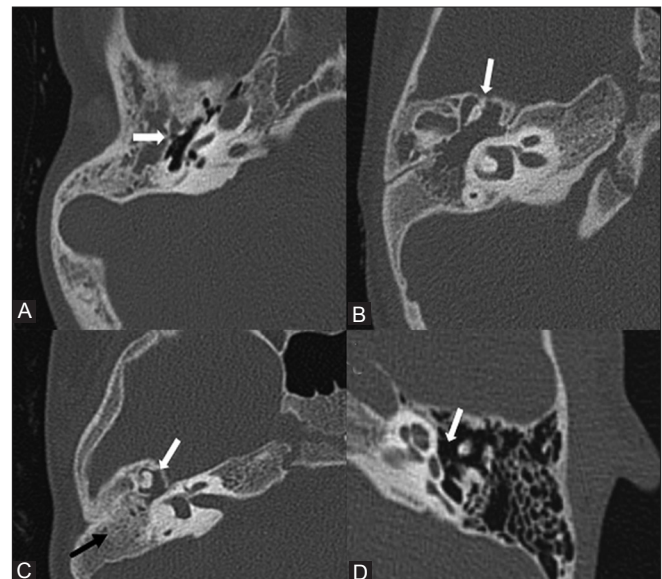


Figure 2 (A-D): Middle ear anomalies. (A) Axial HRCT section shows small capacity middle ear (arrow). (B) Axial HRCT section shows dysplastic malleus and incus. Also note an associated cholesteatoma. (C) Axial HRCT section shows incudomalleal ankylosis (white arrow). Also seen is non-pneumatized atretic plate (black arrow). (D) Axial HRCT section in microtia shows normal stapes

Table 3: Middle ear size and ossicular status related to grades of microtia (n=55)

Grade of microtia	Middle ear size (%)		Malleus (%)		Incus (%)		Stapes (%)	
	Normal	Small	Normal	Dysplastic	Normal	Dysplastic	Normal	Dysplastic/absent
I (n=6)	5 (83.3)	1 (16.7)	4 (66.7)	2 (33.3)	4 (66.7)	2 (33.3)	4 (66.7)	2 (33.3)
II (n=32)	12 (37.5)	20 (62.5)	9 (28.1)	23 (71.9)	9 (28.1)	23 (71.9)	11 (34.4)	21 (65.6)
III (n=17)	6 (35.3)	11 (64.7)	6 (35.3)	11 (64.7)	6 (35.3)	11 (64.7)	5 (29.4)	12 (70.6)
P value	0.11		0.41		0.41		0.18	

Table 5 shows the relation between the clinical grading of microtia and the degree of hearing loss in decibels. The mean hearing loss in microtia grade I, II, and III was 21.2, 36.2, and 44.4 dB, respectively. Degree of hearing loss showed significant association only with the highest grade (grade III) microtia. Similar association was not reproducible for lower grades of microtia. However, there was a significant correlation ($P < 0.0001$) [Table 4] between the occurrence of cholesteatoma and poor mastoid and atretic plate pneumatization [Figures 7, 8].

Comparison of our results with previous studies is tabulated in Table 6.

Discussion

Microtia is commonly associated with external and middle ear anomalies. Inner ear abnormalities are less consistent. The external and middle ear develop from first and second branchial arches. First arch contributes to incus, malleus, tensor tympani muscle, and mandible, and second arch to stapes, facial nerve canal, stapedius muscle, and the styloid process. Disorders of the first and second branchial arches

also result in dysplasia of the auricular cartilage, leading to microtia in the 7th to 8th week, hence an association of microtia with anomalies of EAC and middle ear. Temporal bone HRCT is the investigation of choice for delineating these abnormalities. Anatomic abnormalities of the ear in microtia have been reported previously using HRCT imaging of temporal bone, but there is lack of such data for the Indian population.

EAC atresia is commonly associated with microtia and usually presents as combined cartilaginous and bony atresia. Isolated cartilaginous or bony canal atresia, which was considered rare, had an incidence of 8.82% in our study. Surgical reconstruction of the EAC and ossicular chain is much easier when the EAC is present, even when it is very narrow and tortuous, because this acts as a landmark to help the surgeon reach the tympanic cavity more safely.^[7] Our study provides an incidence of EAC abnormalities in

Table 4: Association between cholesteatoma with mastoid and atretic plate pneumatization

Region of pneumatization	Status	Cholesteatoma		P value
		Present (%)	Absent (%)	
Mastoid pneumatization	Normal	2 (7.7)	24 (92.3)	<0.001
	Poor	26 (55.3)	21 (44.7)	
Atretic plate pneumatisation	Normal	1 (4.2)	23 (95.8)	<0.001
	Poor	27 (55.1)	22 (44.9)	

Table 5: Grades of microtia correlated with mean hearing loss in dB (n=55)

Grade	Mean hearing loss in dB (±SD)	Median (dB)	P value
I	21.2±21.4	15	-
II	36.2±12.5	40	0.02
III	44.3±6.0	45	<0.01

Table 6: Comparison with previous studies

Study	Number of patients/ ears	Anomalies in microtia (%)								Correlation between microtia grade and		
		EAC dysplasia	Ossicular dysplasia of stapes	Dysplasia of ear	Inner ear	Facial canal changes	Vascular changes	Oval/round window	CS	Hearing loss	Ossicle dysplasia	CS and Mastoid and atretic plate areation
Kountakis et al., 1995	224 ears	NS	NS	NS	NS	NS	NS	NS	24%	NS	Yes	NS
Siebert et al., 1996	71 patients, 142 ears	NS	97%	70%	16%	75%	NS	32%, 7%	NS	NS	No	NS
Mayer et al., 1997	92 patients	NS	98%	72%	13%	75%	38%	36%, 6%	NS	NS	Yes	NS
Ishimoto et al., 2005	109 patients, 142 ears	NS	NS	NS	NS	NS	NS	NS	NS	NS	No	NS
Ishimoto et al., 2007	89 patients, 115 ears	NS	NS	NS	NS	NS	NS	NS	NS	NS	No	NS
Jin et al., 2010	208 patients	NS	NS	NS	NS	NS	NS	NS	7.2%	Yes	NS	NS
Our study, 2011	55 patients, 73 ears	93.2%	74.5%	74.5%	2.7%	12.3%	5.5%	None	38.4%	Yes	No	Yes

CS: Cholesteatoma; NS: Not specified

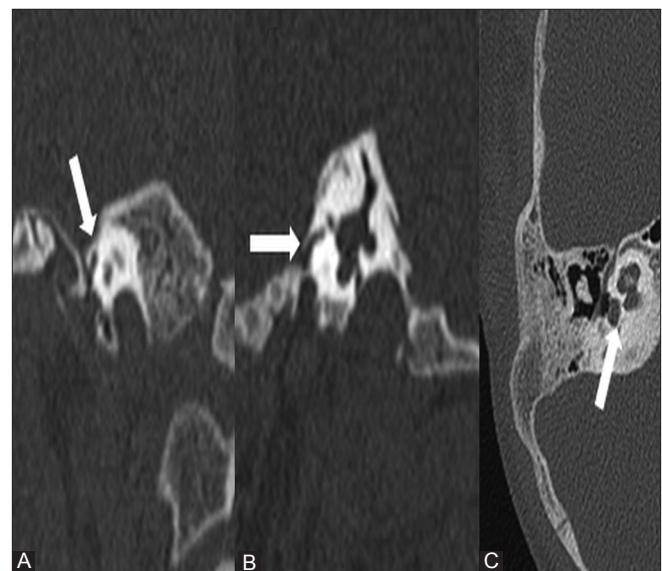

Figure 3 (A-C): Facial canal anomalies. (A) Coronal HRCT section shows anterior location of facial canal (arrow). Also note the shortened vertical course of the nerve. (B) Sagittal HRCT section of same patient shows similar findings (arrow). (C) Axial HRCT section shows intimate course of facial nerve to the round window (arrow)

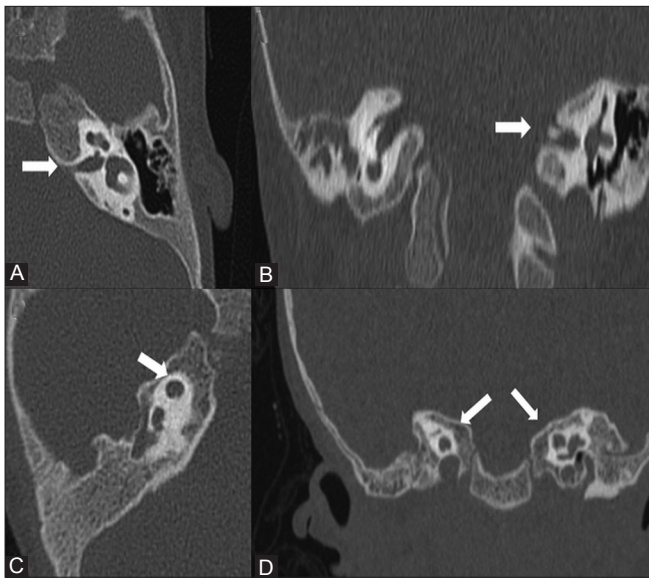


Figure 4 (A-D): Inner ear anomalies. (A) Axial HRCT section shows narrowed left internal acoustic meatus (arrow). (B) Coronal HRCT of same patient shows similar finding. Note normal right IAC. (C) Axial HRCT section shows globular cochlea (arrow) with dysplastic modiolus. (D) Coronal HRCT of same patient shows bilateralism of cochlear dysplasia (arrows)

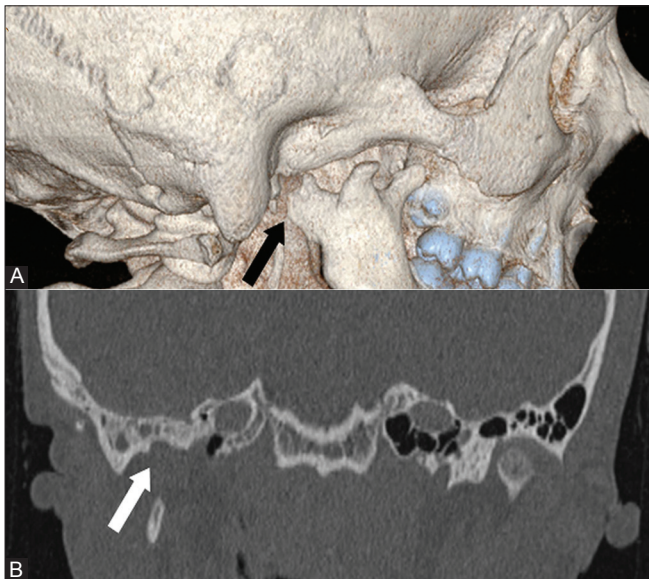


Figure 6 (A, B): Mandibular condyle anomaly. (A) Volume rendered image shows bifid right mandibular condyle (arrow). (B) Coronal HRCT section of same patient shows double temporal articular fossa on right side (arrow)

microtia, a parameter detailed in none of the published studies.

Small capacity middle ear was seen in 84.3% cases in our study. Reduced middle ear space correlates with unfavorable surgical outcome.^[8] A tympanic cavity width <3 mm from the promontory to the atretic plate in the coronal plane is considered inadequate for reconstruction.^[6] Middle ear ossicles show variable anomalies ranging from absence,

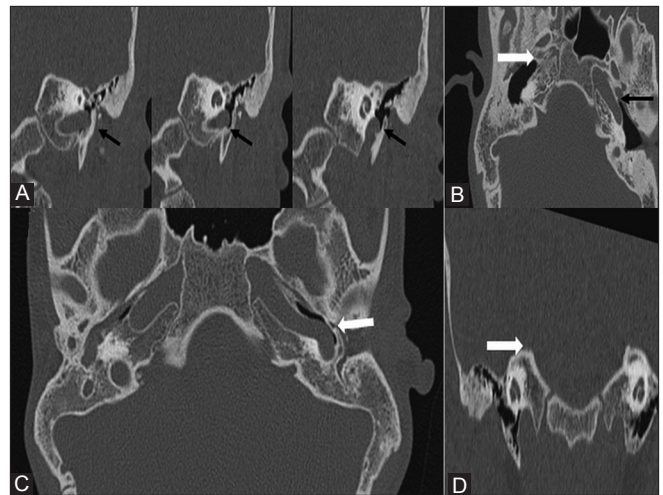


Figure 5 (A-D): Vascular anomalies. (A) Serial coronal HRCT sections shows aberrant course of left internal carotid artery in the middle ear (black arrows). (B) Axial section of same patient shows similar finding (arrow). (C) Axial HRCT section shows absent carotid canal on right side (white arrow). Note the normal carotid canal on left side (black arrow). (D) Coronal HRCT section shows high riding jugular bulb on right side (arrow)

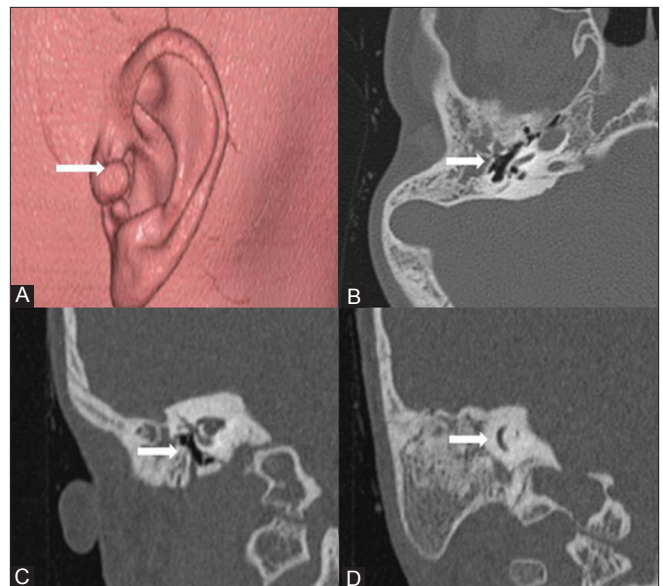


Figure 7 (A-D): A 17-year-old male with grade I microtia on the right side. (A) Volume rendered image shows grade I microtia. There is preservation of helix with preauricular tag (arrow). (B) Axial HRCT section shows small capacity middle ear with dysplastic ossicles (arrow). (C) Coronal HRCT section of same patient shows similar findings (arrow). (D) Coronal HRCT section also depicts non-pneumatized atretic plate with normal inner ear (arrow)

dysplasia, ossicles embedded in the atretic plate, and fusion abnormalities involving malleus and incus. We reported an incidence of combined ossicular dysplasia of 74.5% that is significantly lower as compared to previously reported values of more than 95%.^[9,10] However, the incidence of stapes dysplasia in our study population (74.5%) matched with the previously documented results.

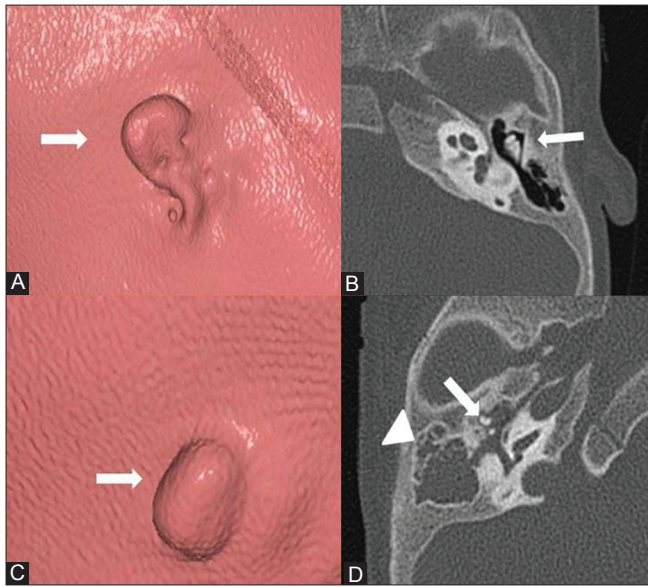


Figure 8 (A-D): A 2-year-old male child with bilateral grade III microtia. (A) Volume rendered image shows left-sided grade III microtia, with bud like pinna (arrow). (B) Axial HRCT section of same side shows preserved middle ear capacity, pneumatization, and ossicles (arrow). (C) Volume rendered image shows right sided grade III microtia (arrow). (D) Axial HRCT section of right side shows small middle ear and dysplastic ossicles (arrow). Also noted is associated cholesteatoma (arrowhead)

Atretic plate refers to the bony plate that separates the undeveloped external ear from the middle ear. Of the two commonly used surgical approaches, transmastoid and anterior, the latter involves drilling of the atretic plate. Hence, information regarding the pneumatization and thickness of the atretic plate is an important prerequisite in guiding the surgeon. We found a significant correlation between pneumatization of mastoid process and that of the atretic plate, similar to that documented in a study by Grassner, *et al.*^[6]

Congenital cholesteatoma is commonly associated with microtia. Presence of soft tissue in the middle ear points to its presence. Our study showed a higher occurrence (38.4%) of cholesteatoma compared to previous studies.^[4,11] There was a significant association between the presence of cholesteatoma and poor mastoid and atretic plate pneumatization. None of the previous studies, to our knowledge, have documented this association.

Facial nerve injury is the most substantial complication of microtia surgery. Thus, it is essential to determine the course of the facial nerve preoperatively. In patients with microtia, the facial canal tends to show an anterolateral displacement of its course, exposing it to the risk of injury during mastoid drilling.^[12,13] Such aberrant anatomy of facial canal was found in 8.22% of our patients, which is lower as compared to that in previous studies.

The inner ear anomalies in microtia have a reported incidence of 10-52%.^[14] We found a much lower incidence (2.7%) with

one patient having bilateral cochlear dysplasia. Patients with an atretic oval window are not considered candidates for surgical repair. However, we encountered no round or oval window atresia in our study. These results are in consort with a different embryological origin of inner ear.

Aplasia or hypoplasia of the tympanic part or mastoid process of the temporal bone, mandibular condyle, and zygomatic arch is also associated with microtia.^[10] Bifid mandibular condyle is a rare association with an incidence of 0.5%.^[15,16] We documented one case of bifid mandibular condyle in our study (1.37%). It is thought to be developmental and is due to presence of fibrous septum or vascular structure impeding the fusion of condylar ossification center. IAC anomalies can range from mild asymmetry and narrowing to replacement by thin neural canal.^[10] One case of IAC narrowing was documented in our study.

Carotid canal anomalies are not uncommon in the setting of microtia.^[17] Aberrant course of carotid artery in mesotympanum confers surgical risk. Absent carotid canal is usually unilateral and can be associated with persistent stapedia artery. High riding jugular bulb is an uncommon association with microtia. Vascular anomalies in our study showed an overall incidence of 5.5%.

Our study did show increasing trend of small mesotympanum and stapes dysplasia with increasing microtia grades; however, with no statistical significance. The small sample size of our study could be the reason for this result. No association could be derived between the EAC anomalies and grades of microtia. We have documented a significant association between cholesteatoma occurrence with poor mastoid and atretic plate pneumatization. This can be explained by the anatomic continuity of mastoid with the middle ear and the common factors affecting their pneumatization. The linear regression tests showed significant increase in degree of hearing loss with worsening microtia grades.

Thus, we conclude that a wide range of anatomic abnormalities are present in the external and middle ear in patients with microtia. Preoperative assessment of these as well as other abnormalities including atretic plate pneumatization and aberrant facial and carotid canal with HRCT imaging of temporal bone plays an important role in planning appropriate management. However, it may not be possible to predict these abnormalities based on microtia grades, thus emphasizing the importance of imaging in all patients regardless of the clinical grade of microtia.

References

1. Mastroiacovo P, Corchia C, Botto LD, Lanni R, Zampino G, Fusco D. Epidemiology and genetics of microtia-anotia: A registry based study on over one million births. *J Med Genet* 1995;32:453-7.

2. Weerda H. Classification of congenital deformities of the auricle. *Fac Plast Surg* 1988;5:385-8.
3. Jahrsdoerfer RA, Yeakley JW, Aguilar EA, Cole RR, Gray LC. Grading system for the selection of patients with congenital aural atresia. *Am J Otol* 1992;13:6-12.
4. Jin L, Hao S, Fu Y, Zhang T, Wang Z. Clinical analysis based on 208 patients with microtia (especially reviewed oculo-auriculo-vertebral spectrum, hearing test, CT scan). *Turk J Pediatr* 2010;52:582-7.
5. Ishimoto S, Ito K, Karino S, Takegoshi H, Kaga K, Yamasoba T. Hearing levels in patients with microtia: Correlation with temporal bone malformation. *Laryngoscope* 2007;117:461-5.
6. Gassner EM, Mallouhi A, Jaschke WR. Preoperative evaluation of external auditory canal atresia on high-resolution CT. *AJR Am J Roentgenol* 2004;182:1305-12.
7. Ishimoto S, Ito K, Yamasoba T, Kondo K, Karino S, Takegoshi H, *et al.* Correlation between microtia and temporal bone malformation evaluated using grading systems. *Arch Otolaryngol Head Neck Surg* 2005;131:326-9.
8. Yeakley JW, Jahrsdoerfer RA. CT evaluation of congenital aural atresia: What the radiologist and the surgeon need to know. *J Comput Assist Tomogr* 1996;20:724-31.
9. Siegert R, Weerda H, Mayer T, Brückmann H. High resolution computerized tomography of middle ear abnormalities. *Laryngorhinotologie* 1996;75:187-94.
10. Mayer TE, Brueckmann H, Siegert R, Witt A, Weerda H. High-Resolution CT of the temporal bone in dysplasia of the auricle and external auditory canal. *AJNR Am J Neuroradiol* 1997;18:53-65.
11. Kountakis SE, Helidonis E, Jahrsdoerfer RA. Microtia grade as an indicator of middle ear development in aural atresia. *Arch Otolaryngol Head Neck Surg* 1995;121:885-6.
12. Takegoshi H, Kaga K. Difference in facial canal anatomy in terms of severity of microtia and deformity of middle ear in patients with microtia. *Laryngoscope* 2003;113:635-9.
13. Takegoshi H, Kaga K, Chihara Y. Facial canal anatomy in patients with mandibulofacial dysostosis: Comparison with respect to the severities of microtia and middle ear deformity. *Otol Neurotol* 2005;26:803-8.
14. Swartz JD, Faerber EN. Congenital malformations of the external and middle ear: High-resolution CT findings of surgical importance. *AJNR Am J Roentgenol* 1985;144:501-6.
15. Shriki J, Lev R, Wong BF, Sundine MJ, Hasso AN. Bifid mandibular condyle: CT and MR imaging appearance in two patients: Case report and review of the literature. *AJNR Am J Neuroradiol* 2005;26:1865-8.
16. Szentpetery A, Kocsis G, Marcsik A. The problem of the bifid mandibular condyle. *J Oral Maxillofac Surg* 1990;48:1254-7.
17. Given CA 2nd, Huang-Hellinger F, Bakera MD, Chepuria NB, Morrisa PP. Congenital absence of the internal carotid artery: Case reports and review of the collateral circulation. *AJNR Am J Neuroradiol* 2001;22:1953-9.

Cite this article as: Patil AR, Bhalla A, Gupta P, Goyal D, Vishnubhatla S, Ramavat A, *et al.* HRCT evaluation of microtia: A retrospective study. *Indian J Radiol Imaging* 2012;22:188-94.

Source of Support: Nil, **Conflict of Interest:** None declared.

Author Help: Reference checking facility

The manuscript system (www.journalonweb.com) allows the authors to check and verify the accuracy and style of references. The tool checks the references with PubMed as per a predefined style. Authors are encouraged to use this facility, before submitting articles to the journal.

- The style as well as bibliographic elements should be 100% accurate, to help get the references verified from the system. Even a single spelling error or addition of issue number/month of publication will lead to an error when verifying the reference.
- Example of a correct style
Sheahan P, O'leary G, Lee G, Fitzgibbon J. Cystic cervical metastases: Incidence and diagnosis using fine needle aspiration biopsy. *Otolaryngol Head Neck Surg* 2002;127:294-8.
- Only the references from journals indexed in PubMed will be checked.
- Enter each reference in new line, without a serial number.
- Add up to a maximum of 15 references at a time.
- If the reference is correct for its bibliographic elements and punctuations, it will be shown as CORRECT and a link to the correct article in PubMed will be given.
- If any of the bibliographic elements are missing, incorrect or extra (such as issue number), it will be shown as INCORRECT and link to possible articles in PubMed will be given.