

Original Article

Limb salvage with microvascular free fibula following primary bone sarcoma resection

Sahasrabudhe Parag, Panchwagh Yogesh¹, Jesal Rathod¹, Panse Nikhil, Jadhav Amit¹

Department of Plastic Surgery, B.J. Government Medical College and Sassoon General Hospitals, ¹Department of Plastic Surgery, Deenanath Hospital, Pune, Maharashtra, India

Address for correspondence: Dr. Sahasrabudhe Parag, Plot No. 82, Lane No. 2, Natraj Society Karvenagar, Pune - 411 052, Maharashtra, India. E-mail: drparags@gmail.com

ABSTRACT

Background: Extremity sarcomas are challenging to manage. Total eradication of tumour has to be balanced with restoration of limb function to prevent mortality and morbidity. Disease-free survival with maximum limb function is the ultimate goal in these patients. **Materials and Methods:** We present a series of ten cases of extremity malignancies, where limb salvage was attempted with microvascular free fibula for limb reconstruction from the period of 2008 to 2015. **Results:** Of the ten cases in the study, there were two females and eight males. There were nine patients with lower limb malignancies and one patient with upper limb malignancy. There were four patients with Ewing's sarcoma of femur, five patients with osteosarcoma of femur and one patient with chondrosarcoma of the humerus. The follow-up period ranged from 1.2 to 6.2 years with mean follow-up of 3.1 years. There were two deaths during follow-up, both were due to distant metastasis. The assessment of the function was done on the basis of Musculoskeletal Tumour Society functional score. Maximum score was 30 and minimum score was 24, the average score being 26. Of the eight surviving patients, three patients had full weightbearing, four patients had partial weightbearing at end of 2 years and one patient of upper limb reconstruction had complete upper limb function. None of the patients had to undergo limb amputation. **Conclusion:** Limb salvage with vascularised fibula graft offers good functional outcome along with good disease-free survival rates.

KEY WORDS

Bone sarcoma; limb salvage; vascularised fibula flap

INTRODUCTION

In the era of microvascular surgery, the treatment of osteogenic malignancies has been shifting from amputation towards limb-sparing procedures. Before

1970s, management routinely consisted of trans bone amputation or disarticulations, with dismal survival rates (10%–20%).^[1] With the development of more effective chemotherapy, radiation therapy and multimodality

Access this article online	
Quick Response Code: 	Website: www.ijps.org
	DOI: 10.4103/0970-0358.197244

This is an open access article distributed under the terms of the Creative Commons Attribution-NonCommercial-ShareAlike 3.0 License, which allows others to remix, tweak, and build upon the work non-commercially, as long as the author is credited and the new creations are licensed under the identical terms.

For reprints contact: reprints@medknow.com

How to cite this article: Parag S, Yogesh P, Rathod J, Nikhil P, Amit J. Limb salvage with microvascular free fibula following primary bone sarcoma resection. *Indian J Plast Surg* 2016;49:370-7.

therapy, the treatment protocol shifted towards limb preservation.

An intercalary reconstruction is defined as replacement of the diaphyseal portion of a long bone after segmental skeletal resection.^[2] After a wide resection, a large skeletal defect is created. It requires reconstruction and bridging of the defect with either megaprosthesis or a vascularised bone graft if limb salvage is planned.

Megaprosthesis is a large metallic joint design to replace the excised length of bone and adjacent joint. These megaprotheses allow for movement of the joint, providing both mobility and stability.^[3]

Another approach to limb salvage has been described by Capanna *et al.*^[4] This technique combines a vascularised fibula graft with a conventional massive allograft to reconstruct large defects after oncologic resection.

Amongst vascularised bone grafts, fibula graft is the most common and preferred graft as it is capable of filling the large defect created following the resection.^[5] We have reviewed a series of ten patients who underwent oncologic limb salvage resection for primary bone sarcoma of extremities and were reconstructed by vascularised fibula graft. We assessed the function post-operatively using Musculoskeletal Tumour Society (MSTS) score at the end of 2 years.

MATERIALS AND METHODS

The present study is a single centre, retrospective study of patients with various types of bone sarcomas which were reconstructed with vascularised free fibula graft after resection. The study was conducted in our institute from the period of January 2008 to December 2015. Detailed record of all patients' demographic profile, disease staging, treatment plan, adjuvant therapy and follow-up was maintained.

Surgical technique

In all cases, the harvest of the free fibula was done from the contralateral limb to that of the limb with the tumour [Figures 1-3]. The procedure was undertaken by two-team approach.

Suitable artery and vein were preserved for the anastomosis [Table 1]. Wide local excision of the tumour with sparing of joints was done with adequate margins.

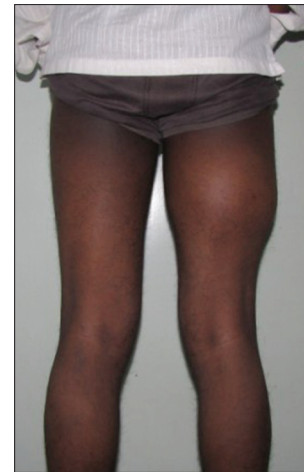

Figure 1: Patient with right femur osteosarcoma

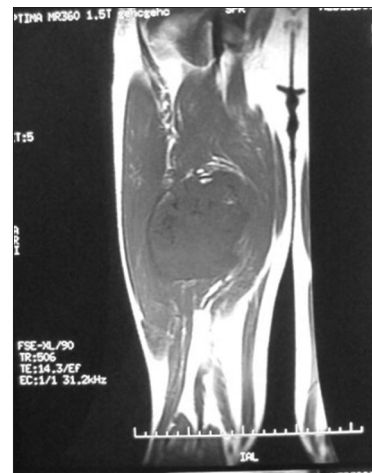

Figure 2: Magnetic resonance imaging of the right femur showing the tumour

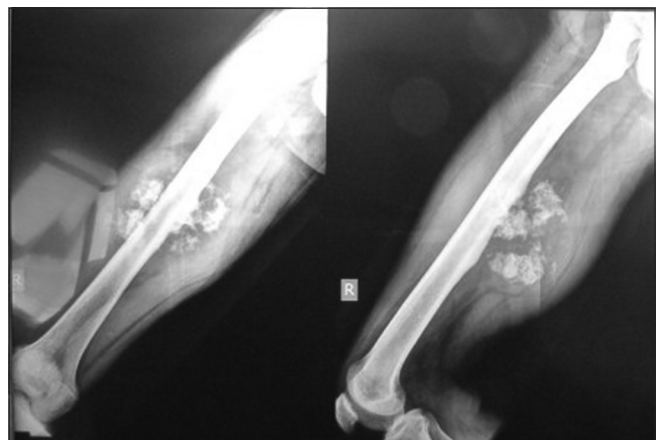

Figure 3: X-ray of the femur showing the tumour

The proximal and distal marrow was sent for frozen section examination and was confirmed to be free of disease. Scoring of the two ends of the bone as a marker was done before the osteotomy so as to prevent any rotational deformity.

Table 1: Fibula orientation and choice of vessels

Patient number	Fibula orientation	Choice of vessel for anastomosis
1	Antegrade	Femoral artery and vein end to side
2	Antegrade	Profunda femoris artery and vein
3	Antegrade	Lateral circumflex femoral artery and vein
4	Antegrade	Profunda femoris artery and vein
5	Antegrade	Anterior tibial vessels
6	Antegrade	Profunda femoris artery and vein
7	Antegrade	Profunda femoris artery and vein
8	Antegrade	Profunda femoris artery and vein
9	Antegrade	Anterior tibial vessels
10	Antegrade	Brachial artery and cephalic vein

The resected bone was stripped of all soft tissues and periosteum and then sent for extracorporeal radiotherapy (ECRT). ECRT was given with a dose of 50 cGy at a rate of 1.8–2.0 cGy/min. The approximate time between the bone segment and returning to the operation room was 30–35 min.^[6] This irradiated bone was used as a graft along with the free vascularised fibula for reconstruction [Figure 4].

Bony fixation was then achieved according to the situation of the recipient bones by impaling the end of the fibula into the medullary cavity of the recipient bone [Figures 5 and 6]. Wherever ECRT treated bone was used along with vascularised fibula, it was fixed with the native bone and fibula by creating a slit along its length to accommodate the vascularised fibula. This slit was made less than half the diameter of ECRT treated femur so as to maintain the strength of the bone [Figures 7 and 8]. The fixation was done using long compression plate of appropriate length, which was determined according to the length of the defect.

Free fibula was used for salvage of failed megaprotheses secondary to post-operative infection in two patients. The procedure was performed in two stages. In the first stage, the prosthesis was removed and replaced with antibiotic incorporated nail spacer cement. In the second stage, the nail spacer cement was removed and was replaced by vascularised free fibula and fixed with appropriate plates and screws.

The length of fibula harvested was between 15 and 22.5 cm (average 18.8 cm). ECRT was given in five patients out of the ten patients in the present study. Out of the remaining five cases, two were salvage of failed megaprotheses. Three cases had adequate circumference of fibula which did not require additional support with ECRT treated bone.

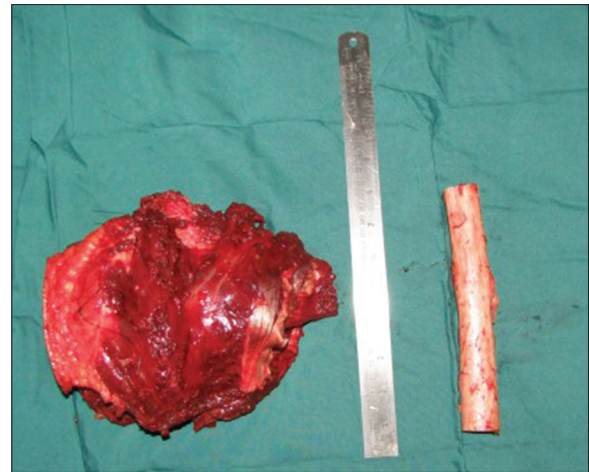

Figure 4: Resected tumour with extracorporeal radiotherapy treated femur

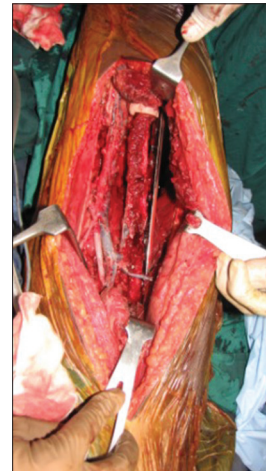

Figure 5: Vascularised fibula docked into the proximal and distal femur and fixed with long dynamic compression plate

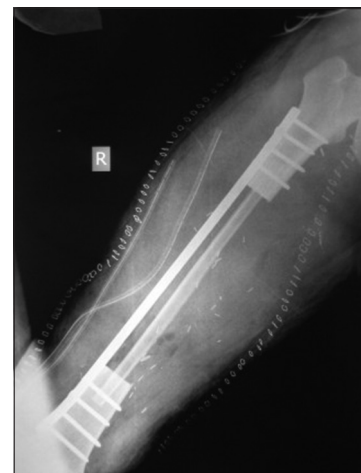

Figure 6: Post-operative X-ray showing free fibula bridging the gap of the resected tumour-bearing femur

Statistical methods

The data were checked for its distribution for its normality through Anderson-Darling test. The MSTs scores recorded

were non-normally distributed. A repeatedly measured scores recorded at various intervals of time (i.e., 6 months, 12 months and 1 year) were checked whether they are improving over time through Kruskal–Wallis ANOVA. The results suggested that the recorded scores improved over time ($P < 0.0001$). All the statistical analyses were done using Minitab 17.1.0® statistical package (©Minitab 17.1.0, Minitab Inc. 2013, Pennsylvania, USA). Complete statistical comparisons with other studies were limited

as the data recorded were dissimilar with respect to parameters recorded.

RESULTS

Ten patients were reconstructed with vascularised free fibula after the oncologic resection. Male:female ratio was 4:1. The mean age was 19.5 years (9–28 years) [Table 2].

Post-operatively, seven patients received chemotherapy and one received radiotherapy. All the patients were followed up every month for first 6 months, then

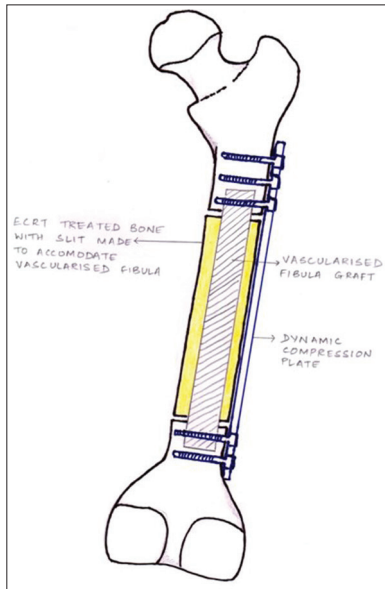


Figure 7: Diagram showing diaphyseal resection of femur bridged with extracorporeal radiotherapy treated femur and vascularised fibula graft

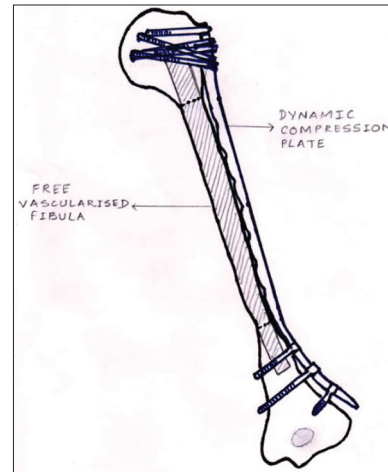


Figure 8: Diagram showing diaphyseal resection of humerus bridges with vascularised fibula graft

Table 2: Overview of the cases

Patient number	Age	Sex	Diagnosis	Defect length (cm)	Follow-up (years)	Disease-free survival (years)	MSTS score	ECRT	Weightbearing (partial)	Full weightbearing	Complication
1	23	Male	Right femur Ewing's sarcoma	20	2	2	Death	Yes	No	No	Bone metastasis
2	12	Male	Right femur Ewing's sarcoma	18	6.2	6.2	25	No	Yes (2 years post-operative)	No	Fracture fibula
3	13	Male	Left leg femur osteosarcoma	15	3.10	3.10	24	Yes	yes	No	Skin island necrosis
4	28	Female	Right femur osteosarcoma	17	3.5	3.5	25	No	yes	No	Fracture fibula
5	15	Female	Left leg femur osteosarcoma	18	2.7	2.7	25	No	Yes (2 years post-operative)	No	No
6	16	Male	Right femur Ewing's sarcoma	20	3.2	3.2	28	Yes	Yes	No	Fracture fibula
7	23	Male	Right femur osteosarcoma	18	3	3	30	No	No	Yes (2 years post-operative)	Fracture fibula
8	9	Male	Left femur Ewing's sarcoma	22	2.3	2.3	24	Yes	No	Yes (2 years post-operative)	No
9	28	Male	Right tibial osteosarcoma	21	1.8	1.8	Death	No	Yes	No	Death
10	28	Male	Left humerus chondrosarcoma	19	2.3	2.3	28	Yes	No	Full function	No

MSTS: Musculoskeletal Tumour Society, ECRT: Extracorporeal radiotherapy

every 3 months in the next 6 months and thereafter every 6 months after primary surgery. In each follow-up, the patients were assessed with an X-ray to look for the integrity of the fibula and the implant, callus formation at both ends of fibula and any fracture in the fibula.

Weightbearing was not allowed for 3–6 months post-operatively, followed by partial weightbearing over the period of next 6 months with support of walker or two axillary crutches. The decision on full weightbearing was based on the state of bone union [Figure 9].

In the first 2 years of follow-up, a chest X-ray was done every 3 months, to look for any metastasis. Every 6 months, computed tomography (CT) of the chest was performed to look for metastasis. Next 3 years, a 6 monthly X-ray and an annual CT and bone scan [Figure 10] were performed. There were two deaths in the series during follow-up, both being males, and both due to distant metastasis. Of the eight surviving patients, three had uneventful recovery. Four had fractures of the fibula, and one patient had necrosis of

skin paddle. Of the four patients who had fracture fibula, two patients had bending of the reconstruction plate. Both these patients were re-explored, and reconstruction plate revision was done, and the other two patients were managed conservatively. The patient who had necrosis of the skin paddle was managed with debridement and regular dressing, which healed with secondary intention. The fibula was viable in this patient.

The assessment of the function was done on the basis of MSTS score, which includes pain, function, patient acceptance, need for external support, walking ability and gait^[7] for the lower limb and pain, function, emotional acceptance, hand positioning, manual dexterity and lifting ability for the upper limb [Table 3].^[7]

The MSTS scores were calculated for all patients at 6 months post-surgery, at 1 year follow-up and last follow-up [Table 4]. The maximum MSTS score was 30 and minimum score was 24, average score being 26. On an average, the MSTS scores increase over time [Tables 5 and 6]. At the end of follow-up, seven out of

Table 3: Musculoskeletal Tumour Society score parameters

<i>Lower limb</i>						
<i>Points</i>	<i>Pain</i>	<i>Function</i>	<i>Emotional acceptance</i>	<i>Support</i>	<i>Walking ability</i>	<i>Gait</i>
5	None (no pain medications)	No restriction	Enthused (would recommend to others)	None	Unlimited (same as pre-surgery)	Normal
4	Intermediate	Intermediate	Intermediate	Intermediate	Intermediate	Intermediate
3	Modest, non-disabling	Recreational restriction (minor disability)	Satisfied (would do again)	Brace	Limited (significantly less)	Minor cosmetic alteration
2	Intermediate	Intermediate	Intermediate	Intermediate (occasional cane or crutch)	Intermediate	Intermediate
1	Moderate, intermittently disabling	Partial occupational restriction (major disability)	Accepts (would repeat reluctantly)	One cane or crutch	Inside only	Major cosmetic, minor functional deficit
0	Severe, continuously disabling	Total occupational restriction	Dislikes (would not repeat)	Two cane or crutch	Not independent	Major handicap
<i>Upper limb</i>						
<i>Points</i>	<i>Pain</i>	<i>Function</i>	<i>Emotional acceptance</i>	<i>Hand positioning</i>	<i>Manual dexterity</i>	<i>Lifting ability</i>
5	None (no pain medications)	No restriction	Enthused (would recommend to others)	Unlimited (180° elevation)	No limitation	Normal load
4	Intermediate	Intermediate	Intermediate	Intermediate	Intermediate	Intermediate
3	Modest, non-disabling	Recreational restriction (minor disability)	Satisfied (would do again)	Not above shoulder or no pronosupination	Loss of fine movement	Limited (minor load)
2	Intermediate	Intermediate	Intermediate	Intermediate	Intermediate	Intermediate (gravity only)
1	Moderate, intermittently disabling	Partial occupational restriction (major disability)	Accepts (would repeat reluctantly)	Not above waist (30° elevation)	Cannot pinch (major sensory loss)	Helping only (cannot overcome gravity)
0	Severe, continuously disabling	Total occupational restriction	Dislikes (would not repeat)	None (0° elevation)	Cannot grasp (anaesthetic hand)	Cannot help (cannot move)

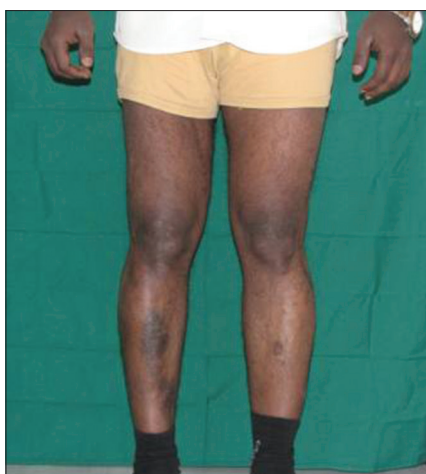

Figure 9: Full weightbearing 2 years post-operatively

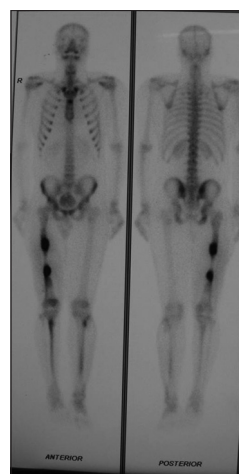


Figure 10: Bone scan showing hypertrophy at the ends of fibula graft

Table 4: Musculoskeletal Tumour Society scores

Patient number	MSTS score		
	6 months	1 year	Last follow-up
1	20	23	23
2	18	20	25
3	15	18	24
4	16	19	25
5	18	20	25
6	17	22	28
7	19	22	30
8	19	21	24
9	21	23	23
10	22	27	28

MSTS: Musculoskeletal Tumour Society

Table 5: The Musculoskeletal Tumour Society scores over time

Time of follow-up	Scores
6 months	18.5 (15-22)
1 st year	21.5 (18-27)
Last follow-up	25 (23-30)

The values are in median (range)

Table 6: The evaluation of Musculoskeletal Tumour Society scores over time

Time of follow-up	Scores	P
6 months	18.5±2.17	>0.05 versus 1 st year
1 st year	21.5±2.55	<0.001 versus 6 months
Last follow-up	25.5±2.37	<0.05 versus 1 st year

The values are in mean and SDs. 95% of CIs are used. A P<0.05 is considered as statistically significant. CI: Confidence interval, SD: Standard deviation

eight patients had union on both ends, with average time of 11 months, ranging from 9 to 18 months.

Three patients out of seven achieved full weightbearing at the end of 2 years, rest four patients had partial weightbearing at the end of 2 years after surgery. The patient with upper limb reconstruction had full upper limb function at the end of 2 years.

DISCUSSION

Currently, 85%–90% of patients with malignant bone tumours are candidates for limb salvage surgeries.^[8] The multitude of surgical procedures to reconstruct the bone defects following wide tumour resection are available.^[9] These procedures have their own advantages and disadvantages.

Conventional cancellous bone grafts are suitable for small defect in the bone with adequate soft-tissue cover.^[10] Virtually, all anatomic defects can be reconstructed with either allograft or vascularised fibula (Capanna technique).^[4,11] The healing mechanism of the bone allograft is characterised by limited revascularisation and is restricted within few millimetres of the bone surface.^[12] Reconstructive procedures with bone transport, such as the Ilizarov technique, include the disadvantage that it takes a long time (months to years) to compensate the long bone defect.

In our series, free vascularised fibula along with either ECRT autograft or vascularised fibula alone was used in ten patients with mean age of 19.5 years. Similar study was done by Krieg *et al.*^[13] on 16 patients [Table 7].

The functional outcome was calculated on the basis of MSTS score. The present study showed good functional outcome with average MSTS score was 86.6%, which was comparable to study done by Krieg *et al.*^[13] which had a score of 85%. There was no significant difference between study done by Krieg *et al.* and our study [Table 7].

In the present study, the average length of defect that was reconstructed was 18.8 cm, which was significantly higher than studies done by Krieg *et al.*^[13] and William *et al.*^[14] [Table 7].

Table 7: Comparison of various factors with other studies

Studies	Number of patients	Mean follow-up (years)	Mean defect length (cm)	MSTS score (%)	Complication rate (%)	Disease-free survival (years)
Zaretski <i>et al.</i> ^[15]	30	2.5	NR	-	37%=11/30	97%=29/30
Krieg <i>et al.</i> ^[13]	16	1.0	16.2	85	-	-
William <i>et al.</i> ^[14]	30	4.9	14.8	-	53%=16/30	-
Rabitsch <i>et al.</i> ^[16]	12	3.2	18.7	-	50%=6/12	80%=9/12
Our study	10	3.1	18.5	86.6	50%=5/10	80%=8/10

MSTS: Musculoskeletal Tumour Society, NR: Not reported

In our series, three patients had full weightbearing, four patients had partial weightbearing and one patient with upper limb reconstruction had full upper limb function.

The average time for full weightbearing in the present study was 10 months, which was slightly more than 8 and 9.2 months in studies done by Krieg *et al.*^[13] and Zaretski *et al.*^[15] respectively. This delayed weightbearing in the present study is due to long size of the defect and our guarded approach towards weightbearing.

In our series, the complication rates were 50%, which were comparable to studies done by William *et al.*^[14] and Rabitsch *et al.*^[16] [Table 7]. These complications were manageable and did not lead to any amputation.

The most common complication after vascularised fibula reconstruction was fractures of the fibula. In our study, four patients had fracture (50%). Studies done by Ozaki *et al.* and Abed *et al.* have cited the fracture rates between 20% and 40%.^[17] Graft fracture rates in study done by Rabitsch *et al.*^[16] and William *et al.*^[14] were 33.3% and 20%, respectively.

In our study, disease-free survival at the end of 2 years was 80%. This was comparable to the study done by Rabitsch *et al.*^[16] which was 80% after 2 years as well as study done by Zaretski *et al.*^[15] which was 97% after 2.5 years of follow-up.

Limb salvage should be aimed at providing stability and function.^[18] None of the patients had to undergo amputation of the limb; hence, there were 100% limb salvage and acceptable long-term function.

CONCLUSION

Our study indicates that limb salvage with vascularised fibula graft for long bone sarcoma defects gives good functional outcome in terms of MSTS scores. In spite of

initial complications, the long-term results of functional outcome were acceptable. Thus, in the present era, limb salvage for primary bone sarcoma should be the primary goal of treatment.

Financial support and sponsorship

Nil.

Conflicts of interest

There are no conflicts of interest.

REFERENCES

1. Eilber FR, Eckhardt J, Morton DL. Advances in the treatment of sarcomas of the extremity. Current status of limb salvage. *Cancer* 1984;54 11 Suppl: 2695-701.
2. Virkus WW, Henshaw RM, Millers BJ, Gitelis S. Use of allografts and segmental prostheses for reconstruction of segmental bone defects. In: Wiesel SW, editor. *Operative Technique in Orthopaedic Surgical Oncology*. 1st ed. Philadelphia: Lippincott Williams and Wilkins; 2012. p. 288-305.
3. Gosheger G, Gebert C, Ahrens H, Streitbueger A, Winkelmann W, Harges J. Endoprosthetic reconstruction in 250 patients with sarcoma. *Clin Orthop Relat Res* 2006;450:164-71.
4. Capanna R, Campanacci DA, Belot N, Beltrami G, Manfrini M, Innocenti M, *et al.* A new reconstructive technique for intercalary defects of long bones: The association of massive allograft with vascularized fibular autograft. Long-term results and comparison with alternative techniques. *Orthop Clin North Am* 2007;38:51-60, vi.
5. DiCaprio MR, Friedlaender GE. Malignant bone tumors: Limb sparing versus amputation. *J Am Acad Orthop Surg* 2003;11:25-37.
6. Davidson AW, Hong A, McCarthy SW, Stalley PD. En-bloc resection, extracorporeal irradiation, and re-implantation in limb salvage for bony malignancies. *J Bone Joint Surg Br* 2005;87:851-7.
7. Enneking WF, Dunham W, Gebhardt MC, Malawar M, Pritchard DJ. A system for the functional evaluation of reconstructive procedures after surgical treatment of tumors of the musculoskeletal system. *Clin Orthop Relat Res* 1993;286:241-6.
8. Weber KL. What's new in musculoskeletal oncology. *J Bone Joint Surg Am* 2005;87:1400-10.
9. Puri A. Limb salvage in musculoskeletal oncology: Recent advances. *Indian J Plast Surg* 2014;47:175-84.
10. Aponte-Tinco LA, Ritacco LE, Albergio JI, Ayerza MA, Muscolo DL, Farfalli GL. The principles and applications of fresh frozen allografts to bone and joint reconstruction. *Orthop Clin North Am* 2014;45:257-69.

11. Donati D, Capanna R, Campanacci D, Del Ben M, Ercolani C, Masetti C, *et al.* The use of massive bone allografts for intercalary reconstruction and arthrodeses after tumor resection. A multicentric European study. *Chir Organi Mov* 1993;78:81-94.
12. Mankin HJ, Gebhardt MC, Tomford WW. The use of frozen cadaveric allografts in the management of patients with bone tumors of the extremities. *Orthop Clin North Am* 1987;18:275-89.
13. Krieg AH, Davidson AW, Stalley PD. Intercalary femoral reconstruction with extracorporeal irradiated autogenous bone graft in limb-salvage surgery. *J Bone Joint Surg Br* 2007;89:366-71.
14. William CE, Vasileios K, Lawrence SL, Brian EB. Free vascularized fibular graft reconstruction of large skeletal defects after tumor resection. *Clin Orthop Relat Res* 2010;468:590-8.
15. Zaretski A, Amir A, Meller I, Leshem D, Kollender Y, Barnea Y, *et al.* Free fibula long bone reconstruction in orthopedic oncology: A surgical algorithm for reconstructive options. *Plast Reconstr Surg* 2004;113:1989-2000.
16. Rabitsch K, Maurer-Ertl W, Pirker-Frühaufl U, Wibmer C, Leithner A. Intercalary reconstructions with vascularised fibula and allograft after tumour resection in the lower limb. *Sarcoma* 2013;2013:160295.
17. Abed YY, Beltrami G, Campanacci DA, Innocenti M, Scoccianti G, Capanna R. Biological reconstruction after resection of bone tumours around the knee: Long-term follow-up. *J Bone Joint Surg Br* 2009;91:1366-72.
18. Kadam D. Limb salvage surgery. *Indian J Plast Surg* 2013;46:265-74.