

Original Article

Siliconomas of the lower limb: Tumour-like excision and reconstruction

Tommaso Agostini, Raffaella Perello

Department of Plastic and Reconstructive Surgery, Centro Chirurgico San Paolo, Pistoia, Italy

Address for correspondence: Dr. Tommaso Agostini, Department of Plastic and Reconstructive Surgery, Centro Chirurgico San Paolo, Via Del Quadrifoglio 3, 51100, Pistoia, Italy. E-mail: tommasoagostini@gmail.com

ABSTRACT

Background: Silicone oil injection can cause several complications including pain, cellulitis, abscesses, skin compromise, migration, embolism and multiorgan failure. Oil-infested tissue excision remains the solely treatment to prevent such complications. **Objectives:** The authors evaluate tumor-like excision of the oil-infested tissue as a treatment for patients experiencing silicone injections in the lower limbs, to both preserve aesthetic appearance and solve further risk of complication from silicone. **Methods:** Between January 2004 and January 2011 a total of 12 consecutive, nonrandomized female patients underwent surgical management of siliconoma of the lower limb. The mean age was 41-years, range from 22 to 61 years and all patients didn't referred comorbidities. Eight siliconomas were located on the leg and 4 were on the thigh. The mean area of siliconoma was 35 cm², range from 25 to 60 cm². Each patient was evaluated by ultrasonography and EchocolorDoppler of the soft tissue and in order to achieve a "staging" of siliconoma. **Results:** Healing was uneventful in all cases. Three patients (25%) suffering hypertrophic scarring underwent further injection of corticosteroids to improve hypertrophic scars quality. Two patients (16.6%) required a further session of structural fat grafting to improve thigh's profile. All patients were satisfied with the cosmetic results and indispositions requiring medical therapy disappeared. **Conclusions:** Tumor-like excision and immediate reconstruction appears to be a safe and consistent surgical option that preserves aesthetic appearance for patients victims of illegal oil silicone injection of the lower limbs.

KEY WORDS

Reconstruction; siliconoma functional outcome; silicone

INTRODUCTION

Siliconoma is defined as a circumscribed tissue response to extravasated silicone accompanied by a foreign body-type giant cell reaction, histiocytes

and brightly refractile silicone crystals.^[1-3] Frequently, these types of injuries are iatrogenic and are performed illegally by physicians or non-medical staff. Silicone oil

Access this article online	
Quick Response Code:	Website: www.ijps.org
	DOI: 10.4103/0970-0358.197228

This is an open access article distributed under the terms of the Creative Commons Attribution-NonCommercial-ShareAlike 3.0 License, which allows others to remix, tweak, and build upon the work non-commercially, as long as the author is credited and the new creations are licensed under the identical terms.

For reprints contact: reprints@medknow.com

How to cite this article: Agostini T, Perello R. Siliconomas of the lower limb: Tumour-like excision and reconstruction. *Indian J Plast Surg* 2016;49:384-9.

injections can lead to several complications including calcification,^[1] granuloma,^[2-4] migration events to distant sites,^[5] autoimmune disease,^[6,7] skin ulcers,^[8,9] lymphoedema,^[10] chronic inflammatory syndromes,^[11] pneumonitis,^[12] embolisms,^[13] multi-organ failure and even death.^[14,15] Typically, the onset of these complications is unpredictable and undetected until several years after the injections.^[8,9] Siliconoma is a growing problem due to the expanding development of cosmetic medicine and it should not be underestimated.

Siliconoma may affect any part of the body since silicone oil is injected to correct contour deformities. Naturally, the face represents the most affected area and management of siliconoma in aesthetic-sensitive areas still represents a challenge both from a medical and surgical point of view, often requiring minimally invasive approaches that do not offer a real recovery, but with more or less temporary resolutions.^[16,17] The surgical approach in other parts of the body can offer more feasible results provided that the amount of oil injected is somehow limited in quantity or circumscribed by an autologous inflammatory response, thus making it possible to set on a well contour defined lesion.^[18] Herein, we describe a two-stage surgical approach to treat well-circumscribed siliconoma of the lower limbs with full recovery.

PATIENTS AND METHODS

Between January 2004 and January 2011, a total of 12 consecutive, nonrandomised female patients underwent surgical management of siliconoma of the lower limbs. The mean age was 41 years, ranging from 22 to 61 years, and no patients had comorbidities. Eight siliconomas were located on the leg, and four were on the thigh. All patients underwent silicone oil injections to correct contour deformities: nine patients (75%) to correct lipodystrophy resulting from repeated corticosteroid injection to improve hypertrophic scars, and three patients (25%) to improve lower limb profile following traumatic lipodystrophy.

All patients reported recurrent local infections dating from at least 1 month after their treatment (mean 2 months; ranging from 1 to 4 months), which obliged them to assume pharmacological therapy consisting of antibiotics and corticosteroids until a complete remission of their symptoms. Eight patients (66.6%) complained of fatigue and malaise during the acute phase of infection. Three of them (25%) underwent previous liposuction of the

siliconoma with only partial recovery. The mean area of siliconoma was 35 cm², ranging from 25 to 60 cm². Written, informed consent to these procedures was always obtained. The mean follow-up was 67 months, ranging from 96 to 48 months. In all cases, it was not possible to identify the origin of the silicone injected (medical or industrial), and ten patients reported they did not know what kind of filler they were injected with; only two patients were specifically informed that they were to undergo silicone injection.

Surgical technique

Ultrasonography of soft tissue and locoregional lymph nodes was performed to achieve a 'staging' of the siliconoma, with a particular interest to assess the silicone oil over the muscular fascia and negative lymph node involvement. Echo colour Doppler was done to confirm a healthy venous system despite recurrent inflammation. Under local anaesthesia (xylocaine 1% with epinephrine solution 1:200,000), an incision was made over previously treated scars where possible, or along the Langer lines, and soft tissue saturated with oil was resected with a 5 mm healthy tissue radius confirmed by intraoperative ultrasounds [Figure 1]. Resection included soft tissue from the subdermal plane to the muscular fascia [Figures 2 and 3]. While on the legs, surgical resection was performed including the Scarpa fascia as well, on the thigh, the resection was performed in a suprafascial plane. The reason for this is that soft tissue is thicker on the thigh when compared to the leg and so consequently resulted in the full-thickness involvement of silicone oil on the leg, while only partially on the thigh. Healthy tissue was assessed through the frozen section. After carefully

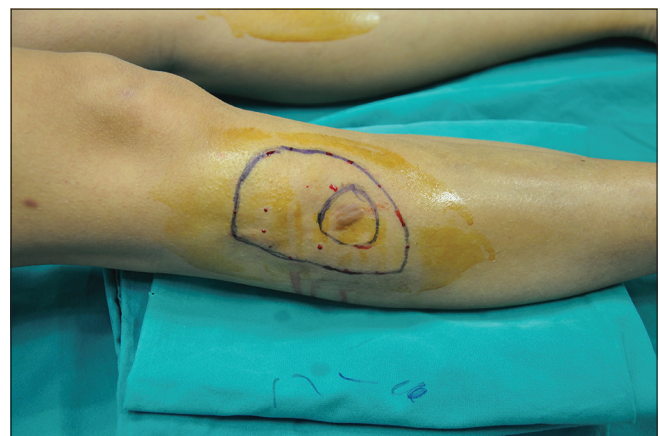

Figure 1: Preoperative of a large siliconoma (10.5 cm × 4 cm) of the right lower leg of a 43-year-old female patient. Note, this patient underwent corticosteroid injections of a hypertrophic scar which resulted in soft-tissue atrophy corrected with illegal silicone oil injection

observing haemostasis, a double layer of dermal regeneration template (Integra®, Life Sciences Corp., New Jersey, USA) was applied and left on for 3 weeks to promote granulation and to allow a benefit in terms of thickness, which helped to achieve a satisfactory reconstruction [Figure 4]. Antibiotics and low-weight heparin were administered during this period. The patients' healing processes were medically monitored twice a week. When the silicone layer of the dermal regenerative template was removed, the direct closure was performed [Figure 5].

A flowchart to treat siliconoma of the lower limb is available in Figure 6.

RESULTS

Healing was uneventful in all cases, and patients were able to walk starting from the day after surgery. Direct closure of the defect was performed from 21 to

28 days (mean, 23 days) following siliconoma resection. Three patients (25%) suffering hypertrophic scarring underwent further injection of corticosteroids following structural fat grafting (once a month for 3 months) to improve scar quality. Two patients (16.6%) required a further session of structural fat grafting to improve their thigh's profile. Each patient underwent lipoinjection of 10 cc of purified fat. The pinch test was performed at 6 and 12 months and showed good pliability. All patients were satisfied with their cosmetic results and their indispositions requiring medical therapy disappeared.

DISCUSSION

In Italy, the use of silicone has been forbidden since 1994 as published in the Official Gazette of 29/08/94, n. 201; Ministerial Decree of 12/08/94.^[9,17,18] However, the improper use of liquid silicone is still observed in Europe, and legal injections continued to be used extensively in Japan and Asia.

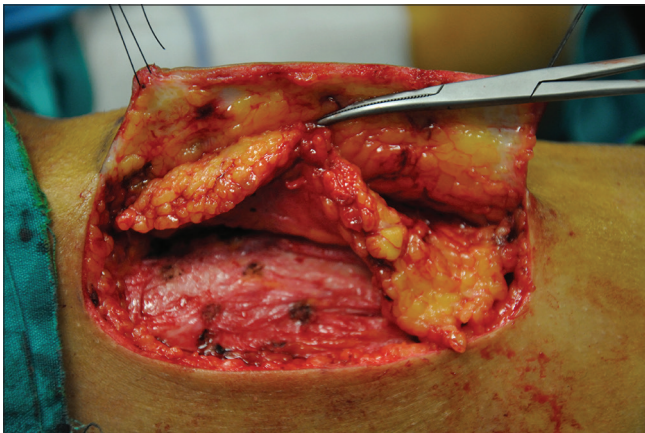

Figure 2: Intraoperative excision of the oil-infested soft tissue with a 0.5 cm of healthy margins till the deep fascia

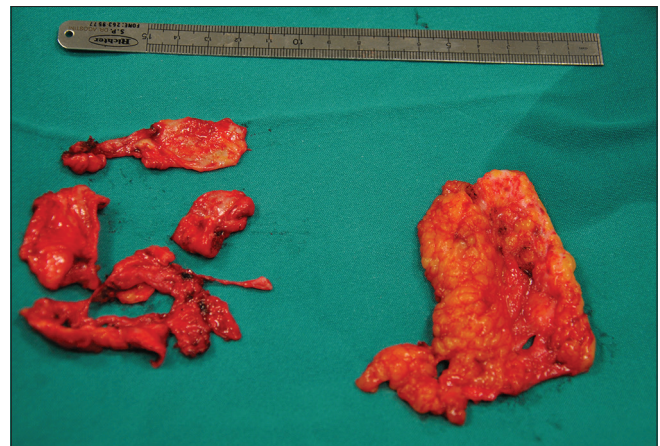


Figure 3: Oil-infested tissue resected. Note the fibrous aspect of the subcutaneous with the absence of the fascia Scarpa

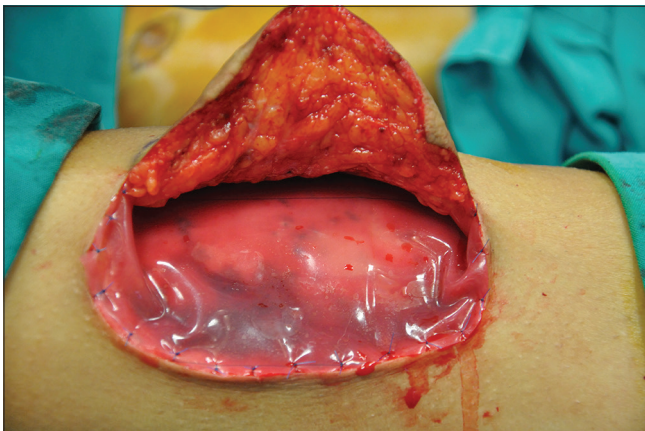


Figure 4: Defect reconstruction using a double layer of dermal regeneration template

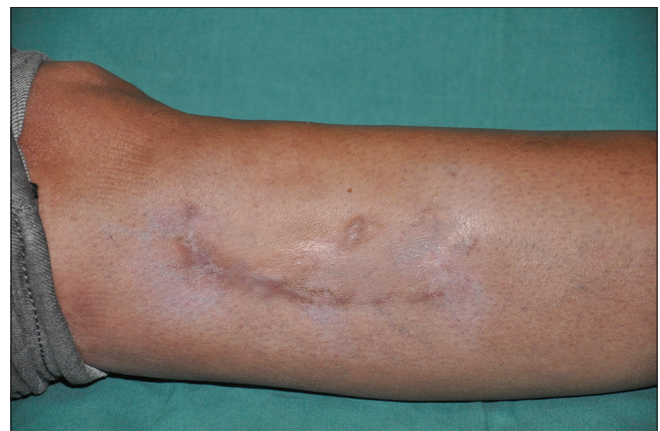

Figure 5: Outcome of reconstruction 4 years postoperatively

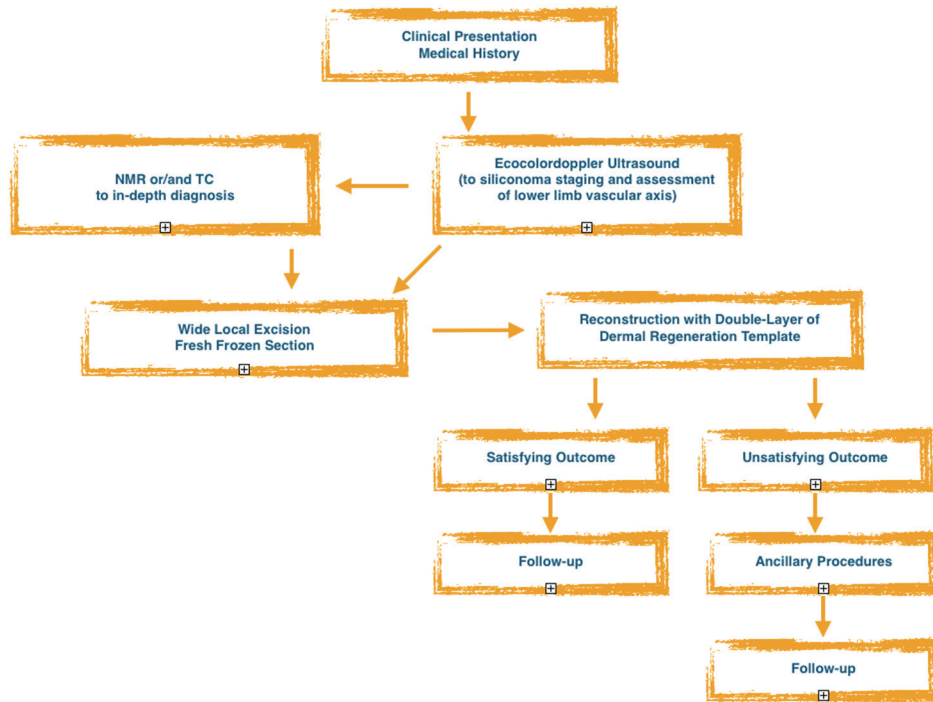


Figure 6: Flowchart to treat siliconoma of the lower limb

The management of silicon oil injections is still in high demand, especially for aesthetically sensitive areas.^[1-9] Many patients suffer the sequelae of illegal injections with serious repercussions on their daily activities and general health.^[13,14] These injections can also be life-threatening, and a surgical approach that is decisive and safe must be considered in selected patients.^[14] Several complications, such as granuloma,^[2,3] skin ulcers,^[8,9] migration even to the distance,^[5] pneumonitis, embolism,^[12] and multi-system organ failure^[15] have already been mentioned. The onset of complications varies from 2 to 7 years after the injections and for this reason, correct diagnosis of the causes of these complications can be challenging.^[9] Moreover, most people who undergo such injections both underestimate the potential risk or ignore how they are victims of illegal injections.^[17] Most of the complicated cases derive from cosmetic buttock augmentation and are linked to the quantity of silicone injected.

Several surgical approaches have been described, from standard liposuction^[18] and ultrasound-assisted liposuction,^[19,20] combined liposuction and lipofilling,^[21] to dermolipectomy^[22] and reconstruction of the whole anatomical area through tissue expansion^[23] or pedicle flaps.^[24] Liposuction, although minimally invasive, does not guarantee a complete removal of all the injected oil, which can migrate, both intraoperatively or later posing

high risk for patients.^[19,20] Unsuccessful surgery can lead to long-term complications and scarring.^[22-27] Thus, open surgery remains the gold standard to achieve complete eradication of the infested tissue, and a subsequent reconstruction of the defect is mandatory. To this regard, Integra® (Life Sciences Corp., New Jersey, USA) is perhaps the most used and best-established artificial dermal template and it is approved for use in full/split-thickness soft-tissue defects. This device consists of a matrix of purified collagen obtained from bovine tendons cross-linked with glycosaminoglycan from shark cartilage. Integra is supplied with a removable silicone layer that functions as a temporary and protective epidermis.^[28-31]

The described technique has the advantage of being safe and consistent, guarantying a complete excision of the oil-infested area and immediate reconstruction of the defect. This procedure achieved very satisfying results when used on the lower limbs, and the indication could be extended to other areas of the body with similar soft tissue thickness, such as the upper limb. The main advantage lies in the preservation of the skin because the excision is limited from the subdermal plane down to the muscular fascia. Above all, all the infiltrated tissues are removed. Without complete silicone removal, there is a risk of further infection and latent syndrome embolisation.^[26] Limitations include the necessity to

perform two operations with a recovery of at least 3 weeks between the procedures although, at least in the present study, this did not interfere with patients' satisfaction. Finally, body mass index and dimension of siliconoma (i.e., buttocks or breasts) are further limitations to tumour-like excision of siliconoma: the first could necessitate re-defining lipomodelling procedures to achieve the desired thickness; the second could limit the applicability of the present technique to the advantage of other described techniques.^[19,20,22-27] Finally, if examination of the margins of the operative specimen is doubtful, a careful follow-up should be made, and a secondary stage may be necessary to remove the remaining infiltrating tissues. The main challenge with these difficult cases is the successful extirpation all the infiltrated tissues.

CONCLUSION

This 'tumour-like' approach to well-defined siliconomas proves to be a valuable tool to completely solve the symptoms and risks connected to silicon oil removal. Although this approach has not been indicated yet, it can be considered decisive to solve chronic inflammation even if it requires two steps and a 3-week healing period to promote granulation. The surgical approach to siliconoma remains the most effective and reliable treatment protocol, and this technique is an excellent tool in plastic and reconstructive armamentarium.

Financial support and sponsorship

The Authors did not receive any financial support or sponsorship.

Conflicts of interest

There are no conflicts of interest.

REFERENCES

- Lee JH, Choi HJ. Rare complication of silicone fluid injection presenting as multiple calcification and skin defect in both legs: A case report. *Int J Low Extrem Wounds* 2015;14:95-7.
- Altmeyer MD, Anderson LL, Wang AR. Silicone migration and granuloma formation. *J Cosmet Dermatol* 2009;8:92-7.
- Camuzard O, Dumas P, Foissac R, Fernandez J, David S, Balaguer T, *et al*. Severe granulomatous reaction associated with hypercalcemia occurring after silicone soft tissue augmentation of the buttocks: A case report. *Aesthetic Plast Surg* 2014;38:95-9.
- Gold HL, Wang I, Meehan S, Sanchez M, Smith GP. Gluteal silicone injections leading to extensive filler migration with induration and arthralgia. *Dermatol Online J* 2014;21. pii: 13030/qt4xf2m886.
- Jeng CJ, Ko ML, Wang TH, Huang SH. Vulvar siliconoma migrating from injected silicone breast augmentation. *BJOG* 2005;112:1659-60.
- d'Ythurbide G, Kerrou K, Brocheriou I, Hertig A. Reactive amyloidosis complicated by end-stage renal disease 28 years after liquid silicone injection in the buttocks. *BMJ Case Rep* 2012;2012. pii: Bcr2012006803.
- Guerrissi J, Béjar A. Massive injections of adulterated liquid silicone: Local complications and development of autoimmune diseases. *Ann Plast Surg* 1998;41:572-3.
- Carella S, Romanzi A, Ciotti M, Onesti MG. Skin ulcer: A long-term complication after massive liquid silicone oil infiltration. *Aesthetic Plast Surg* 2013;37:1220-4.
- Fumo G, Ferrel F, Murgia S, Galletti R, Pau M. A serious complication due to liquid silicone injection in the legs for cosmetic purpose. *Clin Ter* 2013;164:e377-9.
- Gaber Y. Secondary lymphoedema of the lower leg as an unusual side-effect of a liquid silicone injection in the hips and buttocks. *Dermatology* 2004;208:342-4.
- Frey C, Naritoku W, Kerr R, Halikus N. Tarsal tunnel syndrome secondary to cosmetic silicone injections. *Foot Ankle* 1993;14:407-10.
- Zamora AC, Collard HR, Barrera L, Mendoza F, Webb WR, Carrillo G. Silicone injection causing acute pneumonitis: A case series. *Lung* 2009;187:241-4.
- Restrepo CS, Artunduaga M, Carrillo JA, Rivera AL, Ojeda P, Martinez-Jimenez S, *et al*. Silicone pulmonary embolism: Report of 10 cases and review of the literature. *J Comput Assist Tomogr* 2009;33:233-7.
- Price EA, Schueler H, Perper JA. Massive systemic silicone embolism: A case report and review of literature. *Am J Forensic Med Pathol* 2006;27:97-102.
- Clark RF, Cantrell FL, Pacal A, Chen W, Betten DP. Subcutaneous silicone injection leading to multi-system organ failure. *Clin Toxicol (Phila)* 2008;46:834-7.
- Anastassov GE, Schulhof S, Lumerman H. Complications after facial contour augmentation with injectable silicone. Diagnosis and treatment. Report of a severe case. *Int J Oral Maxillofac Surg* 2008;37:955-60.
- Kluger N, Plantier F, Carlotti A, Guillevin L. Facial granuloma after occult silicone injection (siliconoma): A diagnosis not to be missed. *Eur J Intern Med* 2009;20:e120-1.
- Almeida DA, Rebello C, Prestes MA. The employment of suction for the removal of siliconomas. *Plast Reconstr Surg* 1990;85:635-6.
- Grippaudo FR, Spalvieri C, Rossi A, Onesti MG, Scuderi N. Ultrasound-assisted liposuction for the removal of siliconomas. *Scand J Plast Reconstr Surg Hand Surg* 2004;38:21-6.
- Bassetto F, Abatangelo S, Masetto L, Vindigni V. Ultrasound-assisted liposuction as a safe and effective method for the removal of siliconomas. *Aesthetic Plast Surg* 2012;36:220-2.
- Salgado CJ, Sinha VR, Desai U. Liposuction and lipofilling for treatment of symptomatic silicone toxicosis of the gluteal region. *Aesthet Surg J* 2014;34:571-7.
- Loustau HD, Mayer HF, Catterino L. Dermolipectomy of the thighs and buttocks to solve a massive silicone oil injection. *Aesthetic Plast Surg* 2009;33:657-60.
- Wilke CP, Woods JE. Use of tissue expanders in reconstruction after excision of multiple large silicone granulomas. *Ann Plast Surg* 1993;30:367-70.
- Lai YL, Weng CJ, Noordhoff MS. Breast reconstruction with TRAM flap after subcutaneous mastectomy for injected material (siliconoma). *Br J Plast Surg* 2001;54:331-4.
- Hage JJ, Kanhai RC, Oen AL, van Diest PJ, Karim RB. The devastating outcome of massive subcutaneous injection of highly viscous fluids in male-to-female transsexuals. *Plast Reconstr Surg* 2001;107:734-41.

26. Purdy-Payne EK, Green J, Zenoni S, Evans AN, Bilski TR. A serious complication of illicit silicone injections: Latent silicone embolization syndrome after incision and drainage of local injection site. *Surg Infect (Larchmt)* 2015;16:473-7.
27. Park ME, Curreri AT, Taylor GA, Burris K. Silicone granulomas, a growing problem? *J Clin Aesthet Dermatol* 2016;9:48-51.
28. Rehim SA, Singhal M, Chung KC. Dermal skin substitutes for upper limb reconstruction: Current status, indications, and contraindications. *Hand Clin* 2014;30:239-52, vii.
29. Cherubino M, Scamoni S, Pellegatta I, Maggiulli F, Minuti A, Valdatta L. Massive de-gloving thigh injury treated by vacuum therapy, dermal regeneration matrix and lipografting. *Afr J Paediatr Surg* 2013;10:386-9.
30. Dini M, Quercioli F, Mori A, Romano GF, Lee AQ, Agostini T. Vacuum-assisted closure, dermal regeneration template and degloved cryopreserved skin as useful tools in subtotal degloving of the lower limb. *Injury* 2012;43:957-9.
31. Lee SM, Stewart CL, Miller CJ, Chu EY. The histopathologic features of Integra® dermal regeneration template. *J Cutan Pathol* 2015;42:368-9.