

## Original Article

# Passage through the carotid sheath: An alternative path to the pre-spinal route for direct repair of contralateral C7 to the lower trunk in total brachial plexus root avulsion injury

Piyush Bhupendra Doshi, Yogesh Chimanbhai Bhatt<sup>1</sup>

Department of Plastic Surgery, SBKS Medical Institute and Research Centre, Sumandeep Vidhyapeeth University,

<sup>1</sup>Department of Brachial Plexus Injury, Aakar Plastic Surgery Hospital, Vadodara, Gujarat, India

**Address for correspondence:** Dr. Piyush Doshi, 47 Gulmohar Park, Near Akota Garden, Akota, Vadodara - 390 020, Gujarat, India.  
E-mail: dr.p.doshi@gmail.com

### ABSTRACT

**Context:** In surgical management of global brachial plexus injuries, direct repair of contralateral C7 (cC7) to the anterior division of the lower trunk, can produce good extrinsic finger flexion. The pitfalls associated with the pre-spinal passage have, perhaps, proved to be a deterrent for using this technique routinely. **Aims:** The aim of this study is to demonstrate an alternative to pre-spinal route for cC7 transfer in brachial plexus avulsion injuries. **Methods:** We noted that the mobilised lower trunk, which reaches the level of the scalenus anterior by passage deep to the clavicle, can be brought to the suprasternal notch when brought out from below the clavicle. This area was dissected in two cadavres, and safe passage was found through the carotid sheath with the common carotid artery medially and the internal jugular vein with the vagus nerve laterally. The cC7 root dissected medial to the scalenus anterior muscle can be directly transferred along this path to the subcutaneous plane at the suprasternal notch. This study allowed us to execute a direct repair in ten clinical cases of global brachial plexus injuries. In each case, the passage was prepared rapidly and uneventfully. The repair was technically simple and could be performed comfortably using suitable fine suture materials. In none of these cases, did we need to shorten the humerus. **Results:** The clinical outcome of this technique is awaited. **Conclusions:** We advocate carotid sheath route to approximate the cC7 to the injured lower trunk in global palsies, as the risks associated with the pre-spinal route can be readily avoided.

### KEY WORDS

Anterior division of lower trunk; brachial plexus injury; carotid sheath route; contralateral C7; direct repair; finger flexion

Access this article online	
Quick Response Code: 	Website: www.ijps.org
	DOI: 10.4103/0970-0358.191327

This is an open access article distributed under the terms of the Creative Commons Attribution-NonCommercial-ShareAlike 3.0 License, which allows others to remix, tweak, and build upon the work non-commercially, as long as the author is credited and the new creations are licensed under the identical terms.

**For reprints contact:** reprints@medknow.com

**How to cite this article:** Doshi PB, Bhatt YC. Passage through the carotid sheath: An alternative path to the pre-spinal route for direct repair of contralateral C7 to the lower trunk in total brachial plexus root avulsion injury. Indian J Plast Surg 2016;49:159-63.

## INTRODUCTION

In the surgical management of post-traumatic brachial plexus injuries, nerve transfers and nerve grafting have produced consistent results in the restoration of the control at the shoulder and elbow. However, the efforts in regaining distal functions in global palsies have not met with similar success. The use of contralateral C7 (cC7) (with the help of non-vascularised or vascularised nerve grafts) offered the possibility of getting distal hand functions. However, the feeble and inconsistent return of extrinsic flexion seen over the years has led to diminishing interest in the cC7 transfer.<sup>[1-7]</sup> The direct repair of cC7 with lower trunk produced superior and consistent result in restoration of extrinsic finger flexion.<sup>[8,9]</sup> However, despite the landmark report from Beijing in 2013, very few other units have adopted this technique. The pitfalls associated with the pre-spinal or retro-oesophageal passage have, perhaps, proved to be a deterrent.<sup>[10,11]</sup> We have looked for an alternative to the pre-spinal route.

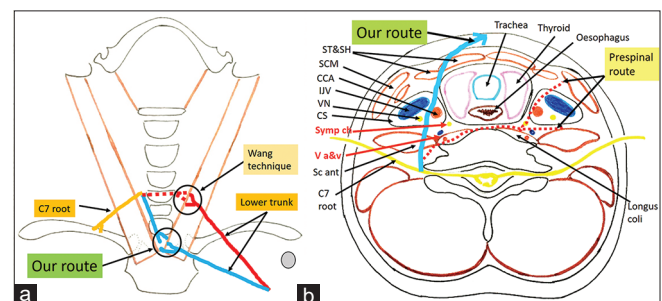
## METHODS

We have used the cC7 (complete root) transfer for a direct approximation to the anterior division of the lower trunk<sup>[8]</sup> in cases of global root avulsions since October 2013. During this period, we looked for an alternative to the pre-spinal route.<sup>[12,13]</sup> We noted that during mobilisation of the avulsed lower trunk, the stump could be delivered to the level of the scalenus anterior by passage deep to the clavicle. At the same time, the end of the trunk could also be brought to the suprasternal notch in midline if it is brought out from below the clavicle. Hence, the quest was for a method to bring the cC7 to the midline at that level [Figure 1a].

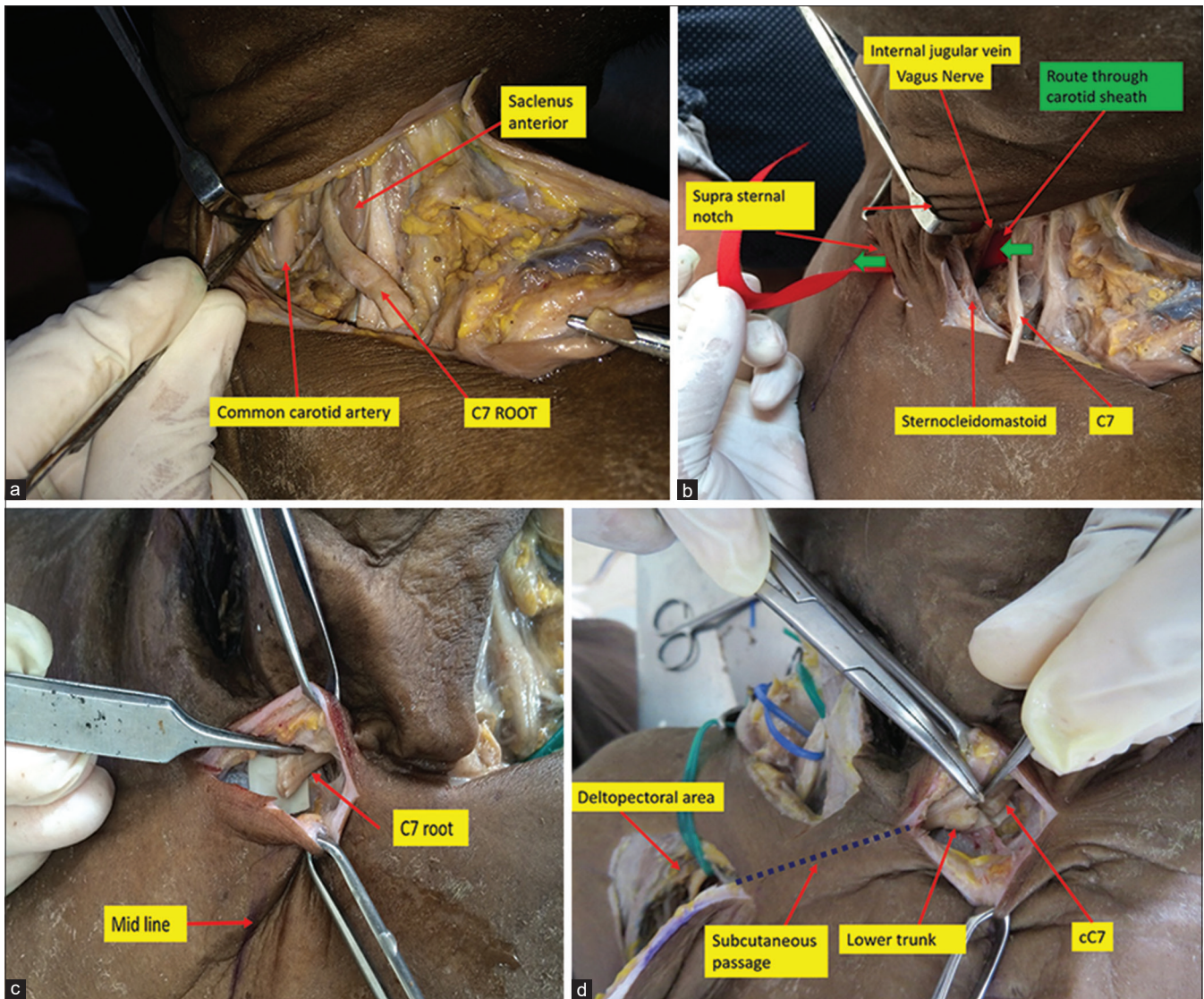
The anatomy of the neck, anterior to the plexus and medial to the sternocleidomastoid was studied [Figure 1b]. Once the cC7 is divided distally, the branch to the serratus anterior is divided and the trunk is delivered medial to the scalenus anterior with the pivot point at the intervertebral foramen. At this level, the internal jugular vein (IJV) lies anterior to it running snugly just deep to the medial border of the sternocleidomastoid muscle. This area was exposed from the suprasternal notch in two cadavers. The anterior insertion of the sternocleidomastoid was retracted laterally and the strap muscles covering the common carotid artery (CCA) were exposed. These were retracted medially revealing the

vagus nerve lying postero-medial to the IJV. Further deep dissection through the fat in the carotid sheath brought us to the anterior aspect of the scalenus anterior and the intervertebral foramen [Figure 2a]. There were no arterial branches, nor venous tributaries, crossing the passage between the IJV and the CCA [Figure 2b]. The important structures such as vertebral and inferior thyroid vessels, sympathetic chain and recurrent laryngeal nerve lie medial and deep to CCA. By remaining lateral to CCA, we can avoid injury to these structures [Figure 1b].

In each cadaver, the maximum possible length of the C7 (distal to its bifurcation into anterior and posterior divisions and distal to the origin of the pectoral branch, protecting the converging posterior division of the lower trunk) was harvested. The trunk measured 6 cm and 5.5 cm, respectively, in the two cadavers (measured from the pivot point at the intervertebral foramen). The trunk was delivered medial to the scalenus anterior and, then, via the space between the IJV and the CCA, to the suprasternal space. This could be easily achieved in each case [Figure 2c]. The injured side C8 and T1 were divided at the intervertebral foramina and lower trunk was mobilised by sectioning the pectoral and cutaneous branches as described in the article by Wang *et al.*<sup>[8]</sup> The posterior division of the lower trunk was separated. The ends of the C8 and T1, thus freed, could be delivered to the suprasternal space via a subcutaneous tunnel starting in the deltopectoral groove. This latter passage traced a direct course for the medial cord and adduction of the arm actually helped in placing the end in close approximation to the cC7 stump [Figure 2d].



**Figure 1:** (a) Illustration showing comparison of our route with pre-spinal route. The contralateral C7 is turned at the intervertebral foramen and comes anteromedially while the opposite lower trunk is transferred from below the clavicle to the suprasternal notch. (b) Schematic illustration of the contralateral C7 transfer through carotid sheath between the common carotid artery medially and the internal jugular vein and vagus nerve laterally. The subcutaneous plane is reached by retracting sternocleidomastoid muscle laterally and the strap muscles medially. Keys: Sc ant - Scalenus anterior, V a and v - Vertebral artery and vein, Symp ch - Sympathetic chain, CS - Carotid sheath, VN - Vagus nerve, IJV - Internal jugular vein, CCA - Common carotid artery, SCM - Sternocleidomastoid, ST and SH - Sternothyroid and sternohyoid



**Figure 2:** (a) Cadaveric dissection showing harvest of C7 root (delivered medial to the scalenus anterior) and its relation to the carotid sheath. (b) Route through the carotid sheath to the suprasternal notch – the sternocleidomastoid, internal jugular vein and vagus nerve lying laterally and common carotid artery medially. (c) C7 transferred through the carotid sheath route reaches the midline. (d) The anterior division of lower trunk is transferred to the supra-sternal area via a subcutaneous tunnel from the deltopectoral wound

The confidence gained from the cadaver study allowed us to execute the direct repair in ten clinical cases of global brachial plexus injuries. The cC7 was transected distally at the divisions and delivered medial to scalenus anterior. Haemostat is used to create a plane through the carotid sheath between the CCA medially and the IJV with vagus nerve laterally. The subcutaneous plane is reached by retracting the sternocleidomastoid muscle laterally and the strap muscles medially. In each case, the passages could be created rapidly and uneventfully. The nerves were approximated with 8/0 nylon sutures in each case and the repair was performed comfortably in the subcutaneous plane [Figure 3a-c].

Postoperative treatment included immobilisation of the affected upper limb in stockinette sling with the arm across the chest and the elbow flexed more than 90°. [14]

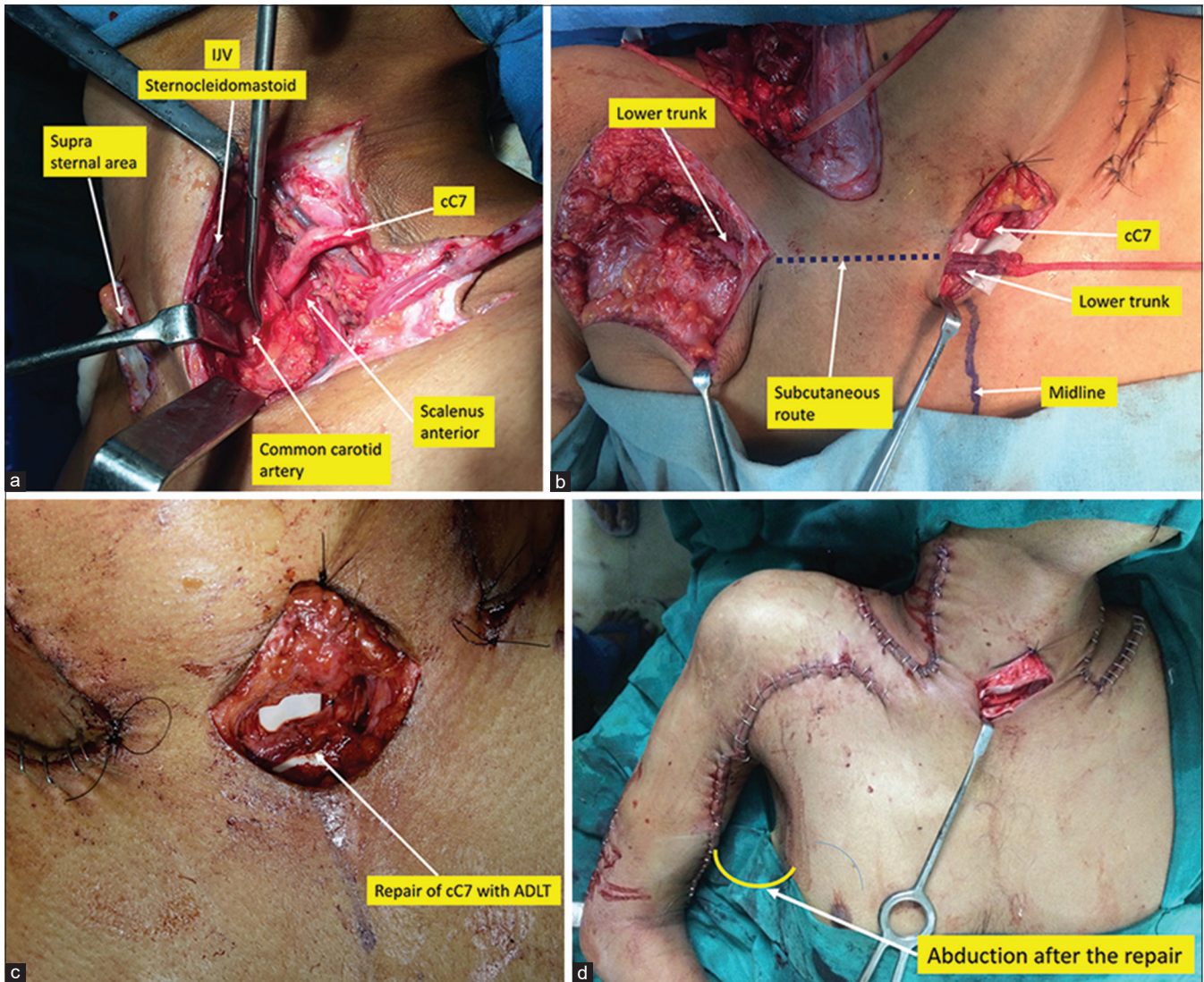
## RESULTS

The clinical outcome of this technique is awaited.

## DISCUSSION

Direct approximation of the cC7 to the lower trunk on the affected side was attempted and reported in 2010 by Feng *et al.* [15] Direct approximation was not possible in two out





**Figure 3:** (a) Intra operative photographs showing dissected the C7 root and its relation with sternocleidomastoid and carotid sheath structures. (b) The anterior division of lower trunk is transferred through a subcutaneous tunnel across the chest to lie adjacent to the C7 stump. (c) The microsurgical repair with 8/0 nylon sutures. (d) The repair can accommodate movement of the paralysed arm up to 30° of abduction

of the four patients and nerve grafts were interposed. They showed restoration of strong flexion of the fingers in half of the patients (2/4). Wang highlighted the advantages of achieving a direct repair of the cC7 to the lower trunk for the first time in his report in 2013. He demonstrated restoration of extrinsic finger flexion in 60% of cases. In addition, finger movement was recorded by 12 months from the operation, far earlier than the average time of 18 months seen with nerve grafting from the cC7 to the medial cord. The patient could activate the paralysed hand without exerting excessive force on the opposite upper limb and the final strength achieved was better than that seen previously with nerve grafting. We have adopted this strategy in the treatment of patients with global root avulsions since 2013. Our initial results have confirmed the observations described by Wang. However, our efforts, too, have been plagued by

difficulties and complications associated with the pre-spinal route. The end of the cC7 often reached the midline or just lateral to it on the paralysed side so that the mobilised lower trunk had to be approximated at an inconvenient location with retraction of the sternocleidomastoid muscle and of the carotid sheath. These difficulties prompted the authors to search for a simpler method of achieving a direct repair. In this endeavour, we found that mobilisation of the avulsed lower trunk allowed it to reach the suprasternal notch just as easily as it reached the medial border of the scalenus anterior. Hence, the repair could be performed there if the cC7 were to be delivered anteriorly instead of medially across the vertebral body as described previously. The ease of achieving this through the carotid sheath was demonstrated in the cadavers and this happy experience was repeated in each of the 10 clinical cases operated on

subsequently. The cC7 was delivered along a safe passage created through normal tissues without significant risk to any vital structure. The affected side lower trunk was passed along a subcutaneous tunnel across an uninjured area (unlike the earlier passage across the scarring in the posterior triangle). The repair was performed comfortably just above the sternum. Adduction of the arm helped to relieve the tension at the repair so that the nerves could be approximated using suitable fine suture materials. In none of these cases, did we need to shorten the humerus. At the end of the repair, the arm could be abducted to 30° without affecting the coaptation [Figure 3d].

Direct approximation of the donor and recipient nerves has been attempted using other methods such as shortening of the humerus. However, the recovered distal function is of little use because of the disfigurement and the compromised biceps function.<sup>[16]</sup> Feng *et al.*<sup>[15]</sup> had described a similar method where the lower trunk on the affected side was mobilised by sectioning the pectoral and cutaneous branches as well as the posterior division and delivered across the chest via a subcutaneous tunnel. They achieved a direct repair by harvesting the C7 long and turning it around the sternocleidomastoid muscle (after the division of a portion of the clavicular insertion). It was coapted to the opposite lower trunk at the level of the sternoclavicular junction on the normal side (2/4 – direct approximation was possible and in the remaining two patients nerve grafts were interposed).

The passage through the carotid sheath helps us attain the suprasternal notch in the midline or, occasionally, beyond the midline. To us, this appears to be a more direct route with no loss of length as the nerve emerges at the medial border of the sternocleidomastoid.

These various advantages have prompted the author to abandon the pre-spinal route and to recommend this passage across the carotid sheath in the safe plane between the IJV and vagus nerve laterally and the CCA medially.

### Acknowledgement

The authors would like to thank the Department of Anatomy, SBKS Medical Institute and Research Centre for allowing to perform cadaveric dissection.

### Financial support and sponsorship

Nil.

### Conflicts of interest

There are no conflicts of interest.

## REFERENCES

1. Waikukul S, Orapin S, Vanadurongwan V. Clinical results of contralateral C7 root neurotization to the median nerve in brachial plexus injuries with total root avulsions. *J Hand Surg Br* 1999;24:556-60.
2. Terzis JK, Kikkalis ZT. Selective contralateral c7 transfer in posttraumatic brachial plexus injuries: A report of 56 cases. *Plast Reconstr Surg* 2009;123:927-38.
3. Sammer DM, Kircher MF, Bishop AT, Spinner RJ, Shin AY. Hemi-contralateral C7 transfer in traumatic brachial plexus injuries: Outcomes and complications. *J Bone Joint Surg Am* 2012;94:131-7.
4. Gu YD. Contralateral C7 root transfer over the last 20 years in China. *Chin Med J (Engl)* 2007;120:1123-6.
5. Tu YK, Tsai YJ, Chang CH, Su FC, Hsiao CK, Tan JS. Surgical treatment for total root avulsion type brachial plexus injuries by neurotization: A prospective comparison study between total and hemicontrolateral C7 nerve root transfer. *Microsurgery* 2014;34:91-101.
6. Yang G, Chang KW, Chung KC. A Systematic review of contralateral C7 transfer for the treatment of traumatic brachial plexus injury: Part 1. Overall outcomes. *Plast Reconstr Surg* 2015;136:794-809.
7. Yang G, Chang KW, Chung KC. A Systematic review of outcomes of contralateral C7 transfer for the treatment of traumatic brachial plexus injury: Part 2. Donor-site morbidity. *Plast Reconstr Surg* 2015;136:480e-9e.
8. Wang SF, Li PC, Xue YH, Yiu HW, Li YC, Wang HH. Contralateral C7 nerve transfer with direct coaptation to restore lower trunk function after traumatic brachial plexus avulsion. *J Bone Joint Surg Am* 2013;95:821-7, S1-2.
9. Bhatia A. Experience with the Wang Technique. Podium Presentation at Club Narakas Brachial Plexus Meeting; 25-27 February, 2016.
10. Li W, Wang S, Zhao J, Rahman MF, Li Y, Li P, *et al.* Complications of contralateral C-7 transfer through the modified pre-spinal route for repairing brachial plexus root avulsion injury: A retrospective study of 425 patients. *J Neurosurg* 2015;122:1421-8.
11. Zhang CG, Gu YD. Contralateral C7 nerve transfer – Our experiences over past 25 years. *J Brachial Plex Peripher Nerve Inj* 2011;6:10.
12. McGuinness CN, Kay SP. The pre-spinal route in contralateral C7 nerve root transfer for brachial plexus avulsion injuries. *J Hand Surg Br* 2002;27:159-60.
13. Xu L, Gu Y, Xu J, Lin S, Chen L, Lu J. Contralateral C7 transfer via the pre-spinal and retropharyngeal route to repair brachial plexus root avulsion: A preliminary report. *Neurosurgery* 2008;63:553-8.
14. Gangurde BA, Thatte MR, Mokal N, Kumta S. Stockinette sling: "A simple method and patient friendly method of immobilisation of elbow and shoulder after a free functioning muscle transfer in global brachial plexus palsy." *Indian J Plast Surg* 2013;46:599-600.
15. Feng J, Wang T, Gu Y, Chen L, Zhang G, Zhu Y. Contralateral C7 transfer to lower trunk via a subcutaneous tunnel across the anterior surface of chest and neck for total root avulsion of the brachial plexus: A preliminary report. *Neurosurgery* 2010;66 6 Suppl: 252-63.
16. Yu ZJ, Sui S, Yu S, Huang Y, Sheng J. Contralateral normal C7 nerve transfer after upper arm shortening for the treatment of total root avulsion of the brachial plexus: A preliminary report. *Plast Reconstr Surg* 2003;111:1465-9.