

Case Report

Three rare cases of cutaneous phaeohyphomycosis

Aditi Chhonkar, Deepti Kataria, Swagata Tambe, Chitra S. Nayak

Department of Dermatology, Topiwala National Medical College and B. Y. L. Nair Hospital, Mumbai, Maharashtra, India

Address for correspondence: Dr. Aditi Chhonkar, Department of Skin and VD, Topiwala National Medical College and B. Y. L. Nair Hospital, OPD Building, Second Floor, OPD-14, Mumbai - 400 008, Maharashtra, India. E-mail: aditichhonkar@gmail.com

ABSTRACT

Phaeohyphomycosis is a chronic infectious condition caused by dematiaceous fungi which usually involve the skin and subcutaneous tissue. Subcutaneous phaeohyphomycosis is characterised by papulonodules, verrucous, hyperkeratotic or ulcerated plaques, cysts, abscesses, pyogranuloma, non-healing ulcers or sinuses. In India, commonly associated genera are *Exophiala*, *Phialophora*, *Cladosporium*, *Curvularia*, *Fonsecaea* and *Alternaria*. This condition involves the presence of brown-walled hyphal structures in the dermis and epidermis. Here, we are reporting a rare case series of three patients of phaeohyphomycosis with lesions on finger and dorsum of the hand.

KEY WORDS

Dematiaceous fungi; dorsum of hand; fungal infection; phaeohyphomycosis

INTRODUCTION

The term 'phaeohyphomycosis' was coined by Ajello *et al.* in the year 1974.^[1] Phaeohyphomycosis is a chronic infectious condition caused by dematiaceous fungi which usually involve the skin and subcutaneous tissue and occasionally the paranasal sinuses or the central nervous system.^[2]

CASE REPORTS

Case 1

A 42-year-old homemaker presented with a single asymptomatic lesion over the dorsum of the left hand since 10 months with no prior history of trauma. There was a history of gradual increase in size of the lesion over a period of time with no

history of discharge, pain, redness or bleeding from the lesion. There was also no history of restriction of joint movements. Clinical examination revealed the presence of a solitary, 4 cm × 3 cm sized, well-defined, non-transilluminating, firm, non-tender nodule on the dorsal aspect of the left hand with no evidence of regional lymphadenopathy. The nodule was not adherent to overlying skin [Figure 1].

Case 2

A 55-year-old homemaker came with complaints of a single, asymptomatic swelling over the left middle finger with a history of gradual increase in size since 2 years. The patient denied any apparent antecedent trauma, arthropod bite, family history or contact with a person with similar lesions. There was no history of discharge, pain, redness or bleeding

This is an open access article distributed under the terms of the Creative Commons Attribution-NonCommercial-ShareAlike 3.0 License, which allows others to remix, tweak, and build upon the work non-commercially, as long as the author is credited and the new creations are licensed under the identical terms.

For reprints contact: reprints@medknow.com

How to cite this article: Chhonkar A, Kataria D, Tambe S, Nayak CS. Three rare cases of cutaneous phaeohyphomycosis. Indian J Plast Surg 2016;49:271-4.

Access this article online	
Quick Response Code:	Website: www.ijps.org
	DOI: 10.4103/0970-0358.191321

from the lesion. There was also no history of restriction of joint movement or any difficulty in doing daily activities. Clinical examination revealed the presence of a solitary, 2 cm × 2 cm sized, well-defined, non-transilluminating, firm, non-tender cystic lesion on the dorsal aspect of left middle finger with no lymphadenopathy. The lesion was not adherent to overlying skin [Figure 2].

Case 3

A 52-year-old male, farmer by occupation, known case of pemphigus vulgaris on monthly dexamethasone cyclophosphamide pulse therapy, presented with a solitary asymptomatic swelling over right ring finger since 5 months with a gradual increase in size. There was no history of antecedent trauma, discharge, pain, redness or bleeding from the lesion. Examination revealed a solitary well-defined non-tender, mobile swelling of 3 cm × 3 cm over right ring finger with no overlying skin changes [Figure 3].

Differential diagnosis of ganglion cyst, phaeohyphomycosis and myxoid cyst was considered in all the three cases.

In all the three cases, routine haemogram, liver and renal function tests and biochemical tests were within normal limit. Fine-needle aspiration cytology from the lesions in all three cases was suggestive of inflammatory lesion of fungal origin. Acid-fast bacilli smear was negative. Ten percent KOH mount showed hyaline and dematiaceous tortuous vesiculated branching fungal hyphal filaments in all the three cases [Figure 4].

Fungal culture showed growth of dematiaceous fungus species on Sabouraud's dextrose agar [Figure 5]. Punch biopsy specimens obtained from the lesions revealed acanthotic epidermis with perivascular lymphohistiocytic infiltration in dermis on haematoxylin and eosin staining [Figures 6 and 7]. Periodic acid–Schiff (PAS) stain showed fragmented bits of granulation tissue and numerous colonies of pigmented hyphal structures suggestive of phaeohyphomycosis [Figures 8 and 9]. Hence, a final diagnosis of phaeohyphomycosis was made in all the three cases. Cases 2 and 3 received oral itraconazole 200 mg twice a day for a minimum of 4 months followed by surgical excision [Figures 10 and 11]. There was no recurrence of lesions in next 6 months after surgical excision. Case 1 was started on oral itraconazole 200 mg twice a day, but the patient was lost to follow-up.

DISCUSSION

Phaeohyphomycosis is caused by brown pigmented fungi

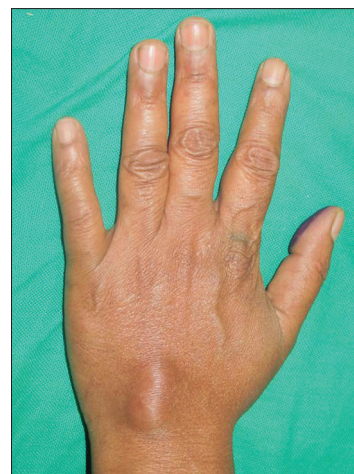

Figure 1: Solitary, 4 cm × 3 cm sized, well-defined, firm, non-tender nodule on dorsal aspect of left hand

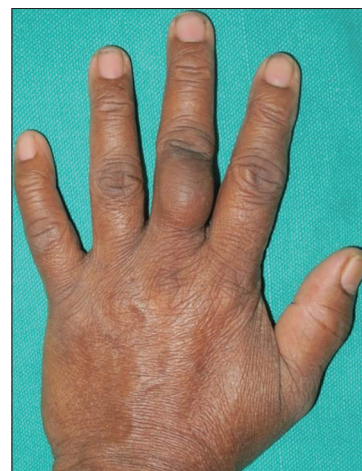

Figure 2: Solitary, 2 cm × 2 cm sized, well-defined, firm, non-tender cystic lesion on dorsal aspect of left middle finger

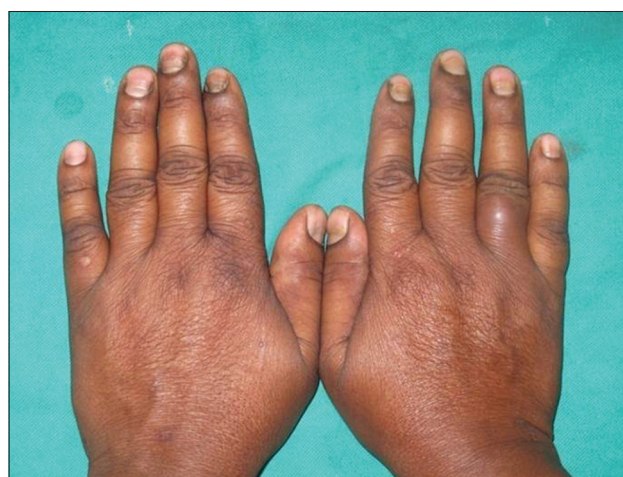


Figure 3: Solitary well-defined non-tender, mobile swelling of 3 cm × 3 cm over right ring finger

containing melanin in their cell wall. Melanin scavenges free radicals and hypochlorite produced by the phagocytic

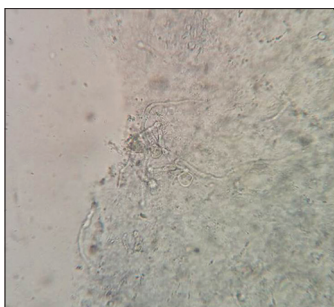


Figure 4: Ten percent KOH mount showing hyaline and dematiaceous tortuous vesiculated branching fungal hyphal filaments



Figure 5: Growth of dematiaceous fungus on Sabouraud dextrose agar media

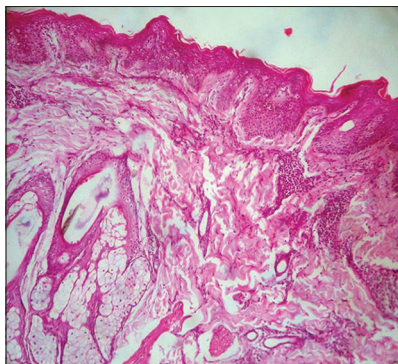


Figure 6: Acanthotic epidermis with perivascular lymphohistiocytic infiltration in dermis on H and E, ×100

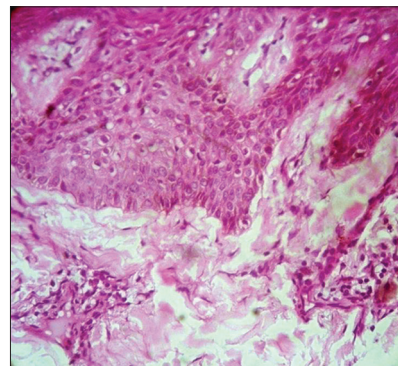


Figure 7: Acanthotic epidermis with perivascular lymphohistiocytic infiltration in dermis on H and E, ×40

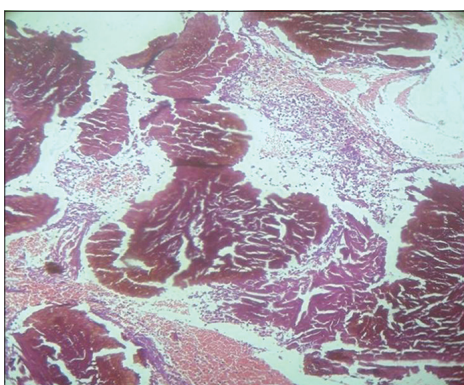


Figure 8: Fragmented bits of granulation tissue and numerous colonies of pigmented hyphal structures on periodic acid–Schiff stain (×10), suggestive of phaeohyphomycosis

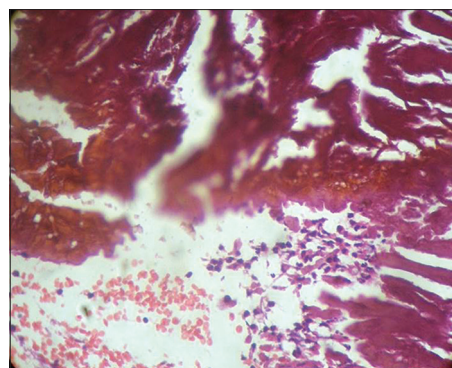


Figure 9: Fragmented bits of granulation tissue and numerous colonies of pigmented hyphal structures on periodic acid–Schiff stain (×40), suggestive of phaeohyphomycosis

cells and also binds to hydrolytic enzymes, and this makes it possible for the fungus to cause infection even in immunocompetent host.^[3] Current prevalence is unknown, but in recent years, the number of cases has increased in immunosuppressed patients. Depending on the extent and depth of invasion, the disease is classified as surface, subcutaneous, systemic and cerebral.^[4] Cutaneous and subcutaneous phaeohyphomycosis is usually secondary to direct inoculation, often succeeded by trauma. Subcutaneous phaeohyphomycosis occurs in all climates throughout the world. The climate ranges from tropical to temperate in India, and the disease has been reported

from North to South, except for the Western and Eastern regions of the country.^[2]

Males are commonly affected because of their outdoor occupation. The highest incidence is seen in the third and fifth decades of life.^[5] According to many published cases, many species are involved although they mostly belong to the genera *Exophiala*, *Alternaria*, *Phialophora*, *Curvularia* and *Fonsecaea*.^[6] However, more recently, in a case report, a new species of dematiaceous fungus, *Phialemoniopsis ocularis*, has been implicated in chronic subcutaneous phaeohyphomycosis.^[7]

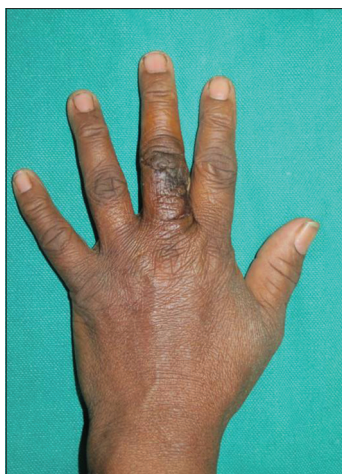

Figure 10: Post-excision patient 1

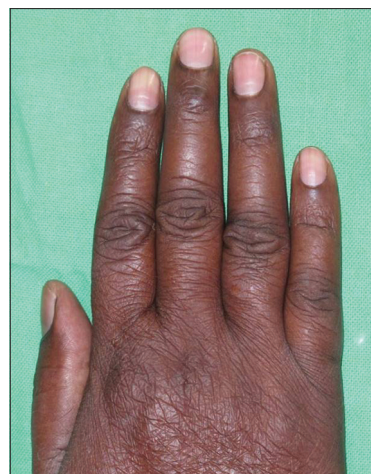

Figure 11: Post-excision

Following a chronic course, it begins with the appearance of small papules which evolve into a cyst and ultimately results in the formation of nodules or indurated plaques.^[6,8] The disease most commonly presents as cysts, commonly seen in the phalanges, or well-demarcated, slow-growing nodules. The lesions are located in exposed parts of the body such as the lower and upper limbs. The most common subcutaneous lesion is the cystic form which is characterised as a firm lesion with well-defined edges and intact skin surface.^[4] The varied presentations are papulonodules, verrucous, hyperkeratotic or ulcerated plaques, cysts, abscesses, pyogranuloma, non-healing ulcers or sinuses.^[2,9] Differential diagnoses include lipomas, epidermal cysts, bacterial abscesses, fibroids, foreign body granuloma and squamous cell carcinoma.^[10]

Laboratory diagnosis includes isolation of fungal hyphae on potassium hydroxide mounts and culture on Sabouraud's dextrose agar.^[11] Histopathologically, the lesions show brown-walled septate hyphae or yeast or a combination of both in tissue. The Fontana-Masson stain (specific for melanin), PAS and Gomori methenamine silver stains can be used to confirm the diagnosis.^[11]

Local infection may be treated with excision or cryotherapy or in combination with antifungals.^[2] Dematiaceous fungi are most susceptible to voriconazole, itraconazole and posaconazole, whereas ketoconazole and fluconazole have limited activity. Amphotericin-B and 5-flucytosine may also be used as treatment modality. Systemic disease is often refractory to therapy.^[11] Successful treatment of these lesions includes complete excision. In case of incomplete resection or relapse, oral itraconazole is still considered as the standard treatment for this condition.^[6]

Financial support and sponsorship

Nil.

Conflicts of interest

There are no conflicts of interest.

REFERENCES

1. Ajello L, George LK, Steigbigel RT, Wang CJ. A case of phaeohyphomycosis caused by new species of *Phialophora*. *Mycology* 1974;66:490-8.
2. Sharma NL, Mahajan V, Sharma RC, Sharma A. Subcutaneous phaeohyphomycosis in India – A case report and review. *Int J Dermatol* 2002;41:16-20.
3. Mishra D, Singal M, Rodha MS, Subramanian A. Subcutaneous phaeohyphomycosis of foot in an immunocompetent host. *J Lab Physicians* 2011;3:122-4.
4. Perusquía-Ortiz AM, Vázquez-González D, Bonifaz A. Opportunistic filamentous mycoses: Aspergillosis, mucormycosis, phaeohyphomycosis and hyalohyphomycosis. *J Dtsch Dermatol Ges* 2012;10:611-21.
5. Ramos-e-Silva M, Castro MC. *Fundamentos de Dermatologia*. 2nd ed. Rio de Janeiro: Atheneu; 2010.
6. Revankar SG. Phaeohyphomycosis. *Infect Dis Clin North Am* 2006;20:609-20.
7. Perdomo H, Sutton DA, García D, Fothergill AW, Gené J, Cano J, *et al.* Molecular and phenotypic characterization of *Phialemonium* and *Lecythophora* isolates from clinical samples. *J Clin Microbiol* 2011;49:1209-16.
8. Isa-Isa R, García C, Isa M, Arenas R. Subcutaneous phaeohyphomycosis (Mycotic cyst). *Clin Dermatol* 2012;30:425-31.
9. Caligiore RB, de Resende MA, Dias-Neto E, Oliveira SC, Azevedo V. Dematiaceous fungal pathogens: Analysis of ribosomal DNA gene polymorphism by polymerase chain reaction-restriction fragment length polymorphism. *Mycoses* 1999;42:609-14.
10. Lacaz CS, Porto E, Martins JE, Hiens-Vaccari EM, Melo NT. Feo-hifomycose. In: Lacaz CS, editor. *Tratado de Micologia Médica*. 9th ed. São Paulo: Sarvier; 2002. p. 520-61.
11. Revankar SG. Dematiaceous fungi. *Mycoses* 2007;50:91-101.