

## Salvage oesophageal reconstruction that withstood the test of time

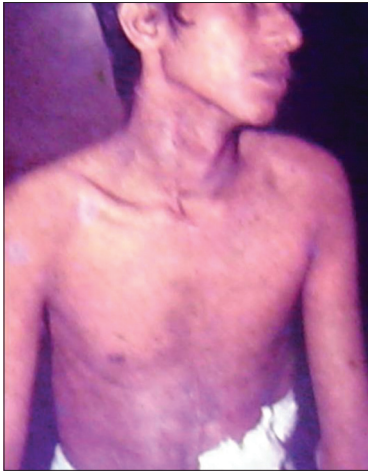Sir,

We wish to present a unique case of total oesophageal reconstruction using tubed skin and myocutaneous flaps, performed in 1989 by the senior authors. The patient was symptom-free, feeding satisfactorily and socially well rehabilitated for the past 25 years. This case was brought to our attention while he presented with a small fistula below the original pharyngostomy site following active pulmonary tuberculosis.

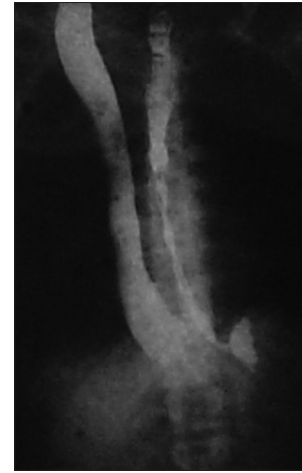Twenty-five years back, this patient had sustained extensive corrosive stricture of the oesophagus [Figure 1]. A colon transfer had failed and he was being managed with a pharyngostomy and feeding gastrostomy. Once the general condition of the patient was stabilised, he was subjected to a multistage segmental neo-oesophageal reconstruction that took a year to complete. Upper third of the neo-oesophagus was reconstructed with a reversed, tubed deltopectoral flap which was tunnelled subcutaneously into the cervical region and anastomosed to the pharyngostoma. Flap donor site was skin grafted. The middle third of neo-oesophagus was constructed with a reversed, tubed pectoralis major myocutaneous flap. Subsequently, skin of the lower chest wall was fashioned into a Gillies tube pedicle flap and connected to the remnant of transferred colon [Figure 2]. An average interval of 3 months was maintained between each stage of the reconstruction.

The flaps were meticulously planned to give the widest possible lumen, and precautions were taken to avoid strictures at the anastomotic sites. Following the release of a minor synechia at the proximal anastomosis, the patient started feeding adequately. The patient was then followed up with barium swallows and the conduit appeared smooth and strictureless [Figure 3]. Since the neo-oesophagus lacked peristalsis, the patient was propelling the swallowed food forwards with a gentle massage, aided by gravity. Except for a minimal redundancy of the tubed conduit, he was symptom-free and feeding adequately till the development of the fistula. He has completed antituberculous drug therapy and undergone an oesophagoscopy with dilatation of a minor inflammatory stricture around the fistulous tract. However, the fistulous tract persisted and a subsequent biopsy revealed a well-differentiated squamous cell carcinoma. The patient has now undergone a resection of the involved segment followed by chemoradiation [Figure 4].

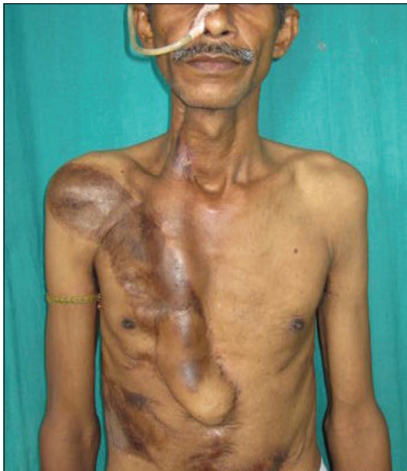A literature search from 1980s to 1990s showed that four types of pharyngo-oesophageal reconstructions were employed at that time, namely, (1) subcutaneous or intrathoracic interposition or migration of alimentary tract, either stomach or colon, (2) free flaps of jejunum or colon, (3) local or regional skin flaps and (4) free skin grafts.<sup>[1]</sup> Wherever facilities for microvascular surgery exists, a free jejunal interposition flap is considered to be the best reconstructive option.<sup>[1-4]</sup> However, salvage reconstruction of neo-oesophagus with skin and myocutaneous flap still



**Figure 1:** An 18-year-old patient with oesophageal stricture on feeding gastrostomy before reconstruction



**Figure 2:** Barium swallow at the end of reconstruction showing smooth, stricture less conduit of neo-oesophagus. A trickle of Barium across the corrosive stricture can also be seen

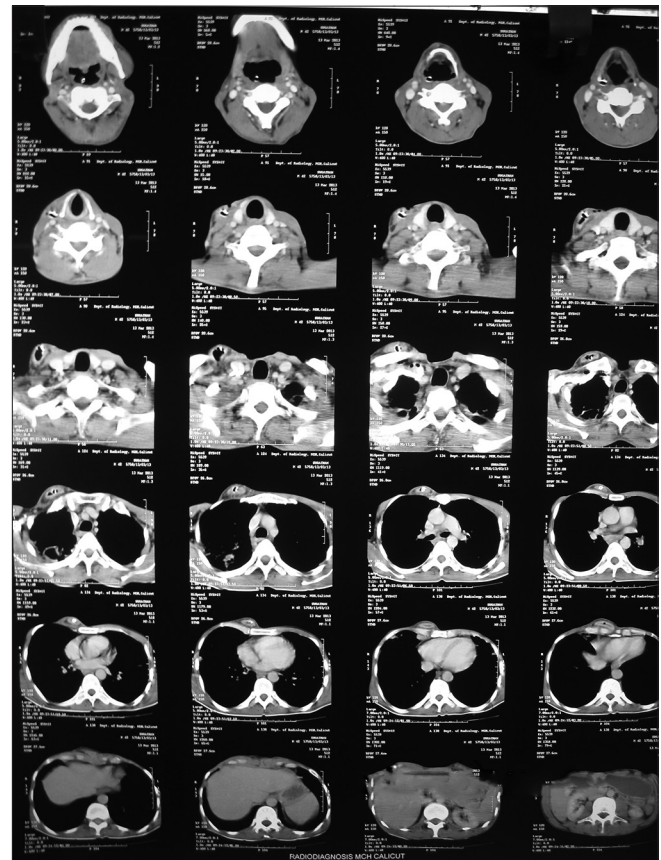


**Figure 3:** Patient after 25 years with the reconstructed neo-oesophagus. A fistula can be seen at the lower neck region

has a role when free flaps or pull-ups fail or when there is extensive substernal scarring.<sup>[2,4,5]</sup>

We wish to highlight the long-term success of this salvage reconstruction from a centre where facilities for microsurgery were non-existent. By carefully planned and meticulously executed simple-staged reconstructive steps, the young patient could be restored to oral feeding and socially well rehabilitated by avoiding the life-long stigma of a gastrostomy. There is paucity of literature on the long-term survival rates of patients with salvage reconstruction of neo-oesophagus; however, we believe that a reconstruction as in our patient that withstood the test of time for 25 long years is truly unique and deserves special credit.

**Financial support and sponsorship**  
Nil.



**Figure 4:** Recent computed tomography scan showing the reconstructed oesophagus with inflammation in the proximal segment

### Conflicts of interest

There are no conflicts of interest.

**Sheeja Rajan T. M, Rajesh S<sup>1</sup>, Benoy Varghese,  
P. V. Ramnarayan<sup>1</sup>**

Departments of Plastic and Reconstructive Surgery and  
Cardiothoracic Surgery, Government Medical College,  
Kozhikode, Kerala, India

**Address for correspondence:**

Dr. Sheeja Rajan T. M, Department of Plastic and  
Reconstructive Surgery, Government Medical College,  
Kozhikode, Kerala, India.  
E-mail: sheejarajantm@gmail.com

## REFERENCES

1. Jurkiewicz MJ. Reconstructive surgery of the cervical esophagus. *J Thorac Cardiovasc Surg* 1984;88 (5 Pt 2):893-7.
2. Oki M, Asato H, Suzuki Y, Umekawa K, Takushima A, Okazaki M, *et al.* Salvage reconstruction of the oesophagus: A retrospective study of 15 cases. *J Plast Reconstr Aesthet Surg* 2010;63:589-97.
3. Chana JS, Chen HC, Sharma R, Gedebo TM, Feng GM. Microsurgical reconstruction of the esophagus using supercharged pedicled jejunum flaps: Special indications and pitfalls. *Plast Reconstr Surg* 2002;110:742-8.
4. Okazaki M, Asato H, Takushima A, Nakatsuka T, Ueda K, Harii K. Secondary reconstruction of failed esophageal reconstruction. *Ann Plast Surg* 2005;54:530-7.
5. Jenkins HA, Canalis RF, Ward PH. A technique for pharyngeal reconstruction in heavily irradiated patients. *Laryngoscope* 1979;89:366-71.

This is an open access article distributed under the terms of the Creative Commons Attribution-NonCommercial-ShareAlike 3.0 License, which allows others to remix, tweak, and build upon the work non-commercially, as long as the author is credited and the new creations are licensed under the identical terms.

Access this article online	
Quick Response Code: 	Website: <a href="http://www.ijps.org">www.ijps.org</a>
	DOI: 10.4103/0970-0358.191315

**How to cite this article:** Sheeja Rajan TM, Rajesh S, Varghese B, Ramnarayan PV. Salvage oesophageal reconstruction that withstood the test of time. *Indian J Plast Surg* 2016;49:291-3.