

## Case Report

# Superficial upper limb vasculature and its surgical implications

Richa Gupta, Anjali Aggarwal, Tulika Gupta, Harjeet Kaur, Sunil Gaba<sup>1</sup>, Daisy Sahni

Departments of Anatomy and <sup>1</sup>Plastic and Reconstructive Surgery, Postgraduate Institute of Medical Education and Research, Chandigarh, India

**Address for correspondence:** Dr. Anjali Aggarwal, Department of Anatomy, Postgraduate Institute of Medical Education and Research, Sector 12, Chandigarh - 160 012, India. E-mail: anjli\_doc@yahoo.com

### ABSTRACT

Any kind of anatomical variation whether encountered during cadaveric dissections or routine clinical or surgical procedures needs to be reported and taken into account. This can be quite helpful in planning surgeries accordingly and avoid disastrous complications. During routine cadaveric dissection, authors found a superficial course of arteries of the arm as well as the forearm, unilaterally in one cadaver. In this case, there were two brachial arteries - superficial and deep. Superficial brachial artery terminated into superficial radial and superficial ulnar artery. Deep brachial artery was trifurcated into common interosseous, medial and lateral artery branches. Authors have also discussed the developmental anomaly, which could have led to the observed morphological variation. Superficial vessels can provide large size pedicles for raising flaps for local reconstructive surgeries in the region of axilla, elbow, wrist or hand, or other regions.

### KEY WORDS

Artery; brachial; radial; superficial; ulnar

### INTRODUCTION

**D**iversion from the typical arterial pattern of the upper limb is not a very uncommon finding, but superficially lying vasculature of the whole of the upper limb region is a very interesting and rare finding. Although individual incidences of superficial brachial artery (SBA) 0.66–1.25%, superficial radial artery (SRA) (14.26–15%) or superficial ulnar artery (SUA) 0.67–9.38% have been reported from time to time,<sup>[1-4]</sup> but till date to the best of our knowledge, we could not find

literature on simultaneous presence of all these vessels superficially. This finding as reported in the current study has very strong clinical implications. Any kind of trauma either due to accident or upper limb surgeries or even routine procedures such as intravenous cannulation or vaccination can lead to damage of these vessels leading to ischaemic necrosis and gangrene of muscles of the arm, forearm or hand region. On the contrary, the occurrence of such large-sized superficially lying arteries provide large-sized pedicles for local reconstructive surgeries in

Access this article online	
Quick Response Code: 	Website: www.ijps.org
	DOI: 10.4103/0970-0358.191314

This is an open access article distributed under the terms of the Creative Commons Attribution-NonCommercial-ShareAlike 3.0 License, which allows others to remix, tweak, and build upon the work non-commercially, as long as the author is credited and the new creations are licensed under the identical terms.

**For reprints contact:** reprints@medknow.com

**How to cite this article:** Gupta R, Aggarwal A, Gupta T, Kaur H, Gaba S, Sahni D. Superficial upper limb vasculature and its surgical implications. *Indian J Plast Surg* 2016;49:258-60.

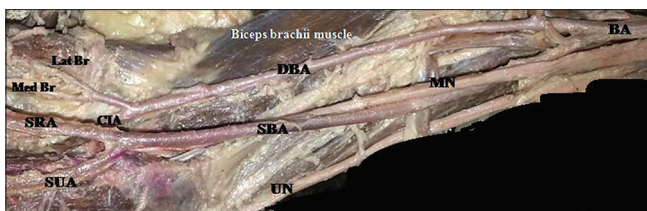
the shoulder, elbow, wrist or hand region, etc. Thus, prior knowledge of such variations may be quite useful during surgeries, interpreting angiograms as well as to avoid complications during simple interventional procedures on the upper limb vessels.

## CASE REPORT

In the present case study, authors observed variations in course and branching pattern of the brachial artery in the left upper extremity of 82-year-old male cadaver during routine dissection.

Brachial artery was seen medial to the median nerve in the proximal arm region. At the level of the middle one-third of the arm, bifurcation of brachial artery into medial and lateral branches was observed. Medial branch crossed median nerve to become SBA at lower one-third of the arm, whereas lateral branch which was located on the deeper plane in relation to median nerve continued as deep brachial artery (DBA). At the level of apex of cubital fossa, SBA was seen dividing into SUA and SRA [Figure 1].

In the region of lower two-third of the arm, DBA was the main source of vascular supply to all the surrounding muscles. At the level of insertion of biceps brachii tendon, DBA was trifurcated into common interosseous, medial and lateral branch. Common interosseous artery after a short course of about 1 cm, divided into anterior and posterior interosseous artery which followed their normal course. The anterior interosseous artery was seen supplying the majority of superficial as well as deep muscles in the flexor compartment of the forearm. Posterior interosseous artery passed through an opening between oblique cord and interosseous membrane to enter the posterior compartment and supplied the muscles of back of forearm. Medial branch was a



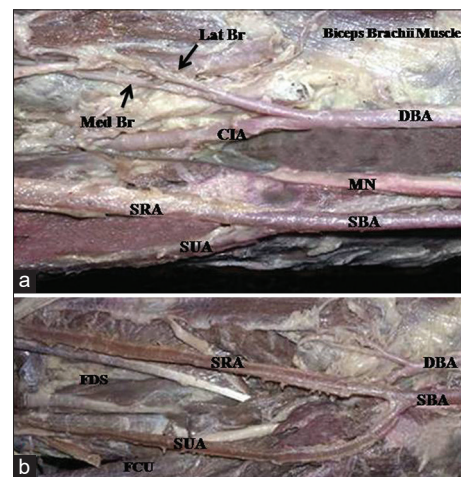
**Figure 1:** Volar aspect of the right arm showing brachial artery bifurcating into medial and lateral branches at the middle one-third of arm. Medial branch continuing as superficial brachial artery and lateral branch as a deep brachial artery in the arm. MN: Median nerve, UN: Ulnar nerve, Lat Br: lateral branch, Med Br: Middle branch, SRA: Superficial radial artery, SUA: Superficial ulnar artery, CIA: Common interosseous artery, DBA: Deep brachial artery, SBA: Superficial brachial artery, BA: Brachial artery

comparative smaller branch supplying pronator teres muscle. Lateral branch supplied brachioradialis muscle and extensor carpi radialis longus muscle [Figure 2].

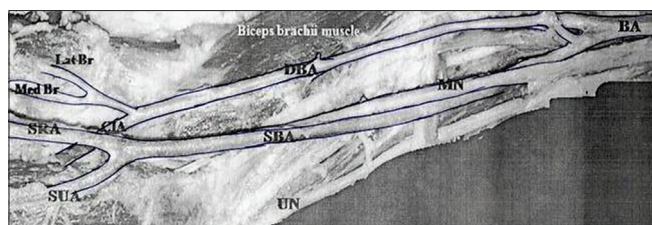
In the forearm, SUA was seen first lying in relation to pronator teres muscle and then, flexor carpi ulnaris muscle and was not accompanied by ulnar nerve as nerve was lying on the deeper plane. However, at the level of wrist both structures came to lie adjacent to each other and thereafter followed normal course as that followed by normal ulnar artery in the palm. SRA coursed first in the middle of forearm, then proceeding laterally at the level of the middle of forearm where it came to lie superficial to the tendon of flexor carpi radialis and brachioradialis muscle. Then, SRA accompanied by superficial radial nerve entered the snuff box and thereafter, followed normal course as that of normal radial artery in the palm [Figures 2 and 3].

## DISCUSSION

Any kind of defect in the embryological axis artery leads to various morphological variations in the vessels. SBA is an embryonic structure which is replaced by a definitive brachial artery in adults. However, if it persists in adult life, it anastomoses with the DBA, which further bifurcates into radial and interosseous arteries and SBA



**Figure 2:** (a) In the cubital fossa, the superficial brachial artery is giving rise to two terminal branches: superficial ulnar artery and superficial radial artery. The deep brachial artery is giving rise to common interosseous artery, medial branch and lateral branch. (b) Volar aspect of the right forearm showing superficial ulnar artery and superficial radial artery following superficial course over the superficial muscles of flexor compartment of the forearm, i.e., Flexor carpi ulnaris, Flexor digitorum superficialis. MN: Median nerve, Lat Br: lateral branch, Med Br: Middle branch, SRA: Superficial radial artery, SUA: Superficial ulnar artery, CIA: Common interosseous artery, DBA: Deep brachial artery, SBA: Superficial brachial artery, FDS: Flexor digitorum superficialis, FCU: Flexor carpi ulnaris



**Figure 3:** Sketch diagram showing the course of superficial vessels. MN: Median nerve, UN: Ulnar nerve, Lat Br: lateral branch, Med Br: Middle branch, SRA: Superficial radial artery, SUA: Superficial ulnar artery, CIA: Common interosseous artery, DBA: Deep brachial artery, SBA: Superficial brachial artery, BA: Brachial artery

terminates as ulnar artery.<sup>[5-7]</sup> However, in this study, DBA was seen continuing as common interosseous artery and SBA divided into SRA and SUA. Clinicians and surgeons should be well aware of such anatomical variants.

The previous studies have observed three kinds of variations in the course of SBA, which were SBA bifurcating into radial and ulnar arteries (3.6%) or continuing as SRA (5.9%) or SUA (2.8%).<sup>[8]</sup> Authors, in the current case study, have observed an entirely different and unique branching pattern of upper limb vessels. This pattern has not been described by the previous studies and has many clinical implications. Superficial upper limb arteries can be misinterpreted as vein, thus leading to traumatic injury during intravenous drug administration, venipuncture or percutaneous brachial catheterisation. The superficial course of these vessels also makes them more susceptible to cut injuries in arm, forearm leading to severe bleeding.<sup>[9]</sup> Similarly, accidental injection of any kind of drug in these vessels can result in reflex vascular occlusion leading to disastrous gangrene of forearm and hand. Superficial arteries can also cause misinterpretation of the angiographic images. Orthopaedicians should be well aware of such variant course of upper limb vessels while treating ruptured bicipital tendon.<sup>[10]</sup> However, in reconstructive surgeries, the presence of superficial vessels can prove to be a boon as these vessels can provide

large size pedicles for raising flaps for local reconstructive surgeries in the axilla, elbow, wrist or hand region. Thus, variations in the topographical anatomy of brachial artery are important not only for surgeons but also for clinicians and radiologists in the day-to-day practice. Such case studies can be quite helpful to minimise the complication rate during various kinds of surgeries as well as routine clinical practice.

### Financial support and sponsorship

Nil.

### Conflicts of interest

There are no conflicts of interest.

### REFERENCES

1. Adachi B. Das arterien system des Japaner (the arterial system of the Japanese). Kyoto 1928;1:205-10.
2. Karlsson S, Niechajev IA. Arterial anatomy of the upper extremity. *Acta Radiol Diagn (Stockh)* 1982;23:115-21.
3. Chin KJ, Singh K. The superficial ulnar artery – A potential hazard in patients with difficult venous access. *Br J Anaesth* 2005;94:692-3.
4. McCormack LJ, Cauldwell EW, Anson BJ. Brachial and antebrachial arterial patterns; a study of 750 extremities. *Surg Gynecol Obstet* 1953;96:43-54.
5. Rodríguez-Baeza A, Nebot J, Ferreira B, Reina F, Pérez J, Sañudo JR, *et al.* An anatomical study and ontogenetic explanation of 23 cases with variations in the main pattern of the human brachio-antebrachial arteries. *J Anat* 1995;187(Pt 2):473-9.
6. Yalcin B, Kocabiyik N, Yazar F, Kirici Y, Ozan H. Arterial variations of the upper extremities. *Anat Sci Int* 2006;81:62-4.
7. Manners-Smith T. The limb arteries of primates: Part I. *J Anat Physiol* 1910;44(Pt 3):271-302.
8. Keen JA. A study of the arterial variations in the limbs, with special reference to symmetry of vascular patterns. *Am J Anat* 1961;108:245-61.
9. Funk GF, Valentino J, McCulloch TM, Graham SM, Hoffman HT. Anomalies of forearm vascular anatomy encountered during elevation of the radial forearm flap. *Head Neck* 1995;17:284-92.
10. Jacquemin G, Lemaire V, Medot M, Fissette J. Bilateral case of superficial ulnar artery originating from axillary artery. *Surg Radiol Anat* 2001;23:139-43.