

## Case Report

# Algorithmic surgical enhancement of function after finger revascularisation

Luis Landin, Pedro Bolado, Maria-Angeles Gajete, Alvaro Gonzalez-Miranda, Jorge Bonastre

Division of Plastic and Reconstructive Surgery, Hospital Universitario La Paz, Madrid, Spain

**Address for correspondence:** Dr. Luis Landin, Division of Plastic and Reconstructive Surgery, University Hospital La Paz, Paseo de la Castellana, 261, 28046 Madrid, Spain. E-mail: landinsurgery@gmail.com

### ABSTRACT

Secondary surgical procedures can improve the function of revascularised and replanted digits. We describe the case of a patient who underwent multidigit revascularisation and replantation following a saw injury at flexor tendon Zone II. To achieve maximal functional improvement after finger revascularisation, we performed secondary surgical procedures in an order that was determined by following a reconstructive decision procedure that covered late revascularisation, nerve reconstruction, pedicled vascularised joint transfer, staged flexor tendon reconstruction and skin revision. Performing the procedures in this manner ensured overall safety. The patient's disabilities of the arm, hand and shoulder questionnaire score improved by 45 points, and the patient was able to return to work with an almost complete range of motion.

### KEY WORDS

Finger; replantation; tendon; vascularised joint transfer

### INTRODUCTION

Following replantation and revascularisation of digits, functional outcome is often not satisfactory, so secondary surgical procedures are necessary to improve the final result.<sup>[1]</sup>

Few reports have focused on the order in which secondary procedures should be performed; this is often left to the surgeons to decide on the basis of

their experience.<sup>[2,3]</sup> Wang reviewed 1227 cases of upper limb replantation published between 1977 and 2000 and designed a decision procedure for determining the order and appropriateness of performing a variety of secondary procedures including soft tissue stabilisation, bone synthesis, sensory restoration, joint flexibilisation and tendon reconstruction [Figure 1].<sup>[4]</sup> However, the utility of such decision procedure has not been corroborated by further reports in the clinical setting.

Video Available on: [www.ijps.org](http://www.ijps.org)

#### Access this article online

Quick Response Code:



Website:

[www.ijps.org](http://www.ijps.org)

DOI:

10.4103/0970-0358.191313

This is an open access article distributed under the terms of the Creative Commons Attribution-NonCommercial-ShareAlike 3.0 License, which allows others to remix, tweak, and build upon the work non-commercially, as long as the author is credited and the new creations are licensed under the identical terms.

**For reprints contact:** [reprints@medknow.com](mailto:reprints@medknow.com)

**How to cite this article:** Landin L, Bolado P, Gajete MA, Gonzalez-Miranda A, Bonastre J. Algorithmic surgical enhancement of function after finger revascularisation. *Indian J Plast Surg* 2016;49:239-44.

We tested the hypothesis that using Wang's decision procedure to determine the order in which secondary procedures should be performed facilitated improvement of function and avoided surgical complications. In the case reported herein, we used and illustrated how the different techniques were used. Sensitivity, range of motion (ROM) and patient-reported outcomes were the main measures of outcome.

## CASE REPORT

The patient gave his informed consent for the publication of this case report. The patient was a 20-year-old male who had suffered a saw injury at flexor tendon Zone II of his dominant hand. The thumb was amputated and suitable for replantation. The fifth finger was not available. The rest of the long fingers were devascularised. Unfortunately, 6 days after revascularisation of the second to fourth fingers and replantation of the thumb, an infection of the wound manifested. All the venous grafts for the arterial bypasses to the fingers were embedded in pus and failed, as did the tenorrhaphies and neurorrhaphies. Although cultures gave negative results, the wound was insufficiently clean to accept new bypasses. In addition, the index finger was barely vascularised; a wait-and-see policy was adopted towards this digit. Three weeks after debridement and empiric systemic antibiotics, all wounds had healed, and all fingers survived. However, the index finger was pale, cold and presented very slow capillary refill (figure unavailable). The patient scored 65 in the disabilities of the arm, hand and shoulder (DASH) questionnaire.

Following the decision procedure described by Wang, first, the thoracodorsal bundle was transferred microsurgically to the index finger to enhance index vascular viability. In brief, the thoracodorsal artery and vein were dissected for 15 cm and a muscle cuff 2 cm wide × 3 cm long was preserved at its tip to monitor the permeability of the bundle. The subscapular artery and one vein were anastomosed to the radial vessels laterally at the anatomic snuffbox, and the bundle was tunneled subcutaneously to the radial side of the index finger [Figure 2].<sup>[5]</sup> The implanted muscle cuff received a skin graft. In addition, grafts from the superficial peroneal nerve were used to reconstruct gaps in the collateral nerves of the index and ring fingers. After healing was complete, the index finger showed good vascularisation [Figure 3]. The patient was then referred for therapy that focused on oedema absorption and passive joint mobilisation.

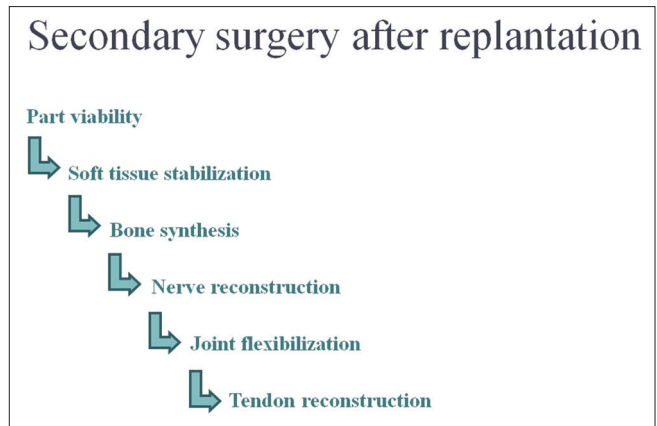


Figure 1: The decision-theoretic approach to functional enhancement after upper limb replantation published by Wang *et al.*

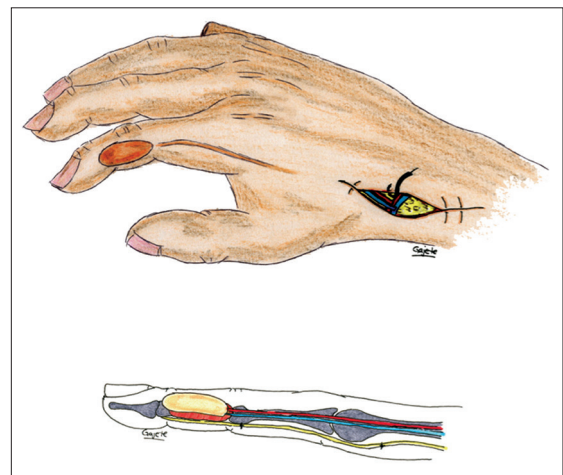


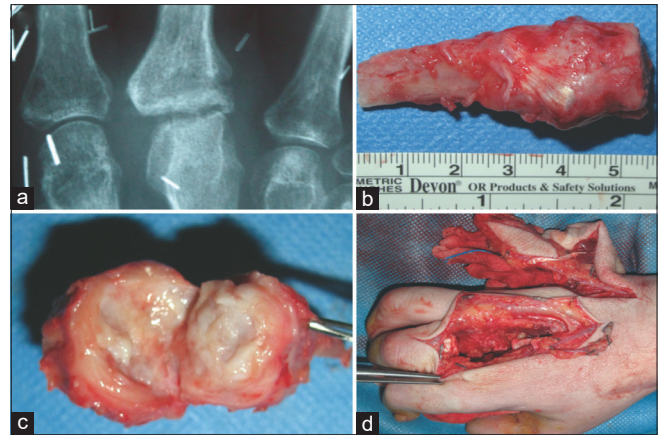
Figure 2: The technique described by Hussli *et al.* was used to transfer the thoracodorsal bundle to the radial artery at the anatomic snuffbox. The bundle was accompanied by a muscle cuff, which was implanted and skin-grafted at the middle phalanx. In the same operation, we used the superficial peroneal nerve to reconstruct the proper digital nerve

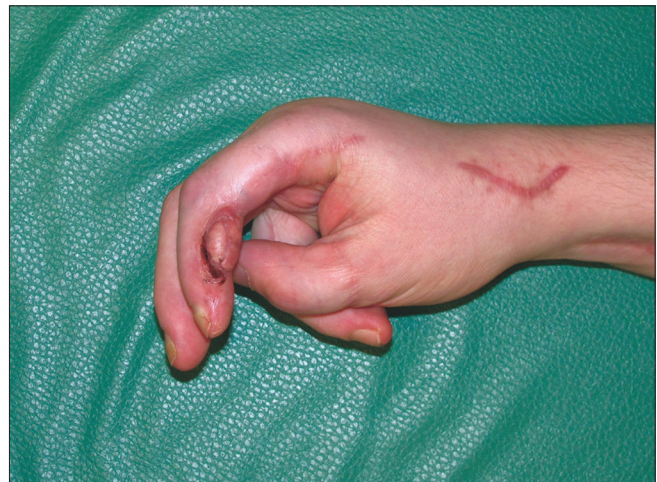

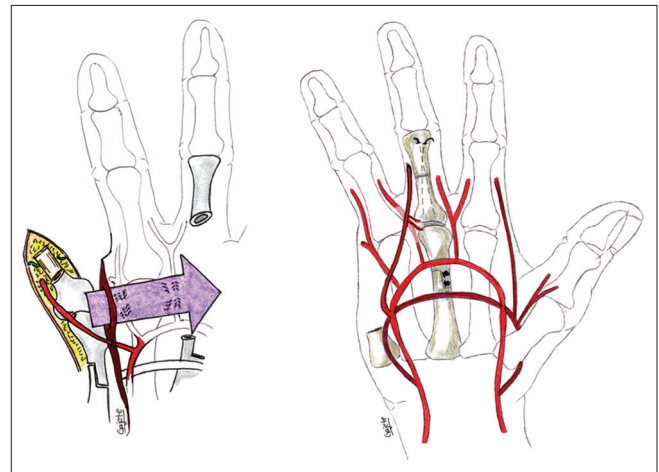
Figure 3: Post-operative appearance of the index finger after late revascularisation. Note that the thumb was replanted, the second to fourth fingers survived the injury and the tip of the fifth finger was not replanted

Eight weeks later the metacarpophalangeal (MCP) joints in all fingers were fully supple. However, under radiological examination, the third MCP joint showed signs of erosion [Figure 4a]. Following Wang's decision procedure, surgical exploration of the joint showed denuded and scarred cartilage [Figure 4b and c]. The joint was removed and a full-thickness defect was created. The defect was reconstructed by transposing a full-thickness MCP joint from the fifth digit with the middle MCP joint [Figures 4d and 5]. This transposition included the fat volar to the MCP joint, the volar plate and the joint and the intrinsic tendons to the extensor hood. The joint was vascularised based on the ulnar collateral artery of the little finger [Figure 5]. A metacarpal ray step-cut was synthesised using 2.3 mm compression screws (Medartis AG, Basel, Switzerland). The proximal phalanx was stabilised using two 1 mm Kirschner wires [Figure 6]. Two dorsal veins at the level of the joint were transected before transposition and then anastomosed to the veins of the dorsum of the hand [Figure 7]. An island of skin was left intact on the dorsum of the joint for monitoring. The extensor tendon was repaired using 4-0 non-absorbable mattress sutures. The vascularised joint transfer was allowed to heal for 3 weeks. Then, progressive passive rehabilitation was initiated. After 8 weeks of therapy, the transposed joint showed bone union and a full passive ROM [Figure 6].

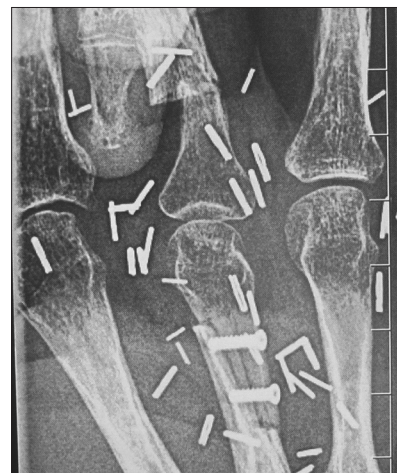Once all the remaining joints were healthy, the fingers had been neurotised and there was stable soft tissue coverage, the patient was scheduled for two-stage reconstruction of the flexor tendons from the second to fourth fingers. All scar tissue was removed through Brunner incisions and 4 mm Swanson–Hunter silicone rod tendon spacers (Wright Medical Technology, Inc., Amstelveen, The Netherlands) were placed finger-to-wrist under A2 and A4 pulley annular tendon-graft reconstructions [Figure 8].<sup>[6]</sup> When the scar was removed, a 1 cm × 1 cm volar defect developed in the index finger, which the latissimus dorsi cuff was rotated to cover. Three months later, after passive mobilisation of all fingers, all joints were fully supple, so the patient was scheduled for the second stage of flexor tendon reconstruction. Tendon grafts of extensor digitorum longus (second to fourth slips) were anchored to the distal phalanges using 4-0 Mitek anchors (DePuy Mitek Inc., Leeds, UK), and pulvertaft 4-0 repairs were performed at the wrist. All grafts were sutured under tension to maintain 80° of MCP, 85° of proximal interphalangeal (PIP) and 15° of distal interphalangeal joint flexion. Passive flexion and



**Figure 4:** (a) Erosion of the metacarpophalangeal joint of the index finger a few weeks after the injury. (b) The joint was removed, and the clinical exploration (c) showed clear degeneration. (d) The full-thickness defect was reconstructed by transferring the fifth metacarpophalangeal joint to the third ray

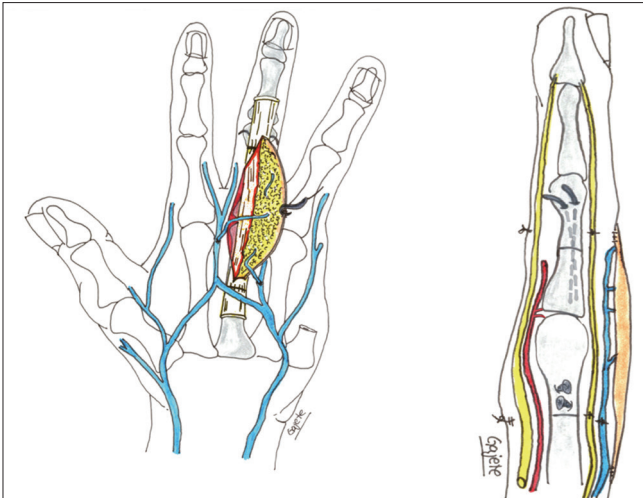


**Figure 5:** The fifth metacarpophalangeal joint was transferred to the third finger based on the ulnar collateral artery under the subcutaneous fat of the palm (volar view). The proximal phalanx was synthesised using Kirschner wires, and the metacarpal bone was fixed with two compression screws



**Figure 6:** Radiological appearance after vascularised joint transfer

protected extension were encouraged at the PIP joint after the first post-operative day.



**Figure 7:** The dorsum of the transferred joint included two veins that were anastomosed to the veins of the dorsum of the hand (dorsal view). The extensor tendon was repaired using non-absorbable mattress sutures

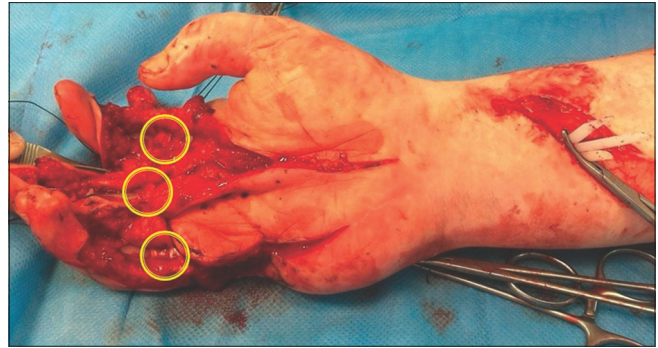
The patient was allowed to stretch the tenorrhaphies progressively only after 3 weeks, followed by assisted active flexion for 9 weeks, after which the patient was allowed to flex against resistance. As a final step, a cosmetic revision was performed 5 months later to remove the redundant muscle island from the thoracodorsal vessels, increase the first web space through skin Z plasties and diminish soft tissue redundancy on the ulnar side of the palm by fat and skin removal.

Sensitivity returned to S3 for the index finger, and S4 for the third and fourth fingers and the thumb, using the measures specified by the Medical Research Council scale. The patient was able to return to work with an almost complete active ROM, for all long fingers [Video 1]. After 2 years, the patient scored 20 in the DASH questionnaire.

## DISCUSSION

Successful replantation or revascularisation of digits usually requires secondary procedures to improve their function.<sup>[4,7-9]</sup> To improve the function of salvaged fingers, our patient required secondary revascularisation, nerve reconstruction, joint reconstruction, two-stage flexor tendon reconstruction and skin revision. This algorithm followed a decision procedure, and our patient showed a notable functional improvement by reducing the DASH score 45 points from his initial score, which is three times the minimum reduction in the score that is required to identify patients whose condition has improved.<sup>[10]</sup>

Wang's decision procedure provides a stepwise approach for the reconstruction of replanted or devascularised



**Figure 8:** Annular pulley reconstructions in all fingers

fingers. For its development, they used as a basis the largest review of replantation cases available. The decision procedure has an anatomical basis in that patients need soft tissue reconstruction first, regardless of what procedures may be needed later. The use of flaps is preferred because only they allow the tendon gliding. Then, nerve reconstruction is needed, not only to enable sensitivity in the finger but also to prevent complications such as silicone rod extrusion that arises as a result of the rehabilitation. Afterwards, the finger must be completely supple, which occurs if the joints are healthy. Only after that can the most frequently needed procedure, which is the reconstruction of tendons, be performed. Fortunately, most patients will not require most of the steps previously mentioned. However, in our case, a decision procedure, aided in designing a surgical plan for the patient. Despite its theoretical appeal, Wang's decision procedure's, clinical effectiveness remains unknown because secondary surgery is not performed very often in such cases.

Finger stiffening is common after Zone II tendon injury and often necessitates secondary reconstruction of joints and tendons.<sup>[11]</sup> The lack of vascular bundles, low sensitivity and need for A2 and A4 pulley reconstructions in the context of two-stage tendon reconstruction, followed by aggressive hand therapy, may pose a risk as silicone implant infection and extrusion, or graft rupture.<sup>[11]</sup> In addition, arthrolysis and tenolysis often require scar removal and carry out a risk of devascularisation of revascularised or replanted digits.<sup>[12]</sup> Thoracodorsal vessel implantation was proposed to treat cold intolerance because it is held to improve the vascularisation of severed digits.<sup>[5]</sup> Grafts from the superficial peroneal nerve were used to restore sensation before silicone rod implantation. The superficial peroneal nerve was harvested easily in the supine position, and the proximal stump remained subfascially deep in the leg, minimising the risk of painful neuroma formation.<sup>[13]</sup> In our case, revascularisation and neurotization allowed safe

scar removal, tenoarthrolysis, silicone rod implantation and tendon grafting in an otherwise barely vascularised finger. Otherwise tendon reconstruction may be unsuitable in poorly vascularised and stiff fingers because tenorrhaphies do not heal or glide smoothly in scarred beds or across stiff joints. In addition, alloplastic tendon spacers may be subject to infection or extrusion when implanted in insensate digits.<sup>[6]</sup>

Although arthrolysis is often required after digit revascularisation or replantation, the need to reconstruct a joint completely is rare.<sup>[14]</sup> Osteochondral grafts and microvascular metatarsophalangeal joint transfers have been used to reconstruct the PIP joint with varying degrees of success, and their use was challenged in a systematic review.<sup>[15]</sup> Osteochondral grafts are better used in acute joint injuries because the ROM they provide is significantly greater than that achieved after their application in chronic injuries.<sup>[16]</sup> We did not consider silicone arthroplasty of the MCP because of the presence of major injury to the flexor and extensor tendons.

The reconstruction of chronic lesions using autologous total MCP replacement remains rare.<sup>[17]</sup> Classically, amputated fingers have served as tissue banks for the reconstruction of other severed fingers in the acute setting.<sup>[8]</sup> In contrast, in our case, the stump of an amputated finger was used as a tissue source for reconstruction in the late post-operative period. A healthy fifth MCP joint was transferred to the third ray followed by venous repairs. We chose to preserve the ulnar collateral artery and only repair the two dorsal veins because there were plenty of recipient veins available in the dorsum. The joint showed complete extension and a full ROM just a few weeks after surgery. Other interventions included two-stage tendon reconstruction and the revision of skin scars, both of which were uneventful.

The replanted thumb required no other revision, except for Z-plasty of the skin in the first web space. The functional status of the patient, indicated by the difference between pre- and post-operative DASH questionnaire scores improved notably. Active ROM was filmed to provide an objective measure of the outcome.

## CONCLUSIONS

The success of replantation should be measured by functional outcome. In this case report, we described the use of a decision-theoretic approach to the secondary

reconstruction of revascularised fingers with a complicated post-operative course that required the use of both established and less frequently used techniques. It proved safe for our patient, who demonstrated an improvement in patient-reported disabilities, gained almost complete restoration of ROM, and was able to return to work. Our experience using this decision procedure in a multistaged case was excellent, but to confirm its efficacy in practice, further evaluation in the clinical setting is required.

## Financial support and sponsorship

Nil.

## Conflicts of interest

There are no conflicts of interest.

## REFERENCES

1. Venkatramani H, Sabapathy SR. Fingertip replantation: Technical considerations and outcome analysis of 24 consecutive fingertip replantations. *Indian J Plast Surg* 2011;44:237-45.
2. Sabapathy SR, Venkatramani H, Bharathi RR, Bhardwaj P. Replantation surgery. *J Hand Surg Am* 2011;36:1104-10.
3. Sabapathy SR, Venkatramani H, Bharathi RR, Sebastin SJ. Distal fingertip replantation without skeletal fixation. *J Reconstr Microsurg* 2005;21:11-3.
4. Wang H, Oswald T, Lineaweaver W. Secondary surgery following replantation. In: Weinzweig N, Weinzweig J, editors. *The Mutilated Hand*. Philadelphia: Elsevier; 2005. p. 247-64.
5. Hussl H, Jungwirth W, Hasenöhr K. Microsurgery for cold intolerance after finger replantation. *Lancet* 1989;2:690.
6. Taras JS, Hankins SM, Mastella DJ. *Staged Flexor Tendon and Pulley Reconstruction*. Philadelphia: Lippincott Williams & Wilkins; 2005.
7. Thomas AG. Unfavorable results in replantation. *Indian J Plast Surg* 2013;46:256-64.
8. Alphonsus CK. Principles in the management of a mangled hand. *Indian J Plast Surg* 2011;44:219-26.
9. Weinzweig N, Sharzer LA, Starker I. Replantation and revascularization at the transmetacarpal level: Long-term functional results. *J Hand Surg Am* 1996;21:877-83.
10. Beaton DE, Katz JN, Fossel AH, Wright JG, Tarasuk V, Bombardier C. Measuring the whole or the parts? Validity, reliability, and responsiveness of the disabilities of the arm, shoulder and hand outcome measure in different regions of the upper extremity. *J Hand Ther* 2001;14:128-46.
11. Hunter JM, Salisbury RE. Flexor-tendon reconstruction in severely damaged hands. A two-stage procedure using a silicone-dacron reinforced gliding prosthesis prior to tendon grafting. *J Bone Joint Surg Am* 1971;53:829-58.
12. Yu JC, Shieh SJ, Lee JW, Hsu HY, Chiu HY. Secondary procedures following digital replantation and revascularisation. *Br J Plast Surg* 2003;56:125-8.
13. Buntic RF, Buncke HJ, Kind GM, Chin BT, Ruebeck D, Buncke GM. The harvest and clinical application of the superficial peroneal sensory nerve for grafting motor and sensory nerve defects. *Plast Reconstr Surg* 2002;109:145-51.
14. Wang H. Secondary surgery after digit replantation: Its incidence and sequence. *Microsurgery* 2002;22:57-61.

15. Squitieri L, Chung KC. A systematic review of outcomes and complications of vascularized toe joint transfer, silicone arthroplasty, and Pyrocarbon arthroplasty for posttraumatic joint reconstruction of the finger. *Plast Reconstr Surg* 2008;121:1697-707.
16. Cavadas PC, Landin L, Thione A. Reconstruction of the condyles of the proximal phalanx with osteochondral grafts from the ulnar base of the little finger metacarpal. *J Hand Surg Am* 2010;35:1275-81.
17. Foucher G, Hoang P, Citron N, Merle M, Dury M. Joint reconstruction following trauma: Comparison of microsurgical transfer and conventional methods: A report of 61 cases. *J Hand Surg Br* 1986;11:388-93.