

Case Report

An unusual foreign body in the infratemporal fossa

Sharad Ramdas

Department of Plastic, Reconstructive and Microsurgery, Pondicherry Institute of Medical Sciences, Puducherry, India

Address for correspondence: Dr. Sharad Ramdas, Department of Plastic, Reconstructive and Microsurgery, Pondicherry Institute of Medical Sciences, Kalapet, Puducherry - 605 014, India. E-mail: sharadramdas2014@gmail.com

ABSTRACT

Infratemporal fossa injuries are uncommon and often go undetected presenting later with complications. We present a case of an infratemporal fossa penetrating injury with a ball point spring following a vehicular accident. Post-traumatic trismus even following supposedly trivial injury in the area should raise suspicion of possible injury in this location.

KEY WORDS

Foreign body; infratemporal fossa; trismus

INTRODUCTION

Recognition of injuries to the infratemporal fossa is of extreme importance in emergency situations as these can lead to life-threatening complications if undetected. We report an unusual cause of infratemporal fossa penetrating injury caused by a spring from a ball point pen which was initially missed and detected by the presence of post-traumatic trismus.

CASE REPORT

A 54-year-old man presented to our emergency room after being involved in a motor vehicle accident in which the van he was travelling in overturned. He was conscious and oriented, and his only complaint was bleeding from the right ear and pain in the area when he tried to open his mouth.

On examination, he was found to have swelling and tenderness in front of the right ear. There was a 1 cm long vertical laceration just medial to the right tragus [Figure 1]. There was no active bleeding. His mouth opening was a full range but accompanied by pain in the right pre-auricular area. His dental occlusion was normal.

The laceration was sutured under local anaesthesia, and a screening X-ray of the skull was ordered. The X-ray showed a spring in the right infratemporal fossa [Figure 2]. This was initially thought to be an artifact but on questioning the patient, he recalled pulling out a ballpoint pen, which had impaled him in his right ear, immediately after the accident. He had been carrying the pen in the right breast pocket of his shirt when the accident occurred.

This is an open access article distributed under the terms of the Creative Commons Attribution-NonCommercial-ShareAlike 3.0 License, which allows others to remix, tweak, and build upon the work non-commercially, as long as the author is credited and the new creations are licensed under the identical terms.

For reprints contact: reprints@medknow.com

How to cite this article: Ramdas S. An unusual foreign body in the infratemporal fossa. Indian J Plast Surg 2016;49:275-8.

Access this article online	
Quick Response Code: 	Website: www.ijps.org
	DOI: 10.4103/0970-0358.191312

A computed tomography (CT) scan was carried out which showed a 3 cm long spring in his right infratemporal fossa [Figure 3].

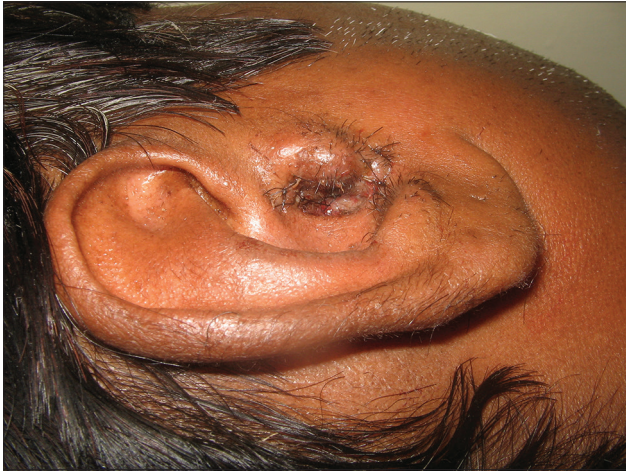

Figure 1: A vertical laceration medial to right tragus

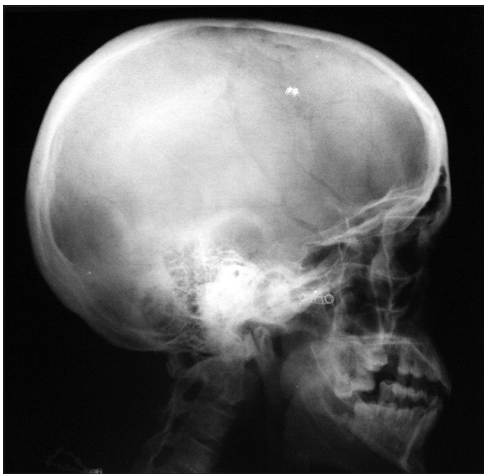

Figure 2: X-ray skull showing spring in the right infra temporal fossa

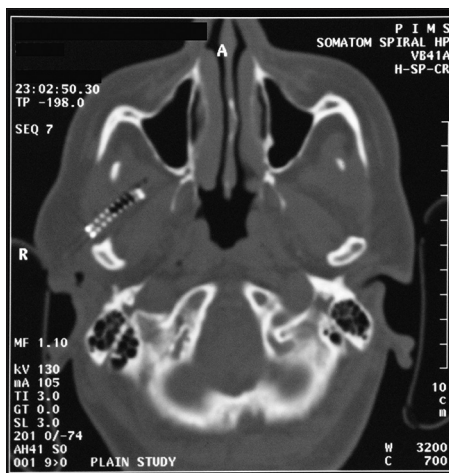


Figure 3: Computed tomography scan showing a 3 cm long spring in right infra temporal fossa

He was taken up for exploration of the wound under general anaesthesia with the plan to approach the infratemporal fossa through the intraoral route, using the assistance of an image intensifier, if required.

The wound was gently probed using a medium artery clamp with a finger in the mouth acting as a guide.

The tract was 8 cm long extending anteromedially into the infratemporal fossa. Multiple fragments of black plastic and a 3 cm long spring were removed, obviating the need for an open procedure. After thoroughly irrigating the wound, it was loosely closed with 5-0 nylon sutures. His post-operative period was uneventful.

DISCUSSION

There have been a number of reports of foreign bodies having been extracted from the infratemporal fossa secondary to external trauma or following complications of oral surgery. A number of these have gone unrecognised at the time of initial injury and have had to be removed later following complications.^[1-6]

A majority of these patients have presented with pain and trismus; however, the diagnosis has been missed in a number of patients, and they have been diagnosed once complications have occurred. In all the reported cases, except for one where the foreign body was vegetative material, the diagnosis was confirmed on a CT scan.^[5]

The infratemporal fossa is a wedge-shaped space between the ramus of the mandible laterally and the wall of the pharynx medially.^[7]

It has a roof, medial, lateral and anterior walls and posteroinferiorly opens into the neck.

The roof is formed by the inferior surfaces of the greater wing of the sphenoid and the temporal bone and is open superiorly to the temporal fossa in its lateral aspect, deep to the zygomatic arch. The lateral wall is formed by the medial surface of the ramus of mandible and it contains the opening to the mandibular canal. A part of the posterior surface of the maxilla forms the anterior wall; the upper part opens as the inferior orbital fissure into the orbit.

There are varied descriptions as to the medial wall. Gray's Anatomy describes the medial boundary as the lateral pterygoid plate, the pharynx and the tensor and levator veli palatini. However, it has also been described in other texts as the sphenoid pterygoid process, lateral portion of the clivus, first cervical vertebra and inferior surface of the petrous portion of the temporal bone.^[8]

A number of neurovascular structures traverse to and from the brain and brain stem through the infratemporal fossa, and it is of great importance to skull base surgeons.

The major contents of the infratemporal fossa include:

- The sphenomandibular ligament
- Medial and lateral pterygoid muscles
- The maxillary artery
- The mandibular nerve, branches of the facial nerve and the glossopharyngeal nerve (IX)
- The pterygoid plexus of veins.

A number of benign or malignant tumours may extend into space either from surrounding areas such as the paranasal sinuses, middle cranial fossa, nasopharynx, parotid gland, external ear canal or occasionally primary tumours may arise from structures within the space. Metastatic lesions in this space are rare.^[9]

Retained foreign material has been reported to be responsible for a number of late complications such as delayed aneurysm,^[10] foreign body granulomas and reactions and migration with erosion of vessel walls.^[11] Other reported late complications include cellulitis, abscess formation and discharging sinus.

The infratemporal fossa lies in a central position between the tissue spaces of the face and the tissue spaces of the neck. Infections involving the infratemporal fossa could potentially spread through the head and neck particularly around the pharynx and compromise the airway, which could be life-threatening. In addition, given the theoretical possibility of migration and erosion into the maxillary artery the early removal of these foreign bodies in this space would be advised.

Traditionally, the major surgical approaches to the infratemporal fossa have been described as anterior (transfacial, transmaxillary, transoral and transpalatal), lateral (transzygomatic and lateral infratemporal) or inferior (transmandibular and transcervical) or a combination of the three. These give a wide surgical exposure but require

Table 1: Approaches used for infra temporal fossa foreign body removal

<i>Foreign body</i>	<i>Surgical approach</i>	<i>Authors</i>
Bullet	Transoral endoscopic	Goswami ^[1] 2013
Glass piece	Intraoral	Hamdoon <i>et al.</i> ^[2] 2012
Tooth	Intraoral	Baig <i>et al.</i> ^[3] 2012
Wooden chip	Pre-auricular	Sajad <i>et al.</i> ^[4] 2011
Vegetable material	Spontaneously extruded	Ziade <i>et al.</i> ^[5] 2009
Hypodermic needle	Transoral endoscopic (computed tomography-guided)	Scott <i>et al.</i> ^[13] 2008
Cottonoid		
Metal object	Endoscopic	Zhang <i>et al.</i> ^[14] 2007
Metal piece	Intraoral	Grant and Rubin ^[6] 2000

considerable tissue dissection and violation of major anatomical structures and may even require osteotomies.^[12]

On reviewing literature, the need for a major surgical procedure to remove a foreign body in the area has not been required, as there has been a need for only limited surgical exposure compared to that required for tumour surgery [Table 1]. With the advent of image-guided endoscopic procedures^[13] the number of open procedures to retrieve foreign bodies in the region is likely to go down.

CONCLUSION

Almost all patients with foreign bodies in the infratemporal fossa, in the literature reviewed, presented with pain and trismus. It would be prudent to say that one should be aware of a possible foreign body if there is post-traumatic trismus even following supposedly trivial injury in the area and rule out the diagnosis only after appropriate radiological studies are carried out.

Financial support and sponsorship

Nil.

Conflicts of interest

There are no conflicts of interest.

REFERENCES

1. Goswami S. A bullet in the maxillary antrum and infratemporal fossa. *Indian J Dent Res* 2013;24:149.
2. Hamdoon Z, Jerjes W, Al-Delayme RM, Upile T, Hopper C. Glass displaced into the infratemporal region from submandibular injury: A case report. *Hard Tissue* 2012;10:6.
3. Baig MH, Punjabi SK, Khan M. Displacement of maxillary third molar in the infratemporal fossa. *Pak Oral Dent J* 2012;32:39-41.
4. Sajad M, Kirmani MA, Patigaroo AR. Neglected foreign body infratemporal fossa, a typical presentation: A case report. *Indian J Otolaryngol Head Neck Surg* 2011;63 Suppl 1:96-8.

5. Ziade M, Mallek A, Delaval C, Goudot P, Yachouh J. Vegetable foreign body of the infratemporal fossa: A case report. *Rev Stomatol Chir Maxillofac* 2009;110:236-8.
6. Grant CA, Rubin PA. An infratemporal fossa foreign body presents as an infraorbital mass. *Arch Ophthalmol* 2000;118:993-5.
7. Strandring S. Infratemporal and pterygopalatine fossae and temporomandibular joint. In: Strandring S, editor. *Gray's Anatomy: The Anatomical Basis of Clinical Practice*. 14th ed. London: Churchill Livingstone Elsevier; 2011. p. 527.
8. Arya S, Rane P, D'Cruz A. Infratemporal fossa, masticator space and parapharyngeal space: Can the radiologist and surgeon speak the same language? *Int J Otorhinolaryngol Clin* 2012;4:125-35.
9. Tiwari R, Quak J, Egeler S, Smeele L, Waal IV, Valk PV, *et al*. Tumors of the infratemporal fossa. *Skull Base Surg* 2000;10:1-9.
10. Chedid MK, Vender JR, Harrison SJ, McDonnell DE. Delayed appearance of a traumatic intracranial aneurysm. Case report and review of the literature. *J Neurosurg* 2001;94:637-41.
11. Lahiri S, Ghosh S, Sengupta G, Bakshi U. An unusual presentation of foreign body in the common carotid artery. *Indian J Surg* 2011;73:460-2.
12. Isolan GR, Rowe R, Al-Mefty O. Microanatomy and surgical approaches to the infratemporal fossa: An anaglyphic three-dimensional stereoscopic printing study. *Skull Base* 2007;17:285-302.
13. Scott AR, Dodson TB, Platt MP, Metson RB. S123 – New approaches to infratemporal fossa foreign body removal. *Otolaryngol Head Neck Surg* 2008;139:118.
14. Zhang SY, Yang C, Zheng JW, Wang Y, Fan XD, Yun B, *et al*. Endoscopic removal of a metallic foreign body from the infratemporal fossa. *Asian J Oral Maxillofac Surg* 2007;19:215-7.