

Original Article

Subcutaneous pedicle propeller flap: An old technique revisited and modified!

Durga Karki, Nikhil Mehta, Ravi Prakash Narayan

Department of Burns, Plastic and Maxillofacial Surgery, VMMC and Safdarjung Hospital, New Delhi, India

Address for correspondence: Dr. Nikhil Mehta, Department of Burns, Plastic and Maxillofacial Surgery, VMMC and Safdarjung Hospital, New Delhi, India. E-mail: dr.nikhilmehta84@gmail.com

ABSTRACT

Background: Post-burn axillary and elbow scar contracture is a challenging problem to the reconstructive surgeon owing to the wide range of abduction and extension that should be achieved, respectively, while treating either of the joint. The aim of this paper is to highlight the use of subcutaneous pedicle propeller flap for the management of post-burn axillary and elbow contractures. **Methodology:** This is a prospective case study of axillary and elbow contractures managed at a tertiary care hospital using propeller flap based on subcutaneous pedicle from 2009 to 2014. Surgical treatment comprised of subcutaneous-based pedicle propeller flap from the normal tissue within the contracture based on central axis pedicle. The flap was rotated axially to break the contracture. The technique further encompassed a modification, a Zig-Zag incision of the flap, which was seen to prevent hypertrophy along the incision line. There was a mean period of 12 months of follow-up. **Results:** Thirty-eight patients consisting of 22 males and 16 females were included in this study among which 23 patients had Type II axillary contractures and 15 had moderate flexion contractures at elbow joint. The post-operative abduction achieved at shoulder joint had a mean of 168° whereas extension achieved at elbow had a mean of 175°. The functional and aesthetic results were satisfactory. **Conclusion:** The choice of surgical procedure for reconstruction of post-burn upper extremity contractures should be made according to the pattern of scar contracture and the state of surrounding skin. The choice of subcutaneous pedicle propeller flap should be emphasised because of the superior functional results of flap as well as ease to learn it. Moreover, the modification of propeller flap described achieves better results in terms of scar healing. There is an inter-positioning of healthy skin in between the graft, so it prevents scar band formation all around the flap.

KEY WORDS

Axillary contracture; elbow contracture; subcutaneous pedicle propeller flap

Access this article online	
Quick Response Code: 	Website: www.ijps.org
	DOI: 10.4103/0970-0358.191306

This is an open access article distributed under the terms of the Creative Commons Attribution-NonCommercial-ShareAlike 3.0 License, which allows others to remix, tweak, and build upon the work non-commercially, as long as the author is credited and the new creations are licensed under the identical terms.

For reprints contact: reprints@medknow.com

How to cite this article: Karki D, Mehta N, Narayan RP. Subcutaneous pedicle propeller flap: An old technique revisited and modified!. Indian J Plast Surg 2016;49:220-4.

INTRODUCTION

Post-burn contractures of elbow or axilla lead to severe functional disability and are aesthetically disfiguring. Flaps or grafts are needed to cover the wound as well as to correct contracture. Despite various surgical techniques available, these pose a challenge for reconstruction due to the complexity of replacing 'like with like' tissues at minimum donor site 'cost' and with maximal efficacy and accuracy. This urged us to explore the option of using propeller flaps based on healthy skin left in the centre of the recipient site.

As the understanding of the cutaneous vasculature has improved, propeller flaps are now considered reliable reconstructive method, based on its vascular pedicle.

The concept of propeller flap was first introduced by Hyakusoku *et al.* in 1991.^[1] Propeller flap is elevated as an island flap with a pedicle at the centre allowing its rotation at 90°. It resembles a propeller of a ship and rotates on its central axis to cover the defect.^[1] The donor site is either primarily covered or skin grafted. Since their introduction in 1991, a great variety of propeller flaps have been described; according to their shape and their potential for coverage. These flaps have progressively been refined and modified, based on their vascularity and space design. The scope of modifying propeller flaps according to the need, led various surgeons to classify them in their own interpretations. To bring about a unanimous nomenclature, the flaps are classified according to the Tokyo consensus classification [Table 1].^[2]

Aims and objectives

To study the utility of subcutaneous pedicle propeller flaps in the reconstruction of post-burn axillary and elbow contractures.

METHODOLOGY

This is a clinical study of axillary and elbow contractures managed at a tertiary care hospital using propeller flap based on subcutaneous pedicle from the year 2009 to 2014.

Twenty-three patients of axillary contractures and 15 of elbow contracture were included in the study. Those with Type II axillary contracture [Table 2] or moderate contracture at elbow joint [Table 3] and with a part of healthy skin left at the centre of cubital fossa or axilla were included in the study. Patients of all age groups and both sexes were included.

Operative technique

Planning in reverse was utilised to design a diamond shaped flap over the flexion contracture according to the size of the defect, that would be created following the release of contracture and the normal skin available at the centre of contracture. No Doppler study was done pre-operatively to identify the perforators as it was based on the central subcutaneous pedicle. The modification we used was, to give a Zig-Zag incision line over the flap. Release of flexion/adduction contractures with subsequent cover of the raw areas, thus created, was done with propeller flap. Flap was islanded while maintaining its vascularity from the subcutaneous pedicle in the central portion so categorised as 'central axis flap method'. Dissection was done gradually by teasing the subcutaneous tissue, taking care not to damage the underlying perforators, up to a level where the flap is comfortably rotated into the defect. The flap thus raised was rotated by 90° so that the longitudinal axis was now in the transverse axis and vice versa. This rotation took place only at the peripheries of the flap. The hair-bearing portion of normal skin in centre of axillary contracture was preserved while rotating the flap in position so as to provide functional as well as aesthetic result. The primary aim was achieving full range of movement in the affected joint and in none of the cases, this aim was compromised.

Table 1: Tokyo Consensus classification

Type of Nourishing Pedicle	Definition:
Subcutaneous Pedicled Propeller Flap	The flap is based on a random subcutaneous pedicle. The perforators included in the pedicle are not visualized or isolated.
Perforator Pedicled Propeller flap	This vessel dictates the position of the skin island that is centered over it. The perforating vessel is then skeletonized and freed from the fascial adhesions. This refinement makes a rotation of up to 180 degrees safe. This is the type of propeller flap that allows the greatest degree of rotation, and it is the most commonly used.
Supercharged Propeller Flap	The supercharged propeller flap is a modification of the perforator pedicled propeller flap. If a long propeller flap is needed, and the isolated perforator vessel is not providing a sufficient arterial inflow or a sufficient venous outflow, an extra pedicle can be added

In majority of cases, the flap once rotated was able to cover the defect. However, in cases where flap was not able to cover the raw area completely, skin grafting was added. Patient details are mentioned in Table 4.

Post-operative care

Splinting was done post-operatively for 7 days. Broad-spectrum antibiotic coverage and regular dressings were done for all the patients. Patients were allowed to carry out passive and active exercises through full range of motion, once splintage was removed. In cases where skin grafts were applied along with propeller flap, the splintage was kept for 3 weeks continuously, followed by night splintage for 6 months. Patients were advised to keep the grafted areas well lubricated. To reduce scar hypertrophy, patients were advised to use pressure garments for 8–12 months. Follow-up visits were done after 3 days, 1 week, 3 weeks, 1 month, 3 months, 6 months and 1 year to monitor the progress. The photographic assessment was done at various stages of healing post-operatively.

RESULTS

Thirty-eight patients consisting of 22 males and 16 females presented with axillary or elbow contractures from 2009 to 2014. The mean age, the type contracture are detailed in Table 4. Follow-up ranged from 12 to 32 months. The mean pre-operative abduction in patients of axillary contracture was 40.61° while the mean pre-operative extension at elbow joint was 71.4°. The mean post-operative abduction at axilla was 168.39° whereas mean post-operative extension at the elbow was 175.47°. The functional and aesthetic results were satisfactory [Table 5] [Figures 1-6]. It was also noted that scar hypertrophy along the line of inseting of flap was absent/minimal when the modification proposed for incision line was used. There is an inter-positioning of healthy skin in between the graft, so it prevents scar band formation all around the flap and also minimised the recurrence of contracture.

Minor complications like necrosis of flap at edges or partial graft loss were noted in five patients, which healed without significant sequelae.

DISCUSSION

Contractures in axilla are difficult to manage because of joint stiffness, difficulty in splinting and the high recurrence rate with inadequate care. Treating axillary

contractures should replace these gliding possibilities. To reconstruct a burn elbow contracture, flaps are preferred over skin grafting as the latter have tendency to contract and may not take up completely. Numerous local and distant flaps have been employed, such as V–Y and Z-plasty techniques for linear band contractures,

Table 2: Kurtzmann Classification of axillary contractures

Classification	
Type 1A	Injuries involving anterior axillary fold
Type 1B	Injuries involving posterior axillary fold
Type 2	Injuries involving both anterior & posterior axillary folds (sparing axillary dome)
Type 3	Injuries Type 2 plus axillary dome

Table 3: Grading of Severity of Elbow Contracture (used in our study)

Joint	Muscle Action	Contracture Severity (in degree)		
		Mild	Moderate	Severe
Elbow	Extension	100-140	45-100	<45

Table 4: Demographic details of patients

	Axillary Contracture	Elbow Contracture
No. of patients	23	15
Male: Female	1.88:1	0.86:1
Mean age	23.7 years (15-33)	17.7 years (4-30)
Cause of Burn	Thermal >> Scald > Electric flash	Thermal >> Scald
Mean Pre-operative degree	40.60	71.40
Severity Grading included	Type II	Moderate
Mean Post-operative abduction/extension achieved	168.390	175.470
Major complications	Nil	Nil
Minor complications	Tip necrosis at edges of flap in 1 patient Partial graft loss seen in 1 patient	Flap necrosis at edges in 2 patients Partial graft loss seen in 3 patients

Table 5: Aesthetic outcome as assessed by patients (according to Global aesthetic improvement score)

Improvement score	Description	Number of patients
Very much improved	Optimal cosmetic result	20
Much improved	Marked improvement in appearance from the initial condition, but not completely optimal for this patient. A touch-up will slightly improve the result	12
Improved	Obvious improvement in appearance from the initial condition, but a touch up or re-treatment is indicated	6
No change	The appearance is essentially the same as the original condition	0
Worse	The appearance is worse than the original condition	0

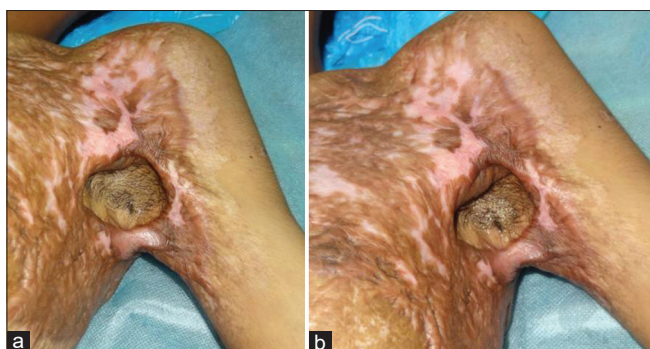

Figure 1: Pre-operative photograph of Type II axillary contracture (45° abduction) showing involvement of anterior and posterior axillary fold with sparing of hair bearing site. (a) Distant view. (b) Close-up focusing on hair bearing site

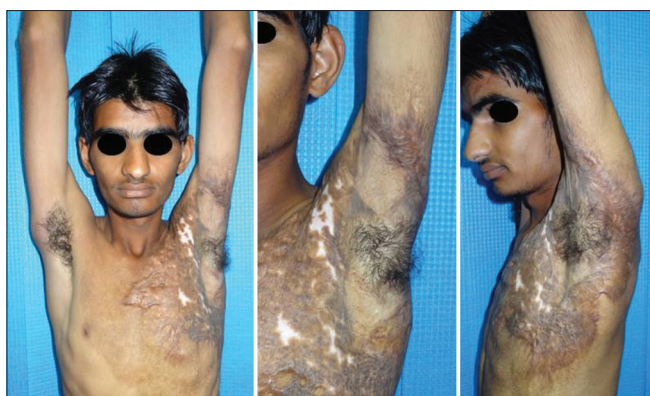

Figure 3: Post-operative photograph showing 180° abduction at shoulder joint which was maintained at 1 year with preservation of the hair bearing area

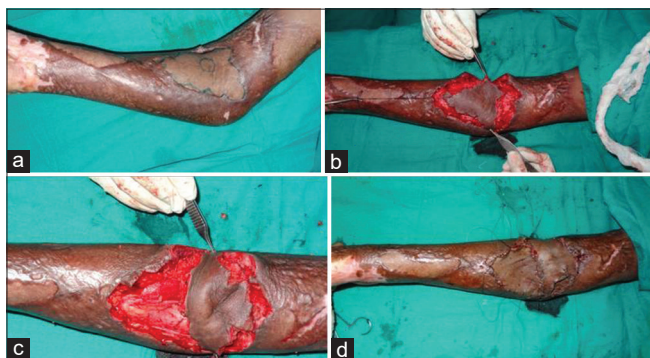

Figure 5: Intraoperative photograph of elbow contracture being released through subcutaneous propeller flap. (a) Intraoperative markings. (b) Raising the subcutaneous propeller flap. (c) Rotation of flap at 90°. (d) Surrounding skin covered with split thickness graft and the graft fixed in place

local fasciocutaneous flaps that may or may not include previously burned skin territories, radial, ulnar and posterior interosseous fasciocutaneous proximally-based flaps and reversed flow flaps such as the lateral arm and the ulnar recurrent upper-arm flap.^[3,4] In addition, distant pedicle and microvascular transfer flaps are also being used. In all these flaps, the functional losses, cosmetic results and compromise of future reconstructive options

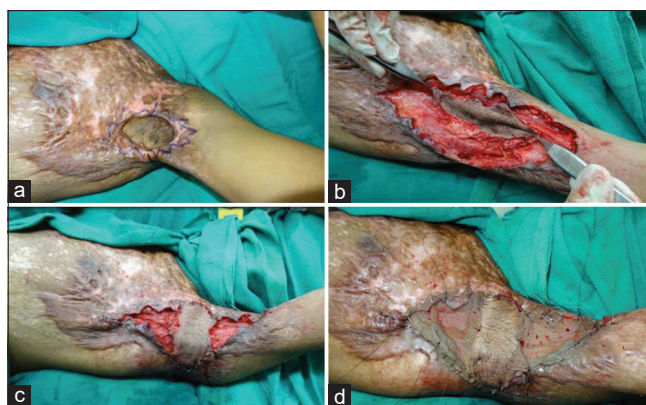


Figure 2: Intraoperative photographs of axillary contracture being released through subcutaneous propeller flap. (a) Intraoperative flap markings. (b) Raising the subcutaneous propeller flap. (c) Propeller flap rotated at 90° for final placement. (d) Surrounding skin covered with split thickness graft and the graft fixed in place

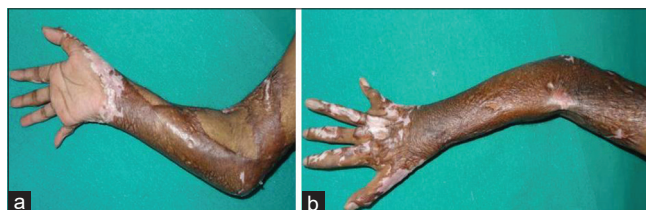

Figure 4: Pre-operative photograph of moderate degree (95°) of elbow contracture. (a) Ventral view. (b) Dorsal view

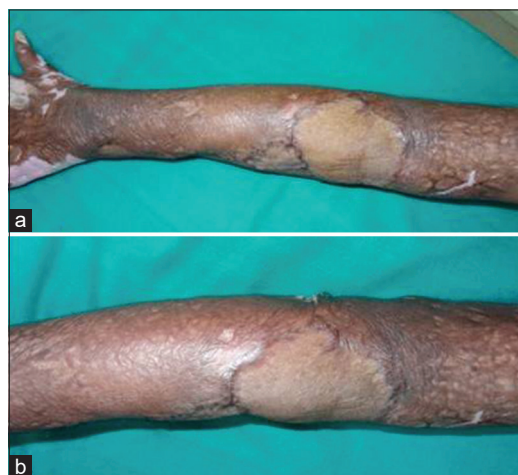

Figure 6: Post-operative photograph of elbow contracture showing 180° extension at the joint. (a) Distant view. (b) Close up view

should be taken into consideration while planning these surgeries.

Propeller flap surgery should follow certain principles. Flaps should be based on perforators as close to the midline or to a fixed point (shoulder, elbow and wrist in upper extremity) as possible and be marked along the axis of the main source vessel. The safest orientation of

the main axis of the flaps is transverse (perpendicular to midline) for the trunk and longitudinal for the upper extremity. This allows for the vascular axis of flow between the perforator vascular territories to follow the direction of linking vessels.^[5,6]

In 1991, Hyakusoku *et al.* introduced the concept of propeller flap consisting of two lobes.^[1] Later, it was followed by some modifications to include more limbs, for example, the multilobed propeller flap and pin-wheel flap.^[7,8]

Since the introduction of propeller flaps in 1991, these have been used in various indications like the reconstruction of tissue defects in traumatic and oncological background. The use of these flaps for post-burn contracture release is not very frequent. Aslan *et al.* performed propeller flaps in seven patients for post-burn elbow contractures with good outcome.^[9] Hyakusoku *et al.* in 2006, performed scar band rotation flap method for scar contractures in finger joints and interdigital spaces.^[10] They concluded that their method efficiently uses surviving normal skin over time. Mohan and Nagarjuna recently used propeller flaps in twenty patients of post-burn axillary contractures.^[11] They concluded that the adequacy of release was superior when compared to Z-plasty, comparable to V-Y and X-plasty and inferior to split skin graft (SSG). Coverage of vital areas was superior to all other techniques, and aesthetic outcome was superior to SSG. Panse *et al.* in 2012, used 16 perforator propeller flaps for post-burn reconstruction for various areas of the body.^[12] Out of these 16 patients, two patients of post-burn contracture elbow were treated by subcutaneous pedicle propeller flap. They too reached to the conclusion that propeller flaps are simple, safe and versatile and must be considered as the primary option for treatment of burn wounds and sequel wherever possible.

The results of this study certainly prove that the use of propeller flap is a good alternative for post-burns contracture release and reconstruction. Further, the use of this technique for elbow, axillary contractures with good results demonstrates the versatility of the technique.

CONCLUSION

Subcutaneous propeller flaps are an important addition to the armamentarium of the plastic surgeon for the management of burn wound sequelae. The design of flap is simple, and the operation is easy and short. It is a one-stage procedure with minimal if any, added donor site morbidity and the colour and texture matches are excellent. The modification that has been proposed as a Zig-Zag incision for raising the flap leads to minimal scar hypertrophy and should be incorporated for better aesthetic results.

Financial support and sponsorship

Nil.

Conflicts of interest

There are no conflicts of interest.

REFERENCES

1. Hyakusoku H, Yamamoto T, Fumiiri M. The propeller flap method. *Br J Plast Surg* 1991;44:53-4.
2. Pignatti M, Ogawa R, Hallock GG, Mateev M, Georgescu AV, Balakrishnan G, *et al.* The "Tokyo" consensus on propeller flaps. *Plast Reconstr Surg* 2011;127:716-22.
3. Karki D, Mehta N, Narayan RP. Post-burn axillary contracture: A therapeutic challenge! *Indian J Plast Surg* 2014;47:375-80.
4. Schwarz RJ. Management of postburn contractures of the upper extremity. *J Burn Care Res* 2007;28:212-9.
5. Lecours C, Saint-Cyr M, Wong C, Bernier C, Mailhot E, Tardif M, *et al.* Freestyle pedicle perforator flaps: Clinical results and vascular anatomy. *Plast Reconstr Surg* 2010;126:1589-603.
6. D'Arpa S, Cordova A, Pignatti M, Moschella F. Freestyle pedicled perforator flaps: Safety, prevention of complications, and management based on 85 consecutive cases. *Plast Reconstr Surg* 2011;128:892-906.
7. Murakami M, Hyakusoku H, Ogawa R. The multilobed propeller flap method. *Plast Reconstr Surg* 2005;116:599-604.
8. Murakami M, Hyakusoku H, Ogawa R. The scar band rotation flap. *Burns* 2005;31:220-2.
9. Aslan G, Tuncali D, Cigsar B, Barutcu AY, Terzioglu A. The propeller flap for postburn elbow contractures. *Burns* 2006;32:112-5.
10. Hyakusoku H, Iwakiri I, Murakami M, Ogawa R. Central axis flap methods. *Burns* 2006;32:891-6.
11. Mohan, Nagarjuna TR. Our experience with propeller flap. *J Evid Based Med Health Care* 2014;1:539-46.
12. Panse N, Sahasrabudhe P, Bhatt Y. Use of local perforator flaps for post burn reconstruction. *World J Plast Surg* 2012;1:22-9.