

Letters to Editor

Hatchet flap and rotation flap for distal dorsal finger defect reconstruction

Sir,

The fingers are considered to be very intricate creation by God with its osseous, tendinous, ligamentous and neurovascular architecture. The skin of the finger dorsum is very thin making the extensor tendon and the joints vulnerable to get injured and exposed.

Our patient is a 26-year-old man presented with deep abrasion over the palm in thenar eminence and the dorsum of index, middle, ring and little fingers over the distal and proximal phalanges. The injury over the ring, little and middle fingers had exposed distal inter-phalangeal joint [Figure 1a]. The injury over the index finger was not exposing the joint, and that was closed primarily. The distal inter-phalangeal joints of middle and ring fingers were destroyed with partial loss of head of the middle phalanges [Figure 1b] and these joints were arthrodesed and stabilised with 0.8 mm K-wires. The defect over the middle finger was closed with hatchet flap and the defects over the little and ring fingers were managed with rotation flap raised from the dorsum, based

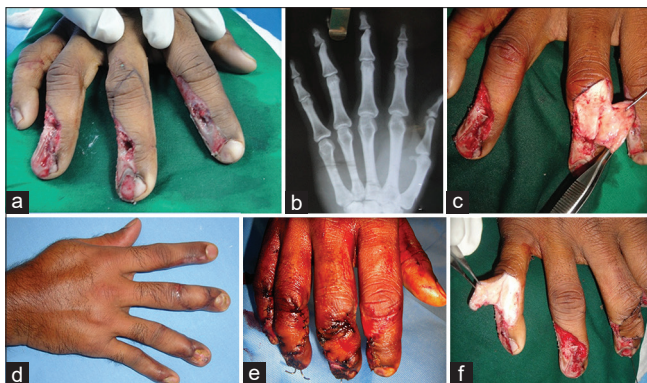

Figure 1: (a) Deep abrasion injury over the dorsum of index, middle, ring and little fingers with exposed distal inter-phalangeal joint of the middle, ring and little fingers with marking for the hatchet flap. (b) X-ray hand showing involvement of the distal inter-phalangeal joint more in ring and middle fingers. (c) The elevated hatchet flap over the middle finger. (d) Rotation flap elevated over the little finger and the closure of the hatchet flap over the middle finger. (e) Flap inset immediate post-operative. (f) 2 months post-operative result showing the well-settled hatchet and rotation flaps

medially [Figure 1c-e]. The flaps survived completely giving good result. The aesthesis was acceptable after 2 months of the procedure [Figure 1f]. Active and/or passive range of movements of all the digits' joints after 3½ years is seen in Video 1. The dorsal scars also were well-settled over a period of 3½ years of post-surgery [Figure 2].

The turnover reversed cross finger flap is commonly used technique for the reconstruction of the dorsum.^[1] The disadvantage of this procedure is immobilisation and sacrificing the adjacent finger dorsum. The homodigital adipofascial turnover flap is another described method for the dorsal defects. Braga-Silva^[2] in his study analysed the anatomy of the flap in cadavers and applied its use clinically. He could identify the dorsal arterial branches from the proper digital vessel in the proximal and distal phalanges, and he used them clinically well. Kawakatsu and Ishikawa^[3] in their clinical study have used dorsal digital perforator flap for the dorsal defect reconstruction. They identified the dorsal digital perforator near the defects and elevated perforator flap in the form of rotation flap or VY advancement flap. In case of small defects, the use of reverse dorsal metacarpal artery (RDMA) flaps looks little overdoing due to the extensive dissection required for both elevation and inset. The RDMA flap is elevated from the dorsum of hand giving another aesthetically displeasing scar. The hatchet flap has been used for the reconstruction of the volar fingertip by Tuncali *et al.*^[4] The outcome of the flap was satisfactory with good functional recovery. The use of the hatchet

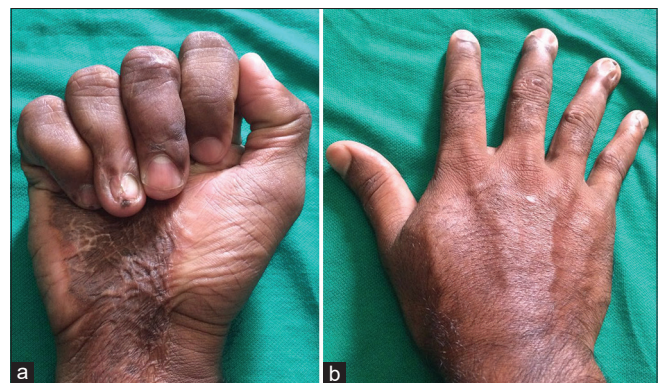


Figure 2: (a and b) Well-settled scar over the finger dorsum after a period of 3½ years post-surgery

flap is not used for the finger dorsum according to the author's best knowledge.

Financial support and sponsorship

Nil.

Conflicts of interest

The authors do not have any conflict of interest.

Jyoshid R. Balan

Department of Plastic Surgery, Sushrutha Institute of Plastic, Reconstructive and Aesthetic Surgery, Elite Mission Hospital, Thrissur, Kerala, India

Address for correspondence:

Dr. Jyoshid R. Balan, Sushrutha Institute of Plastic, Reconstructive and Aesthetic Surgery, Elite Mission Hospital, Thrissur - 680 007, Kerala, India.
E-mail: drjosh4u@gmail.com

REFERENCES

1. Fejjal N, Belmir R, El Mazouz S, Gharib N, Abbassi A, Belmahi A. Reversed cross finger subcutaneous flap: A rapid way to cover finger defects. *Indian J Plast Surg* 2008;41:55-7.
2. Braga-Silva J. Anatomic basis of dorsal finger skin cover. *Tech Hand Up Extrem Surg* 2005;9:134-41.
3. Kawakatsu M, Ishikawa K. Dorsal digital perforator flap for reconstruction of distal dorsal finger defects. *J Plast Reconstr Aesthet Surg* 2010;63:e46-50.
4. Tuncali D, Barutcu AY, Gokrem S, Terzioglu A, Aslan G. The hatchet flap for reconstruction of fingertip amputations. *Plast Reconstr Surg* 2006;117:1933-9.

This is an open access article distributed under the terms of the Creative Commons Attribution-NonCommercial-ShareAlike 3.0 License, which allows others to remix, tweak, and build upon the work non-commercially, as long as the author is credited and the new creations are licensed under the identical terms.

Video Available on: www.ijps.org

Access this article online

Quick Response Code:



Website:

www.ijps.org

DOI:

10.4103/0970-0358.191305

How to cite this article: Balan JR. Hatchet flap and rotation flap for distal dorsal finger defect reconstruction. *Indian J Plast Surg* 2016;49:283-4.