

Original Article

Tuberous breast deformity: A modified technique for single-stage correction

Shweta Aggarwal, Niri S. Niranjan

St. Andrew's Centre for Burns and Plastic Surgery, Broomfield Hospital, Chelmsford, Essex CM1 7ET, UK

Address for correspondence: Dr. Shweta Aggarwal, St. Andrew's Centre for Burns and Plastic Surgery, Broomfield Hospital, Chelmsford, Essex CM1 7ET, UK. E-mail: drshweta@gmail.com

ABSTRACT

Introduction: Tuberous breast deformity is one of the most challenging congenital breast anomalies. Severe forms present as hypoplasia of lower medial and lateral quadrants and breast base constriction. We present a modified technique based on redistribution of breast tissue for single-stage aesthetic correction of this deformity. **Material, Methods and Surgical Technique:** The technique is based on Lejour's method of single vertical scar breast reduction. The breast tissue is divided into three superiorly based pedicles. However, instead of joining the three pedicles, they are spread to redistribute tissue to quadrants which are deficient. This technique is combined with implant insertion if the breast volume is deficient or mastopexy if there is significant ptosis. The level of nipples is matched to achieve symmetry and areolar reduction done where indicated. We have used this for six patients with Type I/II/III (von Heimburg, 2000) tuberous breast deformity. **Results and Discussion:** The aesthetic results have been very good in terms of shape, volume, symmetry and patient satisfaction. A historical summary of the development of techniques for correction of tuberous breast is presented along with description of our method and its results.

KEY WORDS

Lejour; single-stage correction; tuberous breast

INTRODUCTION

Tuberous breast deformity is one of the most challenging congenital breast anomalies. It was first described by Rees and Aston in 1976.^[1] Since then, the same deformity has been described by various other names such as tubular breast,^[2] snoopy breast,^[3] herniated areolar complex,^[4] domed nipple and^[5] narrow base breast,^[6] which are all based on the morphological appearance of the tuberous breast. The deformity is

characterised by a constricted breast base and deficient horizontal and/or vertical development of the breast with or without herniation of the breast parenchyma towards the nipple-areola complex (NAC) and areolar enlargement. Although the definitive aetiology of tuberous breast deformity is unknown, several theories have been proposed. Grolleau *et al.* suggest that the superficial fascia enveloping the breast is abnormally adherent to the dermis and the muscular plane, and by restricting

Access this article online	
Quick Response Code: 	Website: www.ijps.org
	DOI: 10.4103/0970-0358.191293

This is an open access article distributed under the terms of the Creative Commons Attribution-NonCommercial-ShareAlike 3.0 License, which allows others to remix, tweak, and build upon the work non-commercially, as long as the author is credited and the new creations are licensed under the identical terms.

For reprints contact: reprints@medknow.com

How to cite this article: Aggarwal S, Niranjan NS. Tuberous breast deformity: A modified technique for single-stage correction. *Indian J Plast Surg* 2016;49:166-71.

the breast expansion, forces the breast to preferentially expand forward, enlarging the areola.^[7] Alternatively, Mandrekas *et al.* proposed that the deformity is a result of a constricting ring at the base of the breast causing the vertical and horizontal deficiencies. Breast growth leads to eventual herniation into the areola.^[8] Tuberous breast deformity presents itself in varying degrees of severity and classification is important to plan and compare treatment options. von Heimburg classification was first published in 1996 and further refined in 2000^[9,10] [Table 1]. We describe a single-stage modified technique for correction of tuberous breast deformity which is based on Lejour's method of breast reduction applied in a reverse manner. We applied this technique to 6 patients with 9 tuberous breast deformities. The method is based on redistribution of breast parenchyma to deficient quadrants. It is combined with implant insertion if the breast volume is deficient. The level of nipples is matched to achieve symmetry and areolar reduction done where indicated. This technique is effective for correction of Type I, Type II and Type III deformities. The technique is simple, easy to learn as most surgeons are already aware of the Lejour's technique and achieves correction in a single surgery.

MATERIALS AND METHODS

The records of six patients with nine tuberous breasts operated at St. Andrew's Centre by a single surgeon (senior author, NSN) were reviewed [Table 2]. The mean age of patients was 23 years (range, 16–40 years). Three patients had bilateral deformities and three unilateral. Of the nine breasts treated, there were two of Type I, five of Type II and two of Type III deformities. Areolar prolapse was present in five breasts. Augmentation with a breast implant was required in all patients except one patient with a Type II unilateral deformity. The mean follow-up was 22 months with the longest being 6 years.

Surgical technique

The technique is based on Lejour's method of breast reduction applied in a reverse manner. Therefore, just like in Lejour's technique, the breast parenchyma is divided into three superiorly based pedicles. However, instead of bringing these together as in Lejour's, these pedicles are spread out (over an implant if required) to redistribute breast parenchymal tissue to deficient quadrants. In Lejour's method, a large flat breast is converted to a conical breast with good projection, whereas in our technique, a conical tuberous breast is given a flatter profile.

Table 1: von Heimburg classification

Type	Description
Type I	Hypoplasia of the lower medial quadrant
Type II	Hypoplasia of the lower medial and lateral quadrants, sufficient skin in the subareolar region
Type III	Hypoplasia of the lower medial and lateral quadrants, deficiency of skin in the subareolar region
Type IV	Severe breast constriction, minimal breast base

Table 2: Patient demographics and breast pathology

Case	Age (years)	Type (L)	Type (R)	Areolar prolapse (L)	Areolar prolapse (R)	Implant (L, ml)	Implant (R, ml)
1	16		II		+		Nil
2	17	II	I	-	-	215	215
3	25	I	III	+	+	100	200
4	18		II	+		115	
5	40	II	III	+	+	152	220
6	22	II		-		180	

The incision used is periareolar with or without a vertical component. The vertical component can be omitted if the areola is very large and provides adequate access for glanuloplasty. In the presence of areolar prolapse and large areola, an areolar reduction is done first. Skin flaps are then lifted off the breast parenchyma by sharp dissection. The NAC is raised on a central superior pedicle. The remaining parenchyma is dissected off the chest wall and divided into two superiorly based lateral pedicles. The pre-pectoral fascia is carefully preserved during all dissection and meticulous haemostasis ensured. The breast implant (if required) is placed beneath the parenchyma. The pedicles are spread over the implant in a way such that the parenchyma is redistributed in a uniform manner to the deficient lower quadrants. The incision is closed with 3–0 poliglecaprone 25 (Monocryl) subcutaneous and subcuticular sutures and dressed with Steri-Strips. At the end, a plaster corset is placed and kept on for 1 week after which patients are advised to use breast support for a further 3 months [Figures 1 and 2a, b].

RESULTS

All patients were assessed at 3 weeks after discharge from the hospital and then at 3 months, 6 months and 1 year and at each successive year thereafter. The maximum follow-up was 6 years. The results were evaluated in terms of breast volume, shape, symmetry and overall appearance by the surgical team. All parameters were graded as poor (0), fair (1), good (2) and very good (3). There were no operative complications. All results were graded as good or very good [Table 3, Figures 3 and 4].

DISCUSSION

Tuberous breast deformity was first described by Rees and Aston in 1976.^[1] They described it as being characterised by ‘small truncated glands with apparently normal function’. They also distinguished between two types of tuberous breast: The ‘tuberous breast’ and the ‘tubular breast’. For the tuberous breast, Rees and Aston performed an operation through a periareolar incision by first removing a doughnut-shaped segment of the areola. They then

widely undermined the skin, selectively lowered the inframammary fold and introduced an implant into the submammary plane. The operation was completed by advancing the undermined skin over the dermis of the areola thus correcting the ‘herniation’ by telescoping this portion of the areola into the breast. Rees and Aston used a different approach for the tubular breast. Through an inframammary incision, the breast was dissected from the pectoral fascia. Radial incisions were made on the pectoral surface of the breast in order that the parenchyma could unfold like a star fish. An implant was then placed in the pocket, and the expanded breast tissue draped over it.

Since then, literature has been replete with various techniques for the correction of tuberous breast deformity. Toronto (1981) described a two-stage correction and differentiated tuberous breast from tubular breast. The two-stage approach involved, first ‘converting a tuberous breast into tubular breast’ by augmentation mammoplasty, and at a second stage, correction of nipple–areola projection and ptosis by means of a modified Arie-Pitanguy pattern with telescoping of protuberant breast under local anaesthesia.^[11]

Teimourian and Adham described a single-stage technique involving subpectoral augmentation followed

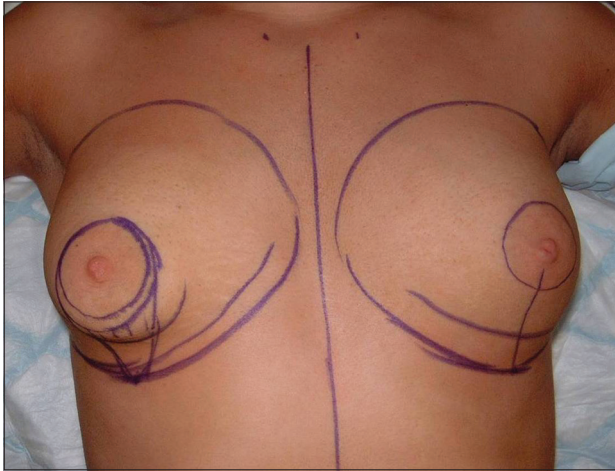


Figure 1: Pre-operative drawing

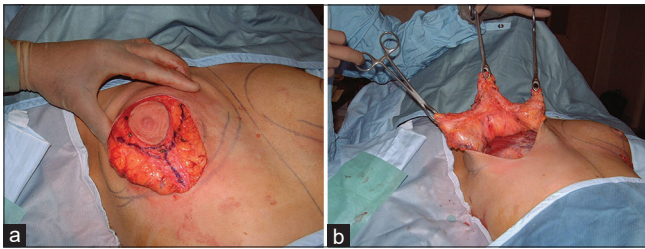


Figure 2: (a) Breast parenchyma divided into three pedicles. (b) Breast parenchyma dissected off the chest wall as three superiorly based pedicles

Table 3: Outcome^a

Case	Volume	Shape	Symmetry
1	3	3	3
2	3	3	3
3	3	3	2
4	3	3	3
5	3	2	2
6	3	3	3

^aPoor (0), fair (1), good (2) and very good (3)

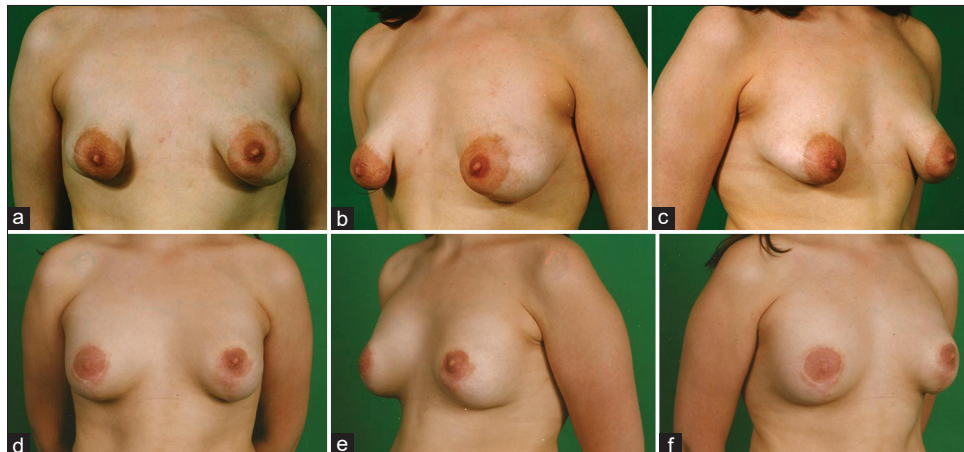


Figure 3: (a-c) Pre-operative view and (d-f) post-operative view

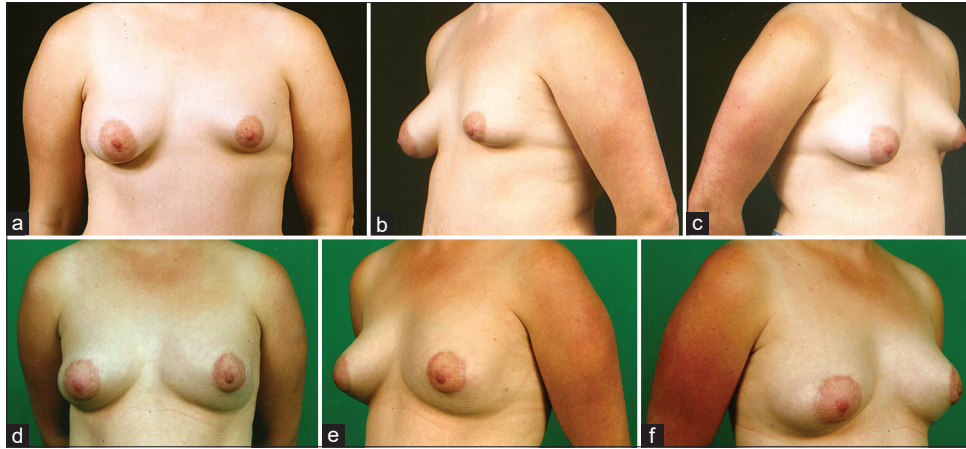


Figure 4: (a-c) Pre-operative view and (d-f) post-operative view

by de-epithelialisation of a doughnut-shaped piece of skin around the periphery of the areola and excision of four wedges of breast tissue from underneath the new areola.^[12]

Dinner and Dowden recognised the various degrees of expression of tuberous breast deformity and proposed addressing each feature individually. They also advocated a full-thickness skin and subcutaneous tissue flap, designed in the submammary fold for correction of the circumferential skin deficiency. However, they reported only one case of fully expressed tuberous breast with no comment on the duration of follow-up.^[13]

Elliot was the first to use a musculocutaneous flap to correct the deformity. He described a serratus musculocutaneous transposition flap for the correction of the infra-areolar skin insufficiency in two patients with severe tuberous breast deformity. The main criticism of his technique was the need for an extensive vertical and inframammary incision and poor aesthetic results due to scarring.^[14,15]

Versaci *et al.* first reported the use of tissue expansion for the treatment of tuberous breast.^[16] Versaci and Rozzelle published a case series of ten tuberous/tubular breasts where they used an inframammary fold incision to introduce either a submammary or subpectoral expander in the first stage. In the second stage, the size of areola was reduced, its deformity corrected and mastopexy performed where required. They admitted not being able to ‘completely eliminate’ the areolar deformity with tissue expansion and periareolar mastopexy and envisaged the possibility of using the operation described by Teimourian to improve the final appearance of the reconstruction.

However, they strongly recommended the use of a two-staged procedure in all but the mildest forms of tuberous breast. Their study lacks in the description of the degree of deformity in the operated breasts and the duration of follow-up.^[17]

de la Fuente and Martín del Yerro reported the use of periareolar mastopexy with mammary implant in a patient with tuberous breast.^[18] Muti described a single-stage procedure using differently shaped glandular flaps and insertion of prosthesis for extremely hypoplastic tuberous breast. Although the results achieved in the three patients illustrated were satisfactory, the application of a single-stage technique is questionable in the presence of extreme hypoplasia with true skin deficiency and inadequate glandular tissue to cover the prosthesis.^[19]

von Heimburg *et al.* published a retrospective study of 68 tuberous breasts which is the largest series to date. They classified the deformity into four types which were further modified in 2000. Their post-operative review showed that Type I deformity can be adequately treated by augmentation or reduction mammoplasty and Type II with spreading of breast tissue in addition. Severe cases (Type III/IV) required additional skin in the subareolar region by tissue expansion or flap procedure to achieve the desired breast shape and avoid a ‘second crease’ deformity. Their classification helped to end the confusion in nomenclature. It also reiterated the fact that recognising the degree of deformity is imperative to the choice of surgical technique and whether a single or two-staged procedure is required.^[9]

Ribeiro *et al.* used a periareolar approach to divide the breast into two portions to disrupt the constricting ring

and make an inferiorly based flap or pedicle to correct the deformity in one-stage without placement of an implant. As advised by the authors, the technique is suitable for patients who want small breasts. However, the medial and lateral extensions of the inferior flap are sacrificed, thus reducing the size of an already hypoplastic breast.^[20]

Atiyeh *et al.* described a one-stage perinipple round block technique where an intra-areolar doughnut of pigmented skin is de-epithelialised to correct the associated mega areola, allowing, at the same time, a port of entry for insertion of a retroglandular breast implant.^[21] However, not all tuberous breasts have areolar enlargement.^[9]

Grolleau *et al.* proposed a classification for breast base anomalies including tuberous breasts. They also proposed a procedure to treat the minor forms of the deformity, using a mammoplasty with a superior pedicle and a lower lateral dermoglandular flap to fill the deficient lower medial quadrant.^[7]

Mandrekas *et al.* (2004) described a procedure for the treatment of the deformity consisting of a periareolar approach and rearrangement of the inferior part of the breast parenchyma by division of the constricting ring, thus creating two breast pillars. These pillars were then allowed to redrape and in cases of volume deficiency, a silicone breast implant placed in a subglandular pocket.^[8] Persichetti *et al.* described a technique using cross-shaped incision on the posterior face of the gland with the aim of redistributing mammary tissue according to traditional quadrants. They also widely dissected the pectoral muscle from the thoracic cage to reduce the compression on the inferior pole of the prosthesis and enhance the 'drop' shape of the breast.^[22]

More recently, there have been a number of publications exploring the role of fat grafting in correction of tuberous breast deformity. We believe that this could be a useful adjunct to conventional surgery. It would however not be possible to use this as the sole technique in patients with severe deformity without releasing the parenchymal constrictions and reducing NAC diameter.^[23,24]

We describe a modified technique for single-stage aesthetic correction of mild and moderate forms of tuberous breast deformity without significant skin deficiency (von Heimburg Type I, Type II and some Type III). Our technique is a modification of previously described procedures based on the concept of redistribution of

available breast tissue to correct the tuberous breast deformity. We prefer to divide the breast into three pedicles to ensure uniform distribution of parenchyma. Furthermore, due to initial steps being similar to Lejour's technique of breast reduction, the procedure is easy to learn.

CONCLUSION

This technique is a simple single-stage procedure based on the redistribution of available breast parenchyma to deficient quadrants. It is easy to learn as most surgeons are already aware of Lejour's technique of breast reduction. We have achieved good aesthetic long-term results with this method without any complications or recurrence.

Financial support and sponsorship

Nil.

Conflicts of interest

There are no conflicts of interest.

REFERENCES

1. Rees TD, Aston SJ. The tuberous breast. *Clin Plast Surg* 1976;3:339-47.
2. Williams G, Hoffman S. Mammoplasty for tubular breasts. *Aesthetic Plast Surg* 1981;5:51-6.
3. Gruber RP, Jones HW Jr. The donut mastopexy: Indications and complications. *Plast Reconstr Surg* 1980;65:34-8.
4. Bass CB. Herniated areolar complex. *Ann Plast Surg* 1978;1:402-6.
5. Vecchione TR. A method for recontouring the domed nipple. *Plast Reconstr Surg* 1976;57:30-2.
6. Puckett CL, Concannon MJ. Augmenting the narrow-based breast: The unfurling technique to prevent the double-bubble deformity. *Aesthetic Plast Surg* 1990;14:15-9.
7. Grolleau JL, Lanfrey E, Lavigne B, Chavoïn JP, Costagliola M. Breast base anomalies: Treatment strategy for tuberous breasts, minor deformities, and asymmetry. *Plast Reconstr Surg* 1999;104:2040-8.
8. Mandrekas AD, Zambacos GJ, Anastasopoulos A, Hapsas D, Lambrinaki N, Ioannidou-Mouzaka L. Aesthetic reconstruction of the tuberous breast deformity. *Plast Reconstr Surg* 2004;113:2231-2.
9. von Heimburg D, Exner K, Kruff S, Lemperle G. The tuberous breast deformity: Classification and treatment. *Br J Plast Surg* 1996;49:339-45.
10. von Heimburg D. Refined version of the tuberous breast classification. *Plast Reconstr Surg* 2000;105:2269-70.
11. Toronto IR. Two-stage correction of tuberous breasts. *Plast Reconstr Surg* 1981;67:642-6.
12. Teimourian B, Adham MN. Surgical correction of the tuberous breast. *Ann Plast Surg* 1983;10:190-3.
13. Dinner MI, Dowden RV. The tubular/tuberous breast syndrome. *Ann Plast Surg* 1987;19:414-20.
14. Elliott MP. A musculocutaneous transposition flap mammoplasty

- for correction of the tuberous breast. *Ann Plast Surg* 1988;20:153-7.
15. Wilkinson TS. Mammoplasty for the tuberous breast. *Ann Plast Surg* 1988;21:294-6.
 16. Versaci AD, Balkovich ME, Goldstein SA. Breast reconstruction by tissue expansion for congenital and burn deformities. *Ann Plast Surg* 1986;16:20-31.
 17. Versaci AD, Rozzelle AA. Treatment of tuberous breasts utilizing tissue expansion. *Aesthetic Plast Surg* 1991;15:307-12.
 18. de la Fuente A, Martín del Yerro JL. Periareolar mastopexy with mammary implants. *Aesthetic Plast Surg* 1992;16:337-41.
 19. Muti E. Personal approach to surgical correction of the extremely hypoplastic tuberous breast. *Aesthetic Plast Surg* 1996;20:385-90.
 20. Ribeiro L, Canzi W, Buss A Jr., Accorsi A Jr. Tuberous breast: A new approach. *Plast Reconstr Surg* 1998;101:42-50.
 21. Atiyeh BS, Hashim HA, El-Douaihy Y, Kayle DI. Perinipple round-block technique for correction of tuberous/tubular breast deformity. *Aesthetic Plast Surg* 1998;22:284-8.
 22. Persichetti P, Cagli B, Tenna S, Simone P, Marangi GF, Li Vecchi G. Decision making in the treatment of tuberous and tubular breasts: Volume adjustment as a crucial stage in the surgical strategy. *Aesthetic Plast Surg* 2005;29:482-8.
 23. Ho Quoc C, Sinna R, Gourari A, La Marca S, Toussoun G, Delay E. Percutaneous fasciotomies and fat grafting: Indications for breast surgery. *Aesthet Surg J* 2013;33:995-1001.
 24. Derder M, Whitaker IS, Boudana D, Marchac A, Hivelin M, Mattar N, *et al*. The use of lipofilling to treat congenital hypoplastic breast anomalies: Preliminary experiences. *Ann Plast Surg* 2014;73:371-7.