

## Prof. Mira Sen (Banerjee) CME Article

# Novel expansion techniques for skin grafts

**Dinesh Kadam**

Department of Plastic and Reconstructive Surgery, A.J. Institute of Medical Sciences and A.J. Hospital and Research Centre, Mangalore, Karnataka, India

**Address for correspondence:** Dr. Dinesh Kadam, Department of Plastic and Reconstructive Surgery, A.J. Institute of Medical Sciences and A.J. Hospital and Research Centre, Mangalore, Karnataka, India. E-mail: drkadam@yahoo.co.in

## ABSTRACT

The quest for skin expansion is not restricted to cover a large area alone, but to produce acceptable uniform surfaces, robust engraftment to withstand mechanical shear and infection, with a minimal donor morbidity. Ease of the technique, shorter healing period and reproducible results are essential parameters to adopt novel techniques. Significant advances seen in four fronts of autologous grafting are: (1) Dermal–epidermal graft expansion techniques, (2) epidermal graft harvests technique, (3) melanocyte-rich basal cell therapy for vitiligo and (4) robust and faster autologous cell cultures. Meek's original concept that the sum of perimeter of smaller grafts is larger than the harvested graft, and smaller the graft size, the greater is the potential for regeneration is witnessed in newer modification. Further, as graft size becomes smaller or minced, these micrografts can survive on the wound bed exudate irrespective of their dermal orientation. Expansion produced by 4 mm × 4 mm sized Meek micrografts is 10-folds, similarly 0.8 mm × 0.8 mm size micrografts produce 100-fold expansion, which becomes 700-fold with pixel grafts of 0.3 mm × 0.3 mm size. Fractional skin harvest is another new technique with 700  $\mu$  size full thickness graft. These provide instant autologous non-cultured graft to cover extensive areas with similar quality of engraftment surface as split skin grafts. Newer tools for epidermal blister graft harvest quickly, with uniform size to produce 7-fold expansions with reproducible results. In addition, donor area heals faster with minimal scar. Melanocyte-rich cell suspension is utilised in vitiligo surgery tapping the potential of hair root melanocytes. Further advances in the cell culture to reduce the cultivation time and provide stronger epidermal sheets with dermal carrier are seen in trials.


## KEY WORDS

Epidermal grafts; micrografts; skin culture; skin expansion; skin graft

## INTRODUCTION

The utility of skin grafts remains a mainstay in the wound management. The standardisation of technique adapted in the last century continues

to be unchallenged.<sup>[1]</sup> However, several shortcomings have limited its use in various clinical settings.<sup>[2]</sup> Two inherent drawbacks of skin graft include limited donor area and permanent donor site sequel with associated morbidity. The current research focuses on addressing

Access this article online	
Quick Response Code:	Website: www.ijps.org
	DOI: 10.4103/0970-0358.182253

This is an open access article distributed under the terms of the Creative Commons Attribution-NonCommercial-ShareAlike 3.0 License, which allows others to remix, tweak, and build upon the work non-commercially, as long as the author is credited and the new creations are licensed under the identical terms.

**For reprints contact:** reprints@medknow.com

**How to cite this article:** Kadam D. Novel expansion techniques for skin grafts. Indian J Plast Surg 2016;49:5-15.

both these aspects, and success of each other is mutually complimenting. It entails extraction of more grafts from a limited donor site by expansion techniques with the overall benefits of early cover, faster healing, better quality of skin resurfacing, lesser donor site scarring and morbidity and avoidance of anaesthesia and hospital stay in some. Early and faster wound coverage results in reduced infection, toxicity, mortality and early rehabilitation of burns.<sup>[3]</sup> Several reports of successful resurfacing of burns wounds above 60% are emerging using novel grafting techniques.<sup>[4,5]</sup> Hitherto available options of wound coverage in a resource-constrained donor site are traditional meshing techniques, multiple re-harvests from donor sites, use of amniotic membrane, allografts, xenografts and engineered skin sheets.<sup>[6-8]</sup> Skin expansion with a regular mesher is available with an expansion ratio of 1:1.5–1:9.<sup>[9]</sup> In practice, the expansion of 1:9 ratio is extremely fragile to handle and difficult to maintain the dermal orientation over the wound bed surface. The drawback of unsightly ‘fishnet’ pattern of the recipient site is inevitable. Moreover, the true expansion ratio is seldom truly achieved in the clinical application.<sup>[10,11]</sup> Multiple re-harvest is a protracted process, with a minimum interval of the 2 week period between each. Besides, the grafts have to be uniformly thin, which is easier with a power dermatome than a manual harvesting knife. There is also a potential risk of donor site complication as dermis becomes thinner with each harvest. Exogenous grafts such as allografts and xenografts are beneficial in acute care and best used as a temporary biological dressing that eventually needs replacement with autologous skin grafts.<sup>[12]</sup> Furthermore, the availability of cadaveric allograft is often limited and requires following strict protocols of tissue banking. Pathogenicity and disease transmission remain at risk, and reported microbiological contamination is 5% despite strict adherence to asepsis.<sup>[13]</sup> Only other option existing for extensive burns with limited donor site is artificial skin substitutes and autologous engineered skin. Of these, tissue-engineered bilayered skin is preferred as they contain both epidermal and dermal components, embedded on artificial extra-cellular matrix. Cultured epithelial autografts (CEAs) devoid of the dermal component, lack both mechanical stability and elasticity. In either case, the time required to develop them is 2–3 weeks before they are suitable for grafting.<sup>[14]</sup> Such Bioengineering facilities currently are sparse and not cost-effective in Indian scenario.<sup>[15]</sup>

Recently, modifications in skin graft techniques have evolved to overcome inadequacies in the donor source as well as unfavourable recipient beds. With these novel methods, the skin expansion is achieved up to the ratio of 1:100-700 from the conventional maximal expansion ratio of 1:9.<sup>[2,16,17]</sup> The techniques described include dermal–epidermal graft expansion with minced micrografts,<sup>[16]</sup> fractional skin harvesting,<sup>[18]</sup> epidermal suction blister grafting<sup>[19,20]</sup> and autologous non-cultured cell therapy.<sup>[21,22]</sup>

## THE BASIS OF EXPANSION AND CHANGING CONCEPTS

Two important concepts form the basis for novel skin grafting and expansion techniques. First, the mathematical model conceptualised by Meek<sup>[23]</sup> that the sum of all quadratic edges or perimeter of the grafts is larger, the smaller the size of the graft is. It is known that keratinocytes migrate from the graft edges to re-epithelialise the wound and hence, multiple pieces of a large graft provide more active edges for regeneration. From the device with multiple blades, he produced postage stamp shaped micrografts which, when spread over the wound, created a multiple island of grafts with faster epithelialisation. Smaller the graft size, the shorter is the distance between them, consequently lesser distance for epithelial migration. Thus, smaller grafts will have greater potential for regeneration at a lesser duration of time. This has been proved in experimental and clinical studies.<sup>[2,4,5,17]</sup>

Second concept is on the dermal orientation of the grafts. It is utmost important that the dermal surface of the graft faces the wound bed for the successful revascularisation, however this has changed with respect to micrografts. The Meek model was not successful during his lifetime simply because the micrografts needed to be placed in a proper dermal orientation with the dermal surface facing the wound bed.<sup>[24]</sup> This was labour-intensive, time-consuming in addition to the high cost of the device. All further modifications of his techniques still required to maintain dermal orientation. Recent findings with micrografting reveal that, when moist environment is provided, the grafts can survive irrespective of the dermal orientation.<sup>[25]</sup> These tiny grafts can survive on the diffusion from the wound bed alone than neovascularisation.<sup>[16]</sup> Thus, shreds of the skin can be simply spread over the wound without the need

for dermal orientation, provided moist environment is maintained in the wound. This has greatly widened the scope and, utilising this advantage, newer devices are designed to 'mince' the grafts for the coverage of larger wound surfaces. These micrografts offer a better quality of re-epithelialisation in terms of uniform resurfacing and stability with shorter duration. In addition, they exhibit a great potential to obviate the need for *in vitro* cultured grafts or allografts. The deterrent, however, remains the cost and availability of the device and, provision and maintenance of moist environment of the grafted wound during the initial phase. There are different techniques of harvests described for dermal-epidermal and epidermal only grafts.

## DERMAL-EPIDERMAL GRAFTING

Dermal-epidermal grafts contain epidermis and variable amount of dermis or full thickness skin. With the inclusion of the dermis, these provide superior resurfacing of wound and stability. The following are expansion techniques described for these grafts.

### The landmark concept of Meek

The concept of micrografts was introduced by Cicero Parker Meek (1914–1979). He worked as a general practitioner at South Carolina, USA, with a great deal of interest in treating burn wounds.<sup>[24]</sup> He is credited for his pioneering invention of a technique of high expansion of split skin graft with his unique instrumentation. He initially devised the instrument in 1958, called the 'Meek dermatome' which was subsequently modified with the help of his engineer friend S.P. Wall and was patented as 'Meek-Wall dermatome'. The dermatome had 13 blade cutters that cut the grafts into small postage stamp grafts of 4 mm × 4 mm size to allow 10-fold skin expansion. The device was driven by an electric motor with additional cork plates as carriers. These small grafts were saturated in the plasma, transferred over the parachute silk and then placed over the wound bed. The technique of graft application needed dermal orientation (dermal side down) for the survival and proliferation, which was both labour-intensive and time-consuming. His technique, though came much before the the introduction of skin meshers it was however, lost in time until Dutch surgeons reintroduced it in 1990s.

### Modified Meek techniques

In 1993, Kreis *et al.* reintroduced a modified Meek technique using a dermatome running on compressed

air.<sup>[26]</sup> The experience reported from different centres shows the usefulness of Meek technique.<sup>[4,27]</sup> With modified Meek technique, expansion ratio of 1:4–1:9 was achieved which was most useful in treating severe burns, in comparison to the meshed grafts, the Meek micrografts provide a true expansion ratio and greater reliability on graft take. Successful grafting of full thickness burns up to 75% has been shown. Micrografts or meshed grafts in combination with cultured grafts and allografts have also been widely used with excellent results. This combination technique improves the engraftment and negates, or at least reduces the drawbacks of both allografts and CEA when used alone.<sup>[28]</sup>

### Flypaper technique

The flypaper technique described by Lee *et al.* principally based again on the original concept of Meek with a simplified device to cut equal-sized grafts. The technique involves cutting the grafts into 5 mm × 5 mm size with a pre-chessboard-designed steel plate using a circular rotating blade. These uniform-sized grafts were placed over gauze impregnated with petroleum jelly, with dermal surface facing upwards in a similar way flies sticking to a flypaper. This allowed true and practical expansion of the skin graft up to 9 times with islands of 5 mm skin. The grafts were placed on the wound by simply inverting and fixing the petroleum jelly gauze. They further modified the placement technique to reduce the maximum distance between grafts by 10–20% from the original technique.<sup>[28]</sup> With their wheel knife and quick cutting plate, the authors claim wound epithelialisation similar to Meek technique, but at a lower cost.

These modified techniques were also laborious and did not provide skin expansion beyond Meek's original technique. However, combination techniques with allografts, xenografts and cultured keratinocytes have circumvented the problems of restricted to donor sites to treat extensive burns. These grafts are superior to meshed ones in terms of lower fragility and higher take, particularly in extensive burns. With shorter a duration of engraftment, overall reduction in the cost, hospital stay and improved patient survival has been reported.<sup>[4]</sup>

### Skin expansion with meshers

Following its introduction in 1994, skin meshing is widely used for large areas of burns and other wounds.<sup>[9-11,29]</sup> Various modifications exist with fixed or interchangeable expansion ratio from 1:1 to 1:9. The advantages include easy adaptability, prevention of fluid collection

underneath grafts and reliable take in moderate to large areas. On the other hand, fish net appearance and difficulties in handling large expansion grafts remain as drawbacks. Moreover, the true expansion ratio beyond 1:1 is questionable. It is seen that increasing expansion ratio results in greater discrepancies between the area predicted and the actual surface area of meshed skin. As a consequence, the estimation of the required donor area may be erroneous.<sup>[11]</sup> Despite these drawbacks, meshed grafts are easy to use and remain a most utilised tool for moderate skin expansion in most clinical settings.

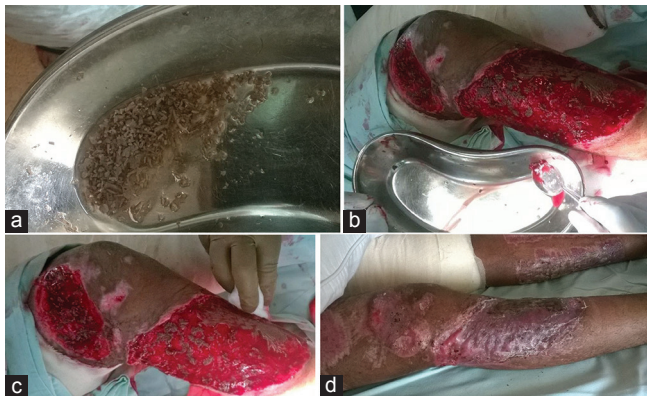
### Micrografts (Xpansion® System)

The split skin graft or full thickness graft when cut into multiple micrografts, each of them act as an individual graft unit and promote regeneration. Keratinocytes and fibroblasts migrate in the wound and form epidermal layer with dermal component.<sup>[30]</sup> Further, the minced grafts have demonstrated over-expression of factors such as tumour necrosis factor-alpha, platelet-derived growth factor and basic fibroblast growth factors, all of them facilitate proliferative healing phase, thus promoting re-epithelialisation, neo-angiogenesis and extra-cellular matrix (ECM) deposition.<sup>[31]</sup> The grafts can be manually minced with blade [Figure 1a-d] or more precisely cut using a device. One such device called Xpansion® Micrografting system (Applied Tissue Technologies, Newton, Mass.) which contain 24 parallel rotating cutting disc with 0.8 mm apart designed to cut the grafts twice in perpendicular direction resulting in 0.8 mm × 0.8 mm sized micrografts [Figure 2a-c]. The sum of each micrograft together increases the boarder length (perimeter) and regeneration capability, thus enabling an expansion ratio of 1:100. The clinical results have indicated that wound

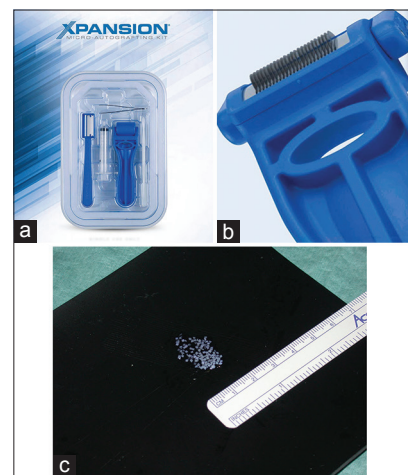healing quality is comparable to the split thickness skin grafting. In a moist wound dressing environment, the dermal orientation of these micrografts did not matter which makes it an easily adaptable procedure.<sup>[5,16,25]</sup> In combination with minced grafts and skin substitute, a single-stage transfer has been described recently, which demonstrates the migration of keratinocytes and fibroblasts into the scaffold, a step towards obviating the necessity of cell cultures.<sup>[30]</sup>

### Minced micrografts - 'pixel' grafting

Extending the technique of Meek micrografts which produced 4 mm × 4 mm sized grafts, the Xpansion® micrografting method produced still smaller grafts of 0.8 mm × 0.8 mm using a handheld device. Further experiments has been done with the hypothesis that, the regenerative potential is higher with smaller grafts when the original skin graft is cut into tiny pieces. This was akin to the pixels on a computer screen, thus termed as 'pixel grafts'.<sup>[32]</sup> The regenerative potentials were studied with 0.3 mm × 0.3 mm grafts in comparison with 0.8 mm × 0.8 mm micrografts on full thickness porcine wounds. A special 'mincing device' was used to cut grafts 10 times (5 times in each perpendicular direction). The study demonstrated similar wound healing potential as with micrografts with respect to parameters such as wound re-epithelialisation, wound contraction, epidermal maturation and rete ridges per mm for the strength of dermo-epidermal junction. The re-epithelialisation rate was significantly faster in the pixel grafts compared to micrografts, implying that a greater number of grafts are available in a given area which create better advantage of regeneration.<sup>[32]</sup>



**Figure 1:** (a) Manually minced split thickness grafts, (b) Grafts applied over the wound as paste, (c) Random spread without dermal orientation (d) Fully epithelialised wound. (Picture courtesy: Dr Surajit Bhattacharya, Plastic surgeon, Lucknow, India)



**Figure 2:** (a) Xpansion® micrografting handheld device, (b) parallel rotating cutting disc, (c) micrografts of uniform 0.8 mm × 0.8 mm size (Picture Courtesy : Dr. Elof Eriksson MD, PhD, Applied Tissue Technologies)



### Mini punch grafting

Punch grafts are harvested using a skin punch or surgical punch instrument, a technique interestingly evolved from the bone trephine instrumentations. The method, though exists since early 1970s, with the present technique, 1.2–1.5 mm sized grafts are procured. It is almost exclusively employed for treating leucodermas, where melanocytes from the graft have been shown to spread centrifugally about 1–2 mm from the edge and recolonise the surrounding epidermis to achieve repigmentation [Figure 3a-c]. Despite the fact that the technique and the concept are simple, the procedure is labour-intensive. It involves using a sharp punch instrument of same size for both donor and recipient and placing grafts from a donor site directly over punch impressions of the recipient area. The punches need to be close to each other to allow complete repigmentation, and grafts are to be placed taking care to avoid any rolled edges and upside-down orientation. Despite many reported successful studies for both body and face, the technique still remains unreliable with several drawbacks. The complications include cobblestone appearance, colour mismatch, variegated appearance, a static graft (no pigmentation), peri-graft halo, graft depigmentation, hypertrophic scars and keloid formation.<sup>[33-35]</sup>

### Fractional skin harvesting

Conceptually, it is similar to punch graft with respect to the thickness and composition. In this new technique, a large number of microscopic full thickness skin graft columns are harvested with the advantages of good quality skin and faster healing of donor sites with minimal scarring. The concept evolved from the photothermolysis technique

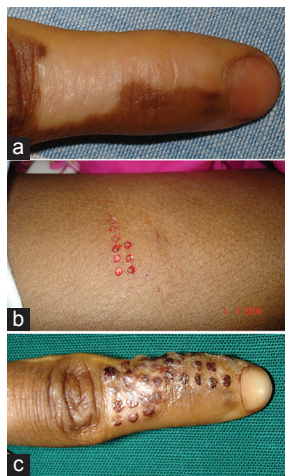
where, when the skin was subjected to laser microbeams of 300 µm diameter to create a microthermal zones, the epidermal closure occurred within 24 h followed by dermal healing within 2 weeks.<sup>[36]</sup> The fractional skin grafts are full thickness grafts, harvested using customised hypodermic needles with double cutting edge of 700 µm diameters. These columns of tissue are extracted by suction into a collection basket. The micrografts are then randomly spread over the wound without dermal orientation. Results have shown that the quality wound cover is similar to the split skin graft technique.<sup>[18]</sup> The grafted surface is smooth and uniform unlike fishnet appearance with meshed skin grafts. The biggest advantage in addition is, the minimal donor scar with faster epithelialisation.

### EPIDERMAL GRAFTING

Although split thickness skin graft (SSG) remains a mainstay in treating chronic wounds, it may not be ideal in certain skin disorders such as leucoderma. Donor site considerations of additional wound and scarring remain a concern. Epidermal grafts primarily consist of epidermis devoid of the dermis, and donor site heals with minimal scarring. Epidermal-only cells in the absence of the dermal component adopt most of the characteristics of recipient area, resulting in better colour match with surrounding skin and superior aesthetic outcome.<sup>[37]</sup> These, however, are not as much stable as SSG to withstand mechanical stress and shear. Their best utility remains for vitiligo.

### Suction blister epidermal grafting

Described by Falabella, this technique involves harvesting of ultra-thin skin grafts consisting of only epidermis by inducing physiological split at the dermo-epidermal junction.<sup>[38]</sup> They are also known as bubble grafts where sustained negative pressure of -200 - -500 mm of Hg by suction is applied to disrupt dermo-epidermal junction until the graft erupts as a blister. The time required for the formation of suction blisters is inversely related to the skin temperature. The blisters are cleaved through the lamina lucida of the dermo-epidermal junction which induces a minimal inflammatory response. The healing is faster with lesser pain, thus the harvesting can be performed in an outpatient setting without anaesthesia. The technique involves induction of blister on the donor area which is generally the outer thigh or the inner arms. A 10-cc syringe is applied over the skin as a suction cup, and the nozzle is connected to a 50-cc syringe with three-way stop cannula to create negative pressure. Once the suction pressure is created with 50-cc



**Figure 3:** (a) Vitiligo of right index finger, (b) Mini punch graft harvesting, (c) Re-pigmentation seen one week following grafting. (Picture courtesy: Dr Girish P N, Dermatologist, Mangalore, India)

syringe, the communication between two syringes is turned off with three-way stop cannula.<sup>[39]</sup> Foot-operated suction machine can also be used to create suction pressure.<sup>[40]</sup> While blisters erupt by 90–120 min, for adequate formation, 4 h of suction may be needed, and yet it is unpredictable and incomplete at times. The ideal blister is single, unilocular and non-haemorrhagic. The grafts are obtained by de-roofing the blister. Recipient site is dermabraded prior to the placement of the graft. The melanocyte transfer takes place within 48–72 h to the underlying dermal surface. These grafts, though, are in use for the past four decades for hypopigmented lesions, have not gained wider acceptance due to complicated, cumbersome and time-consuming procedure of harvesting. Localised stable vitiligo lesions over lips, eyelids, areola of breast, genitalia, etc., are ideal indications, but partial graft uptake can lead to cosmetic disfigurement<sup>[41]</sup>

#### Epidermal micrografts - multiple 'microdome' technique

An automated epidermal harvesting system for suction blister epidermal grafting (CelluTome Epidermal Harvesting Device; Kinetic Concepts, Inc. [KCI], San Antonio, Texas, USA) consisting of multiple 'microdome' has been recently introduced [Figure 4]. The connected vacuum system creates -400 - -500 mm of Hg negative pressure for a short period of 30–60 min to induce multiple bubbles in the microdome. The micrografts are then harvested by a transparent film sticking to these micro bubbles.<sup>[17]</sup> The film with grafts is placed over the wound keeping the dermal surface to the wound. This method is designed to achieve 1:6 expansion ratio, and the micrografts are uniformly spaced at 2 mm distance maintaining their dermal orientation on the recipient bed. The average viability of epidermal micrografts achieved in a study is 99.5%, which is reliable and reproducible by generating uniform viable micrografts with this system.<sup>[17]</sup> The method carries greater donor-site benefits with minimal pain, faster healing, better scar and less cumbersome to the patients than the traditional harvests.

The use of epithelial and micro-blister grafts is limited to treating hypopigmented lesions such as vitiligo and congenital hypomelanotic conditions. Though it is successful in terms of graft uptake, the degree of pigment spread is inconsistent and variable in individual patients.<sup>[19]</sup> Apart from this, smaller acute and chronic wounds are also treated with the advantages of minimal donor-site problems. Epidermal grafts in addition to providing



**Figure 4:** CelluTome™ epidermal harvesting system. (source : <http://www.kci1.com/KCI1/cellutome>)

autologous keratinocytes, act as a bioengineered skin and promote wound healing through the release of autologous keratinocytes and growth factors.<sup>[2]</sup>

## CELL-BASED THERAPIES

Cytherapy or cell-based therapy involves a process to replace a lost or injured tissue with cultured cells. Autologous cell transplantation is the most ideal way to restore lost or injured tissue without the trepidation of rejection. The epidermis forms the outermost layer of the skin with constant regeneration of keratinocytes, a predominant cell of this layer. Transplantation of these cultured keratinocytes was a turning point in the novel technique of skin grafting, following its introduction in 1975 by Rheinward and Green *et al.* Since then, CEAs are in use worldwide despite limitations.<sup>[42]</sup>

#### Cultured epithelial autografts

This involves the ability to grow sheets of keratinocytes, *in vitro* by taking a simple skin biopsy. Epidermis contain epidermal stem cells (EpSCs), and transplantation of these cells along with keratinocytes is of vital importance for the good take of CEAs and permanent regeneration of epidermis.<sup>[43]</sup> The cell clusters containing these EpSc are known as 'holoclones' and depletion of them during cultivation and transportation results in reduced take of CEAs.<sup>[44]</sup> Prior to 1994, the application of CEAs was limited to confluent cell sheets. Studies employing CEA in treating major burns have shown 70% final engraftment and most significantly, improved overall patient survival of 90%.<sup>[45,46]</sup> The euphoria of this success, however, was limited following the reports of disappointing results and complications.<sup>[44,47]</sup> The critical evaluation of available

literature for the evidence of usefulness of the CEA in treating major burns could not establish its beneficial role conclusively.<sup>[14]</sup> The major limiting factors found are the time required to culture CEA sheets, the inconsistency in graft take ranging from nil to 100%, vulnerability of grafts for infections and mechanical shear, lack of long-term durability, hypertrophic scar and the high cost involved in such treatment.<sup>[14]</sup> In addition, the application demands ideal wound conditions with control of infection.<sup>[43]</sup> At present, CEAs are considered a useful tool for an early cover, as a lifesaving measure and not as a durable long-term coverage option.<sup>[48]</sup> Good results are observed with CEA application in partial thickness burns, however dermal substitute is recommended in full thickness wounds.<sup>[14]</sup>

### Autologous cultured cell suspension

This technique was introduced in 1994, wherein, a confluent of cultured cell sheets is detached from the action of enzyme dispase or trypsin to produce keratinocyte cell suspension for transplantation. This, however, rendered cells incapable of adhering to tissues due to injury to cellular proteins such as integrin, thus decreasing the survival rate of cell sheets.<sup>[49]</sup> To circumvent this drawback, cells were transferred to the patient wound from *in vitro* 'pre-confluent stage' prior to the formation of sheets. The cells were thus allowed to actively proliferate and adhere to the wound bed *in vivo* with several advantages of reduced time, minimal enzymatic degradation and better quality of resurfacing with more robust dermal epithelialisation. The transplant of pre-confluent epithelial cells to the wound surface is carried out with a delivery system. Two types of delivery methods currently used are: (1) Application as thin sheets of cell made of either synthetic or non-synthetic material and (2) Spray of cell suspension into the wound.<sup>[50]</sup>

The efficacy of suspension of the pre-confluent epithelial cells, when applied by spraying was studied in full thickness burn wounds in combination with 1:6 meshed skin grafts. A suspension form of cultured epithelial cells developed by Keraheal™ (CEA, Keraheal™, Seoul, Korea, MCTT) was used with fibrin glue to facilitate the attachments of epithelial cells. The graft uptake rates were 37.6%, 68.0% and 90.0% on an average at 2, 4 and 8 weeks, respectively, with 1 ml cell suspension per 497.5 cm<sup>2</sup> area of full thickness burn wounds with good quality of scar.<sup>[51]</sup>

Cultured epithelial cells have its place for the use in extensive burns as a lifesaving measure, however, their vulnerability and fragility preclude them as an option

for a stable cover. The current research is focusing on the additional measures with the inclusion of ECM to produce sheets close to the properties of the skin graft and improve their clinical applicability. A range of delivery system for the effective clinical application is developed from biological and synthetic materials.<sup>[50,52]</sup> They include collagens, hyaluronic acid membrane, fibrin matrix and amniotic membrane. The acellular dermal matrix (ADM) is the dermis with cellular material removed and contains matrix or scaffold composed of materials such as collagen, hyaluronic acid and fibronectin. This scaffold allows regeneration of tissue, revascularisation and repopulation of cellular elements, which resists infection. This scaffold gets disintegrated in a gradual manner until fully replaced by the host collagen to provide stability to CEAs. Currently, there are three kinds of ADMs available obtained from human and different animal species, which include porcine ADMs and bovine foetal collagen.<sup>[48]</sup> Fibrin glue template when mixed with cell suspension is shown to be an excellent delivery substance with good clinical results.<sup>[43,52]</sup>

### Autologous non-cultured cell therapy

Despite advances such as introduction delivery system and cell spray technique in cultured autografts, considerable time delay remains a drawback. *In vitro* CEAs even with sub-cultured cells require a minimum of 2–3 weeks for clinical application. In addition, the cultured cells contain pre-dominantly keratinocytes, as melanocytes get depleted with serial subcultivation.<sup>[53]</sup> To overcome the delay and the cost, use of non-cultured autologous cells have been explored.<sup>[22]</sup> A recently adopted technology in which the harvesting, separation of cells and spraying over the wound as one step process is emerging.<sup>[54]</sup> A recognised commercial product using this technique is ReCell™. Following the harvest of skin graft, cell separation with trypsin solution and incubation for 20 min is done. After digestion, the sample is mechanically agitated to separate the cells. Finally, the cells are suspended in a lactate solution and sprayed over the wound, a process similar to cell spray techniques.<sup>[55]</sup> It is shown to achieve a 1:80 expansion ratio, which is useful, particularly for large areas of burns.<sup>[20]</sup> Advantages of this technique include quick application and the possibility of treating large areas without the need for a scaffold.<sup>[54,56,57]</sup>

The concern was about the loss of viable cells due to mechanical pressure while spraying and negative impact of faster isolation on cell viability. The study by Wood

*et al.* shows comparable viable isolate cells with ReCell® technique to others. A single ReCell® suspension contains approximately  $1.7 \times 10^6$  viable cells per  $\text{cm}^2$  harvested tissue from the dermal-epidermal junction, which is similar to other methods. The percentage of cells

isolated that are viable is approximately 75% at initial harvest and 70% following application through the spray device. Though the spraying, reduced the number of cells marginally, viability of cells is not affected.<sup>[21]</sup> In addition, characterisation of cell suspension showed 30.3% of

Table 1: Summary of expansion techniques

Techniques	Graft thickness	Size	Expansion ratio	Dermal orientation	Advantages	Limitations*
<b>Dermal-epidermal grafts</b>						
Meek micrografts	Partial	4×4 mm	1:4-1:9	Required	Achieves true expansion	Labour intensive. Original technique out of favour.
Modified meek micrografts	Partial	5×5 mm	1:9	Required	Achieves true expansion, technically easier	Labour intensive. Different instrumentation.
Meshed grafts	Partial	Sheets	1:1-1:9	Required	Common practice with easily available instrumentation and application	True expansion not achieved. Too fragile to handle grafts with higher ratio.
Xpansion <sup>(R)</sup> Micrografts	Partial	0.8×0.8 mm	1:80-1:100	Not required	Hand held device for precise graft cut High expansion	Availability of instrumentation*. Multiple sittings for extensive areas
Pixel Micrografting	Partial	0.3×0.3 mm	1:400-700	Not required	Highest reported expansion ratio	Only preliminary reports available.
Mini punch grafts	Full	1.2 mm	1:1 FTSG	Required	Widely practiced	Precise donor and recipient punching necessary.
Fractional skin harvest	Full	700 $\mu$ diameter	Not specified	Not required	Good quality resurfacing with negligible donor morbidity	Only preliminary reports available.
Suction blister epidermal grafting	Epidermal grafts	10 mm	1:1 SSG	Required	Well established	Time consuming. Unpredictable blisters and results.
Epidermal micrografts with Cellu Tome <sup>TM</sup>	Epidermal grafts	2 mm	1:6	Required	Precise-sized grafts and uniformly spread on the wound. Short harvesting time	Availability of instrumentation*. Preliminary stage
<b>Cell-based therapies</b>						
Autologous cultured cell suspension ( <i>In vitro</i> cultivation from small skin biopsy)	CEA sheets or cell suspension	Varied	1:1000	Require for bilayered sheets	Lifesaving in extensive burns. Only small skin biopsy suffices. Good for partial thickness wounds	Time delay. Needs dermal component for epithelial support. vulnerable for infection and mechanical shear
Autologous non-cultured cell suspension ReCell <sup>TM</sup>	Epidermal grafts	Cell suspension	1:80-1:100	Spray of cells	Single stage, reduced time. High expansion	Availability of instrumentation*. Concern about loss of cell.
<b>Melanocyte enriched cell suspensions for vitiligo</b>						
Non-cultured epithelial cell suspension	Partial or full thickness	Melanocyte: Keratinocyte ratio 1:36	1:6	Enzyme degradation	Single stage, cost effective	Un predictable re pigmentation. Low melanocyte ratio.
Hair follicle cell suspension	FUE harvest/ plucked hair harvest	Melanocyte: Keratinocyte ratio 1:1-1:6	Not specified	Enzyme degradation with and melanocyte medium	Higher potential with abundant melanocytes	Technically more demanding. Reports are preliminary.

FUE: Follicular unit extraction, CEA: Cultured epithelial autografts, SSG: Split thickness skin graft, FTSG: Full-thickness skin graft, \*Limitations of availability of instrumentation is with respect to India



fibroblast and 3.5% of the melanocyte cell population along with 64% keratinocytes. This is significant in contrast to prolonged culture where melanocytes are depleted. Viable melanocytes provide pigmentation, which is an additional advantage over cell cultures. The drawback, however, is the high costs, which limits routine use of this technique.

## MELANOCYTE ENRICHED CELLULAR GRAFTING TECHNIQUES IN VITILIGO SURGERY

Large areas of vitiligo are difficult to treat owing to paucity of donor area, and cultured melanocyte (CM) transfers are largely out of practice. Current approaches with cellular therapy or grafting technique include non-cultured basal epidermal suspension (NCES), the hair follicle outer root sheath (ORS) cell suspension, besides CMs or cultured epidermis.

Non-cultured epidermal cell suspension (NCES) is a well-accepted method to treat large areas of vitiligo, which provides basal cell-rich suspension containing melanocytes.<sup>[19]</sup> The technique involves skin biopsy and similar steps of trypsin enzymatic degradation of dermo-epidermal junction, incubation, followed by centrifugation at 2000 RPM  $\times$  10 min of the tube containing melanocytic medium (Dulbecco's Modified Eagles Medium). Basal cell-rich suspension is then evenly applied with 1 ml syringe over dermabraded areas of vitiligo. The onset of pigmentation occurs by 3–6 weeks and completed within 2–6 months. The advantages include 1:10 expansion ratio to treat large areas, faster and uniform pigmentation to match the surrounding areas. It can be used over the difficult areas such as joints, mucosa and pressure points. Further, it does not need an expensive laboratory facility as the procedure can be carried out in the operating room itself. Requirement, however, includes equipment, media and incubator. The procedure can be accomplished with high success rate at a lower cost.

### Hair follicle cell suspension

This is another emerging technique of non-cultured cell therapy in vitiligo. It was Cui *et al.*'s landmark observation that melanocytes residing in ORS and bulge areas of hair follicle become active when stimulated by ultraviolet rays and following dermabrasion.<sup>[58]</sup> These are inactive, DOPA-negative melanocytes and now,

considered to be melanocytic stem cells that migrate upwards along the hair follicle and spread pigmentation centrifugally. It is also observed that in vitiligo lesions, only active melanocytes (DOPA positive) are affected and not the inactive cells. There is a distinct difference between epidermal melanocytes and hair follicle ones. The anagen hair bulb melanogenic melanocytes are larger, more dendritic which contain extensive golgi and rough endoplasmic reticulum and produce larger melanosomes with remarkable synthetic capacity.<sup>[59]</sup> Relatively small number of melanocytes can potentially produce sufficient melanin to pigment up to 1.5 m of hair shaft.<sup>[60]</sup> The ratio of melanocytes to keratinocytes is 1:5 in hair follicle ORS suspension in contrast to 1:36 in epidermal cell suspension. Different techniques of harvest have been described from punch graft from scalp to plucking the hair and more recently, as follicular units similar to that of follicular unit extraction (FUE) technique in hair transplantation. The adaptation FUE technique is based on the evidence that they contain more potential melanocytic 'stem cells' than plucked hair follicle and its successful application in hair transplantation in contrast to the plucked hair transplants.<sup>[61]</sup>

The procedure includes FUE followed by similar steps of the epidermal cell suspension technique, which includes treatment with enzyme, repeated incubation and centrifugation in the media. The advantages are inconspicuous donor scar, high yield of melanocyte with melanocyte–keratinocyte ratio of 1:1–1:6 against 1:36 of NCES. About 15–25 follicular units provide 25,000–50,000 cells rich in melanocyte, which is sufficient for 25 cm<sup>2</sup> area resurfacing. The results of the follicular unit ORS suspension showed stable repigmentation in over 75% patients at 1 year.<sup>[61]</sup> Similar results are reported with ORS-derived melanocyte (plucked hair) suspension technique as well.<sup>[62]</sup> The technique, though simple, is skill-dependent to harvest in FUE technique. These techniques are still in nascent stage awaiting further clinical trials and long-term results. The concern about, the greying of melanocyte is seen with ageing and still remains a drawback.

### Summary

Clinical applications of new skin graft expansion techniques have demonstrated promising results [Table 1]. The benefits are manifold in treating large burns with limited donor area. Quicker donor site

healing with minimal scar is an additional secondary beneficial outcome. The methods with newer devices are less laborious and less technically demanding as seen in preliminary reports. Dermal orientation-independent survivals of minced grafts allow effortless application. In addition, the regenerating potential of micrografts is enhanced with the presence of epidermal stem cells and pigment-producing stem cells. The micrografting has potential to obviate the need of cultured skin and drawbacks associated with it. The various combinations of meshed grafts, micrografts and cultured autografts are in use to tap each of their potential. Further studies are needed to validate the advantages over conventional techniques of skin grafting.

### Financial support and sponsorship

Nil.

### Conflicts of interest

There are no conflicts of interest.

## REFERENCES

- Chick LR. Brief history and biology of skin grafting. *Ann Plast Surg* 1988;21:358-65.
- Singh M, Nuutila K, Kruse C, Robson MC, Caterson E, Eriksson E. Challenging the conventional therapy: Emerging skin graft techniques for wound healing. *Plast Reconstr Surg* 2015;136:524e-30e.
- Munster AM, Smith-Meek M, Sharkey P. The effect of early surgical intervention on mortality and cost-effectiveness in burn care, 1978-91. *Burns* 1994;20:61-4.
- Xu Q, Cai C, Yu Y, Tang Y, Hu D, Liu S, *et al.* Meek technique skin graft for treating exceptionally large area burns. *Zhongguo Xiu Fu Chong Jian Wai Ke Za Zhi* 2010;24:650-2.
- Danks RR, Lairet K. Innovations in caring for a large burn in the Iraq war zone. *J Burn Care Res* 2010;31:665-9.
- Atiyeh BS, Hayek SN, Gunn SW. New technologies for burn wound closure and healing – Review of the literature. *Burns* 2005;31:944-56.
- Sawhney CP. Amniotic membrane as a biological dressing in the management of burns. *Burns* 1989;15:339-42.
- Garfein ES, Orgill DP, Pribaz JJ. Clinical applications of tissue engineered constructs. *Clin Plast Surg* 2003;30:485-98.
- Vandeput J, Nelissen M, Tanner JC, Boswick J. A review of skin meshers. *Burns* 1995;21:364-70.
- Kamoliz LP, Schintler M, Parvizi D, Selig H, Lumenta DB. The real expansion rate of meshers and micrografts: Things we should keep in mind. *Ann Burns Fire Disasters* 2013;26:26-9.
- Lyons JL, Kagan RJ. The true meshing ratio of skin graft meshers. *J Burn Care Res* 2014;35:257-60.
- Chiu T, Burd A. "Xenograft" dressing in the treatment of burns. *Clin Dermatol* 2005;23:419-23.
- Obeng MK, McCauley RL, Barnett JR, Heggors JP, Sheridan K, Schutzler SS. Cadaveric allograft discards as a result of positive skin cultures. *Burns* 2001;27:267-71.
- Wood FM, Kolybaba ML, Allen P. The use of cultured epithelial autograft in the treatment of major burn injuries: A critical review of the literature. *Burns* 2006;32:395-401.
- Singh AK, Shenoy YR. Skin substitutes: An Indian perspective. *Indian J Plast Surg* 2012;45:388-95.
- Hackl F, Bergmann J, Granter SR, Koyama T, Kiwanuka E, Zuhaili B, *et al.* Epidermal regeneration by micrograft transplantation with immediate 100-fold expansion. *Plast Reconstr Surg* 2012;129:443e-52e.
- Serena TE. Use of epidermal grafts in wounds: A review of an automated epidermal harvesting system. *J Wound Care* 2015;24 4 Suppl: 30-4.
- Tam J, Wang Y, Farinelli WA, Jiménez-Lozano J, Franco W, Sakamoto FH, *et al.* Fractional skin harvesting: Autologous skin grafting without donor-site morbidity. *Plast Reconstr Surg Glob Open* 2013;1:e47.
- Gou D, Currimbhoy S, Pandya AG. Suction blister grafting for vitiligo: Efficacy and clinical predictive factors. *Dermatol Surg* 2015;41:633-9.
- Richmond NA, Lamel SA, Braun LR, Vivas AC, Serena T, Kirsner RS. Epidermal grafting using a novel suction blister-harvesting system for the treatment of pyoderma gangrenosum. *JAMA Dermatol* 2014;150:999-1000.
- Wood FM, Giles N, Stevenson A, Rea S, Fear M. Characterisation of the cell suspension harvested from the dermal epidermal junction using a ReCell® kit. *Burns* 2012;38:44-51.
- De Angelis B, Migner A, Lucarini L, Agovino A, Cervelli V. The use of a non cultured autologous cell suspension to repair chronic ulcers. *Int Wound J* 2015;12:32-9.
- Meek CP. Successful microdermagrafting using the Meek-Wall microdermatome. *Am J Surg* 1958;96:557-8.
- Ottomann C, Hartmann B, Branski L, Krohn C. A tribute to Cicero Parker Meek. *Burns* 2015;41:1660-3.
- Hackl F, Kiwanuka E, Philip J, Gerner P, Aflaki P, Diaz-Siso JR, *et al.* Moist dressing coverage supports proliferation and migration of transplanted skin micrografts in full-thickness porcine wounds. *Burns* 2014;40:274-80.
- Kreis RW, Mackie DP, Vloemans AW, Hermans RP, Hoekstra MJ. Widely expanded postage stamp skin grafts using a modified Meek technique in combination with an allograft overlay. *Burns* 1993;19:142-5.
- Raff T, Hartmann B, Wagner H, Germann G. Experience with the modified Meek technique. *Acta Chir Plast* 1996;38:142-629.
- Lee SS, Tsai CC, Lai CS, Lin SD. An easy method for preparation of postage stamp autografts. *Burns* 2000;26:741-9.
- Raff T, Hartmann B, Wagner H, Germann G. Experience with the modified Meek technique. *Acta Chir Plast* 1996;38:142-6.
- Sharma K, Bullock A, Ralston D, MacNeil S. Development of a one-step approach for the reconstruction of full thickness skin defects using minced split thickness skin grafts and biodegradable synthetic scaffolds as a dermal substitute. *Burns* 2014;40:957-65.
- Pertusi G, Tiberio R, Graziola F, Boggio P, Colombo E, Bozzo C. Selective release of cytokines, chemokines, and growth factors by minced skin *in vitro* supports the effectiveness of autologous minced micrografts technique for chronic ulcer repair. *Wound Repair Regen* 2012;20:178-84.
- Singh M, Nuutila K, Kruse C, Dermietzel A, Caterson EJ, Eriksson E. Pixel grafting: An evolution of mincing for transplantation of full-thickness wounds. *Plast Reconstr Surg* 2016;137:92e-9e.
- Falabella R. Repigmentation of leukoderma by minigrafts of normally pigmented, autologous skin. *J Dermatol Surg Oncol* 1978;4:916-9.
- Malakar S, Dhar S. Treatment of stable and recalcitrant vitiligo by autologous miniature punch grafting: A prospective study of 1,000 patients. *Dermatology* 1999;198:133-9.

35. Lahiri K, Malakar S, Sarma N, Banerjee U. Repigmentation of vitiligo with punch grafting and narrow-band UV-B (311 nm) – A prospective study. *Int J Dermatol* 2006;45:649-55.
36. Manstein D, Herron GS, Sink RK, Tanner H, Anderson RR. Fractional photothermolysis: A new concept for cutaneous remodeling using microscopic patterns of thermal injury. *Lasers Surg Med* 2004;34:426-38.
37. Salim T. Surgical management of vitiligo. In: Lahiri K, Chatterjee M, Sarkar R, editors. *Pigmentary Disorders: A Comprehensive Compendium*. 1<sup>st</sup> ed. New Delhi: Jaypee Brothers Medical Publishers (P) Ltd.; 2014. p. 227-40.
38. Falabella R. Epidermal grafting. An original technique and its application in achromic and granulating areas. *Arch Dermatol* 1971;104:592-600.
39. Burm JS. Simple suction device for autologous epidermal grafting. *Plast Reconstr Surg* 2000;106:1225-6.
40. Gupta S, Ajith C, Kanwar AJ, Kumar B. Surgical pearl: Standardized suction syringe for epidermal grafting. *J Am Acad Dermatol* 2005;52:348-50.
41. Savant SS. Surgical therapy of vitiligo: Current status. *Indian J Dermatol Venereol Leprol* 2005;71:307-10.
42. Green H, Kehinde O, Thomas J. Growth of cultured human epidermal cells into multiple epithelia suitable for grafting. *Proc Natl Acad Sci U S A* 1979;76:5665-8.
43. Huang L, Burd A. An update review of stem cell applications in burns and wound care. *Indian J Plast Surg* 2012;45:229-36.
44. Pellegrini G, Ranno R, Stracuzzi G, Bondanza S, Guerra L, Zambruno G, *et al*. The control of epidermal stem cells (holoclones) in the treatment of massive full-thickness burns with autologous keratinocytes cultured on fibrin. *Transplantation* 1999;68:868-79.
45. Carsin H, Ainaud P, Le Bever H, Rives J, Lakhel A, Stephanazzi J, *et al*. Cultured epithelial autografts in extensive burn coverage of severely traumatized patients: A five year single-center experience with 30 patients. *Burns* 2000;26:379-87.
46. Sood R, Roggy D, Zieger M, Balledux J, Chaudhari S, Koumanis DJ, *et al*. Cultured epithelial autografts for coverage of large burn wounds in eighty-eight patients: The Indiana University experience. *J Burn Care Res* 2010;31:559-68.
47. Still JM Jr., Orlet HK, Law EJ. Use of cultured epidermal autografts in the treatment of large burns. *Burns* 1994;20:539-41.
48. Fang T, Lineaweaver WC, Sailes FC, Kisner C, Zhang F. Clinical application of cultured epithelial autografts on acellular dermal matrices in the treatment of extended burn injuries. *Ann Plast Surg* 2014;73:509-15.
49. Stenn KS, Link R, Moellmann G, Madri J, Kuklinska E. Dispase, a neutral protease from *Bacillus polymyxa*, is a powerful fibronectinase and type IV collagenase. *J Invest Dermatol* 1989;93:287-90.
50. Chester DL, Balderson DS, Papini RP. A review of keratinocyte delivery to the wound bed. *J Burn Care Rehabil* 2004;25:266-75.
51. Lee H. Outcomes of sprayed cultured epithelial autografts for full-thickness wounds: A single-centre experience. *Burns* 2012;38:931-6.
52. Ronfard V, Rives JM, Neveux Y, Carsin H, Barrandon Y. Long-term regeneration of human epidermis on third degree burns transplanted with autologous cultured epithelium grown on a fibrin matrix. *Transplantation* 2000;70:1588-98.
53. Compton CC, Warland G, Kratz G. Melanocytes in cultured epithelial grafts are depleted with serial subcultivation and cryopreservation: Implications for clinical outcome. *J Burn Care Rehabil* 1998;19:330-6.
54. Böttcher-Haberzeth S, Biedermann T, Reichmann E. Tissue engineering of skin. *Burns* 2010;36:450-60.
55. Gravante G, Di Fede MC, Araco A, Grimaldi M, De Angelis B, Arpino A, *et al*. A randomized trial comparing ReCell system of epidermal cells delivery versus classic skin grafts for the treatment of deep partial thickness burns. *Burns* 2007;33:966-72.
56. Wood FM, Stoner ML, Fowler BV, Fear MW. The use of a non-cultured autologous cell suspension and Integra dermal regeneration template to repair full-thickness skin wounds in a porcine model: A one-step process. *Burns* 2007;33:693-700.
57. Cervelli V, De Angelis B, Balzani A, Colicchia G, Spallone D, Grimaldi M. Treatment of stable vitiligo by ReCell system. *Acta Dermatovenereol Croat* 2009;17:273-8.
58. Cui J, Shen LY, Wang GC. Role of hair follicles in the repigmentation of vitiligo. *J Invest Dermatol* 1991;97:410-6.
59. Tobin DJ, Paus R. Graying: Gerontobiology of the hair follicle pigmentary unit. *Exp Gerontol* 2001;36:29-54.
60. Slominski A, Wortsman J, Plonka PM, Schallreuter KU, Paus R, Tobin DJ. Hair follicle pigmentation. *J Invest Dermatol* 2005;124:13-21.
61. Kumar A, Mohanty S, Sahni K, Kumar R, Gupta S. Extracted hair follicle outer root sheath cell suspension for pigment cell restoration in vitiligo. *J Cutan Aesthet Surg* 2013;6:121-5.
62. Vanscheidt W, Hunziker T. Repigmentation by outer-root-sheath-derived melanocytes: Proof of concept in vitiligo and leucoderma. *Dermatology* 2009;218:342-3.