Published online: 2019-08-26

Surgical revirgination: Four vaginal mucosal flaps for reconstruction of a hymen

Sir,

We read with interest, the original article "Surgical revirgination: Four vaginal mucosal flaps for reconstruction of a hymen"[1] published in your reputed journal. We must congratulate the author for a commendable and innovative approach based on the principles of plastic surgery.

Hymenoplasty or hymenorrhaphy is in increasing demand due to the traditional sociocultural belief associated with virginity; being still illegal in some countries, it creates a multitude of moral, ethical, social and religious controversies; one finds a lot more information on the internet than in scientific journals.

Any reconstruction should "replace like with like tissues" with the aim of matching colour, texture and thickness, and also the final appearance to be normal. As described, the flaps X and X' overlap whereas flaps Y and Y' overlap leaving no raw areas (Figure 1 redrawn from Saraiya). How does this cruciate flap heal (XX' with YY') as there is no raw area between them?

As the author uses the flaps from the vaginal mucosa for hymen reconstruction and primarily closes the donor site, there is a chance of iatrogenic vaginal stenosis and subsequent risk of dyspareunia; the use of tough vaginal mucosa is akin to creating a transverse vaginal septum with the consequent risk of infertility.

The final appearance following this reconstruction is "network-like" as the author describes it, whereas the appearance after hymenoplasty following repair described by Prakash[2] and Ou[3] is annular. There being so many normal anatomical variations of normal hymen such as annular, crescentic, cribriform, eccentric, septate and microperforated, which one of these forms should one aim to reconstruct and what will be the advantage of one hymeneal type over the other that the author recommends this method to be better?

There are many unanswered issues about this controversial, but still curious procedure. The author describes the reconstruction to be strong enough to sustain daily activities, but how strong should these reconstructions be? How long these repairs should last? When should hymenoplasty be planned in relation to the proposed first intercourse? Moreover what reconstruction would be considered good as there are so many anatomic variations?

How do we assess the success of these surgeries? Is it based on immediate appearance after repair? Or is it its

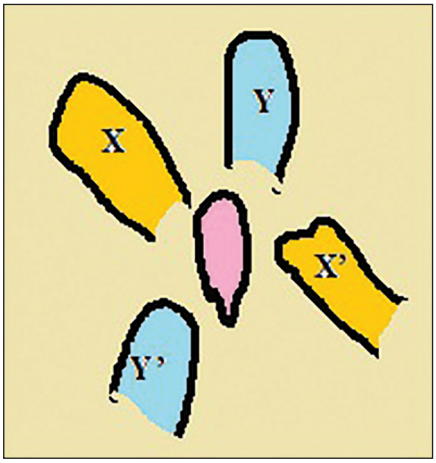

Figure 1: Diagrammatic representation of four flap hymenoplasty (redrawn from Saraiya)

ability to last long? Is it the size of the introitus at the end of repair or first intercourse? Or is it the ability of the repair to bleed at first intercourse?

The author prefers the surgery under spinal anaesthesia for better muscle relaxation, but in our experience, many a time these patients attend the clinics looking for a quick fix without admission, these being super-secretive procedures and follow-up is difficult. Another question that needs to be answered is who is qualified to perform this procedure, it not being part of the medical curriculum.

We conclude by saying that it is time to answer these unanswered questions with evidence-based approach and to make the procedure more scientific.

Financial support and sponsorship
Nil.

Conflicts of interest
There are no conflicts of interest.

S. S. Shirol, Mahesh Prabhu[1], Jaideep Ratkal[2]

Departments of Plastic Surgery, [1]Sampige Superspecialty Clinic Hubli and KIMS, KLE University, Belgaum, [2]Department of Urology, KIMS, Hubli, Karnataka, India

Address for correspondence:
Dr. S. S. Shirol, Sampige Super Speciality Clinic, Club Road, Hubli - 580 028, Karnataka, India.
E-mail: ssshirol@yahoo.co.uk

REFERENCES

1. Saraiya HA. Surgical revirgination: Four vaginal mucosal flaps for reconstruction of a hymen. Indian J Plast Surg 2015;48:192-5.
2. Prakash V. Hymenoplasty — How to do. Indian J Surg 2009;71:221-3.
3. Ou MC, Lin CC, Pang CC, Ou D. A cerclage method for hymenoplasty. Taiwan J Obstet Gynecol 2008;47:355-6.

This is an open access article distributed under the terms of the Creative Commons Attribution-NonCommercial-ShareAlike 3.0 License, which allows others to remix, tweak, and build upon the work non-commercially, as long as the author is credited and the new creations are licensed under the identical terms.

Access this article online

Quick Response Code:	Website: www.ijps.org
	DOI: 10.4103/0970-0358.173142

How to cite this article: Shirol SS, Prabhu M, Ratkal J. Surgical revirgination: Four vaginal mucosal flaps for reconstruction of a hymen. Indian J Plast Surg 2015;48:324-5.