Published online: 2019-08-26

Case Report

# Pentafid tongue: A new entity

**Manesh Senan, Varun Menon P**

Departments of Plastic Surgery and Oral and Maxillofacial surgery, Kerala Institute of Medical Sciences (KIMS), Trivandrum, Kerala, India

**Address for correspondence:** Dr. Manesh Senan, Department of Plastic Surgery, Kerala Institute of Medical Sciences (KIMS), Trivandrum - 695 029, Kerala, India. E-mail: maneshsenan@yahoo.com

## ABSTRACT

Tongue plays a pivotal role in both physiological and functional life of human beings. Structural and developmental abnormalities of the tongue in various forms have been reported in isolation or in combination with various syndromes. Though cases of bifid tongues have been mentioned in literature, no reports of pentafid tongue have been reported till date. Here we describe a unique case of congenital pentafid tongue along with bilateral polydactyly and its surgical management.

## KEY WORDS

Pentafid tongue; polydactyly; surgical technique; tongue shaping

## INTRODUCTION

Developmental and structural abnormalities of tongue are common features, and numerous cases have been reported in literature till date as are the incidents of hamartomas and teratomas of tongue etc. Cases of congenital bifid tongue in association with various other orofacial and skeletal abnormalities have been reported, many of which have been linked to various syndromes. A tongue with a pentafid structure has never been discussed in isolation or with oral-facial-digital syndrome. Here we describe a unique case of congenital pentafid tongue along with bilateral polydactyly and its surgical management.

## CASE REPORT

A 3-year-old male had presented with difficulty in speech with abnormal tongue and extra fingers on both hand. On examination, there were five distinct muscular segments on the tip and lateral surface of the tongue [Figure 1]. His mental and motor developments, as well as audiological evaluation, were normal. The child had presented with bilateral polydactyly [Figure 2];which was evaluated both clinically and radiologically [Figure 3]. No other intraoral and skeletal deformities were evident. There was no relevant medical and family history, and his haematological parameters were within normal limits.

The parents were very particular about restoring back both aesthetic and functional aspects of the child's tongue and hands. Surgical correction of the tongue and hand deformity was planned under general anaesthesia.

| Access this article online | |
|---|---|
| Quick Response Code: | Website: www.ijps.org |
| | DOI: 10.4103/0970-0358.173130 |

This is an open access article distributed under the terms of the Creative Commons Attribution-NonCommercial-ShareAlike 3.0 License, which allows others to remix, tweak, and build upon the work non-commercially, as long as the author is credited and the new creations are licensed under the identical terms.

**For reprints contact:** reprints@medknow.com

**How to cite this article**: Senan M, Menon VP. Pentafid tongue: A new entity. Indian J Plast Surg 2015;48:301-4.

### Surgical technique

Under general anaesthesia, the extra digits of the hands were removed along with bone, cartilage and the underlying growth capsule. For the tongue deformity [Figure 1], the tongue shaping and repair was done by 30-degree angulated V-shaped excision along both the dorsal and ventral sides of the cleft edges of the tongue [Figure 4]. Submucosal dissection was carried out until the underlying muscle projections were adequately exposed [Figure 5]. Muscular layer from both halves were approximated and repaired [Figure 6] with 3.0 Monocryl. The overlying mucosa was adequately trimmed and primary closure was done [Figure 7]. Initially, the medial segment of the tongue defect was aesthetically reconstructed, followed by the lateral segments of the tongue, so as to get the smooth shape of the tongue.

Post-surgery healing was uneventful [Figures 8 and 9]. Patient's speech was better with improved articulation. Aesthetic appearance of the tongue was better and the hand movements were intact with improved cosmesis as well.

## DISCUSSION

Developmental anomalies arising from the lower half of the first branchial arch, such as the complete or

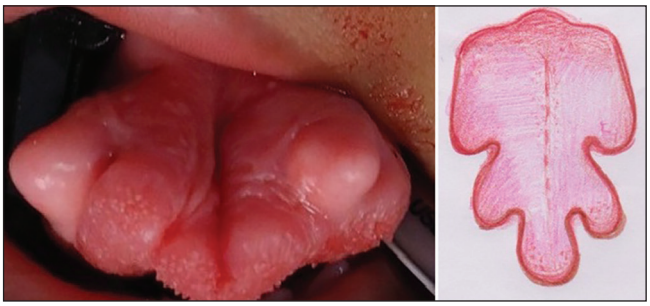

**Figure 1:** Clinical picture of pentafid tongue

**Figure 2:** Clinical picture of bilateral polydactyly

**Figure 3:** Hand-wrist radiograph showing bilateral polydactyly

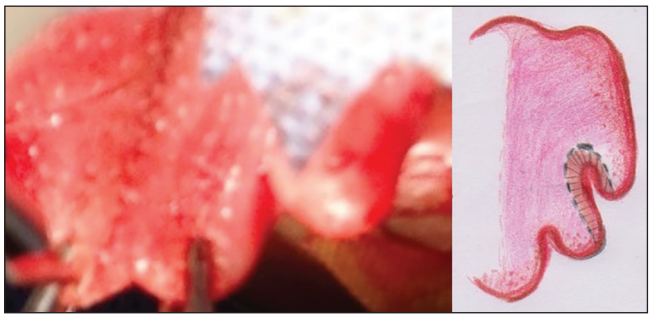

**Figure 4:** V-shaped excision

**Figure 5:** Muscle projection after mucosa undermining

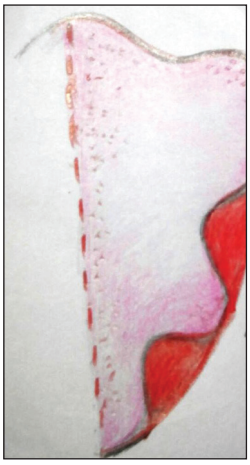

**Figure 6:** After-muscle repair

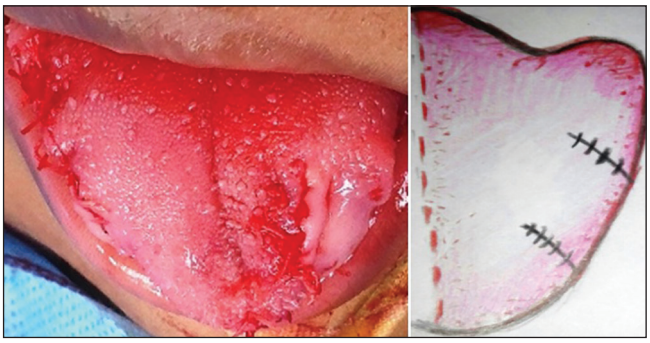

**Figure 7:** After-mucosal trimming and closure

**Figure 8:** Postoperative picture of repaired pentafid tongue

**Figure 9:** Postoperative picture of repaired hand

incomplete cleft of the lower lip, mandible and tongue are rare, as compared to cleft lip or cleft palate derived from the upper half of the first branchial arch.[1]

Developmental malformations seen on the tongue may be either major or minor, single or multiple. These rare anomalies are classified as:

1. Aglossia,
2. Microglossia,
3. Hemiatrophy,
4. Hemihypertrophy,
5. Macroglossia,
6. Long tongue,
7. Ankyloglossia,
8. Cleft or bifid tongue and
9. Hamartomatous lesions.[2]

The development of the tongue begins during the fourth week of intrauterine life, the first pharyngeal arch forms the movable anterior body of the tongue. The second and third arches form the posterior, immovable base of the tongue.[3] Tissues of the tongue have three parts, the central tuberculum impar and the two lateral lingual swellings. The lateral parts rapidly enlarge and merge, overgrowing the central tubercle. Gradually, the three parts of the anterior tongue merge to form a unified structure.[2,3] The tongue is a good example of muscle cell migration because it originates in the occipital myotomes and migrates anteriorly into the floor of the mouth.[3]

The failure of fusion of the first pair of branchial arches or a failure of mesodermal penetration[4] into the midline of the mandibular part of the first branchial arch, have been proposed as the etiology for complete or incomplete cleft of the lower lip, mandible and tongue.[1]

When any of the above phenomenon is disturbed, it gives rise to isolated cleft tongue or bifid tongue. A similar explanation may be put forth to explain the pentafid tongue that was seen in our case, that is, any process affecting this mesodermal penetration and mesenchymal fusion during the tongue development accounts for this malformation.

They may occur as an isolated entity or as a part of clinical syndromes.[5] Syndromic conditions include the Opitz G/BBB syndrome, oral-facial-digital syndrome type I, Klippel-Feil anomaly and Larsen syndrome.[6] Oral-facial-digital syndrome types I, II, IV and VIhave been associated with tongue clefts, median lip with or without mandibular clefts and digital variations[5,7,8].

Instances of cleft palate, mandibular cleft, midline palatomandibular bony fusion and cervical vertebrae have been associated with tongue clefts as well.[9] Rare cases of bifid tongue have also been reported among infants of the diabetic mother.[10] In our literature search, we never came across any such reported cases of either a pentafid tongue or a pentafid tongue associated with polydactyly.

## CONCLUSION

Diagnosing this clinical entity and its treatment options frequently create a dilemma in the minds of clinicians. Sometimes we need to broaden our mind to think beyond syndromes that have already been illustrated in the literature for the right diagnosis and for the appropriate management.

### Financial support and sponsorship

Nil.

### Conflicts of interest

There are no conflicts of interest.

## REFERENCES

1. Almeida LE, Ulbrich L, Togni F. Mandible cleft: Report of a case and review of the literature. J Oral Maxillofac Surg 2002;60:681-4.
2. Emmanouil-Nikoloussi E, Kerameos-Foroglou C. Congenital syndromes connected with tongue malformations. Bull Assoc Anat (Nancy) 1992;76:67-72.
3. Avery JK. Essentials of Oral Histology and Embryology: A Clinical Approach. 3rd ed. St. Louis: Mosby; 2000. p. 29-30.
4. Stones HH. Oral and Dental Diseases. 4th ed. Edinburgh: Churchill Livingstone; 1962. p. 12.
5. Mattei JF, Aymé S. Syndrome of polydactyly, cleft lip, lingual hamartomas, renal hypoplasia, hearing loss, and psychomotor retardation: Variant of the Mohr syndrome or a new syndrome? J Med Genet 1983;20:433-5.
6. Kulkarni U, Kulkarni DU. Bifid tongue — A case report. NJCA 2013;2:97-8.
7. Martinot VL, Manouvrier S, Anastassov Y, Ribiere J, Pellerin PN. Orodigitofacial syndromes type I and II: Clinical and surgical studies. Cleft Palate Craniofac J 1994;31:401-8.
8. Wey PD, Neidich JA, Hoffmann LA, LaTrenta GS. Midline defects of the orofaciodigital syndrome type VI (Váradi syndrome). Cleft Palate Craniofac J 1994;31:397-400.
9. Rao S, Oak S, Wagh M, Kulkarni B. Congenital midline palatomandibular bony fusion with a mandibular cleft and a bifid tongue. Br J Plast Surg1997;50:139-41.
10. James AW, Culver K, Hall B, Golabi M. Bifid tongue: A rare feature associated with infants of diabetic mother syndrome. Am J Med Genet 2007;143A:2035-9.