Published online: 2019-08-26

Original Article

Hypothenar island flap: A safe and excellent choice for little finger defects

Mehmet Tapan, Murat İğde, Ali Rıza Yıldırım, Yağmur Yaprak Balı[1], Sedat Yılancı[2], Ramazan Erkin Ünlü

Department of Plastic, Reconstructive and Aesthetic Surgery, Ankara Numune Training and Research Hospital, Ankara, [1]Department of Plastic, Reconstructive and Aesthetic Surgery, Artvin Public Hospital, Artvin, [2]Department of Plastic, Reconstructive and Aesthetic Surgery, Yozgat Public Hospital, Yozgat, Turkey

Address for correspondence: Dr. Mehmet Tapan, Department of Plastic, Reconstructive and Aesthetic Surgery, Ankara Numune Training and Research Hospital, Talatpasa Boulevard Number: 5, Altındag/Ankara, Turkey. E-mail: drmtapan@gmail.com

ABSTRACT

Soft-tissue defects of the little finger are challenging especially when bone, tendon or vascular pedicle is exposed because of trauma. The hypothenar island flap is easy to harvest and has a good colour and texture match to the little finger pulp. We present nine clinical cases of soft tissue defects of the little finger covered using the reversed hypothenar fasciocutaneous island flap. This article intends to highlight the ease of elevation and good clinical results of the hypothenar flap which is rarely used.

KEY WORDS

Hypothenar island flap; island flap; soft-tissue defects of the little finger

INTRODUCTION

Soft-tissue defects of the little finger are a challenging problem. The reconstructive needs are to provide stable coverage and sensibility.[1,2] A functional fifth metacarpus and functional ulnar fingers are important for the locking grip and supporting grip.[3]

The reverse digital artery island flap is a safe and reliable procedure with a high survival rate.[4] The hypothenar area is used as a vascularized flap donor site very infrequently in the clinical practice.[2,5,6] The hypothenar area has significant sensory potential for finger reconstruction.[7]

Access this article online	
Quick Response Code:	Website: www.ijps.org
	DOI: 10.4103/0970-0358.173127

The aim of this study was to present our experience using the reverse hypothenar island flap for finger reconstruction and to evaluate clinical benefits of this safe and easy surgical technique.

Anatomy and surgical technique

Hypothenar skin is vascularized by different types of perforators that come out from the ulnar palmar digital artery of the little finger that emerges from the superficial palmar arterial arch. In the most distal region of this area,

This is an open access article distributed under the terms of the Creative Commons Attribution-NonCommercial-ShareAlike 3.0 License, which allows others to remix, tweak, and build upon the work non-commercially, as long as the author is credited and the new creations are licensed under the identical terms.

For reprints contact: reprints@medknow.com

How to cite this article: Tapan M, Igde M, Yildirim AR, Bali YY, Yilanci S, Unlu RE. Hypothenar island flap: A safe and excellent choice for little finger defects. Indian J Plast Surg 2015;48:288-92.

fasciocutaneous perforators are the dominant vascular supply, but in the proximal segment, musculocutaneous perforators are more dominant.[2,8] The number of perforators described in anatomical studies varies from 3 to 6.[1] A constant sizeable perforator was identified within 0.7 cm from the proximal margin of the A1 pulley.[9] Neural supply of this area is from the dorsal or palmar cutaneous branches of the ulnar nerve.[2]

The average distances from the superficial palmar arch and deep palmar arch to the carpometacarpal joint of the ring finger were 32.2 ± 6.33 mm and 18.3 ± 4.64 mm, respectively.[10] Ulnar digital artery of the little finger is a direct branch of the superficial arch. A finger has three transverse palmar arches and the proximal transverse palmar arch is located at the level of the neck of the proximal phalanx.[11]

Flap dissection is performed in the subfascial plane of medial side of the abductor digiti minimi muscle. Multiple perforating branches running transversely and arising from the ulnar palmar digital artery are identified. After ligating the ulnar palmar digital artery and concomitant veins at the proximal side of the flap, they are retrogradely dissected at the distal point of rotation which supplies reverse flow of the flap. The distal point of rotation is the neck of proximal phalanx, which is related to the proximal transverse palmar arch between the ulnar and radial palmar arteries. A perivascular cuff of tissue is preserved that aids in venous drainage [Figure 1].

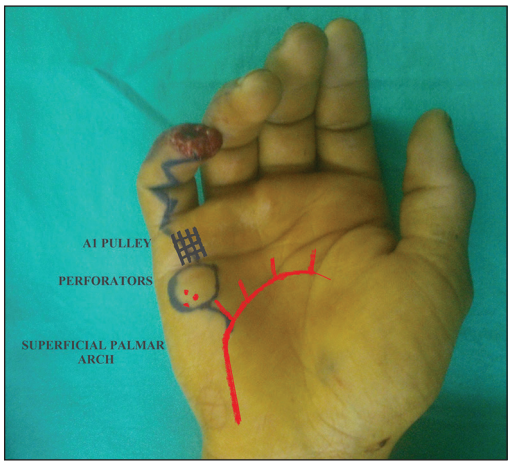

Figure 1: The average distance from the superficial pal mar arch to the carpometacarpal joint of the ring finger was 32.2 mm ± 6.33 mm.[10] Ulnar artery of the little finger is a direct branch of the superficial arch.[11] The number of perforators described in anatomical studies varies from 3 to 6.[1] A constant sizeable perforator was identified within 0.7 cm from the proximal margin of the A1 pulley.[9] In the most distal region of this area, fasciocutaneous perforators are the dominant vascular supply.[2,8]

The donor site is closed primarily with or without simultaneous multiple Z-plasties.[12] We consider that is unsafe to pass the pedicle under a tunnel, so we recommend a Brunner incision from the donor site to the defect [Figure 2].

MATERIALS AND METHODS

Since 2013, nine patients with soft-tissue defects and amputation injuries of the little fingerwere treated using a vascularized flap from the hypothenar area [Table 1].

Because the flap gains its vascular supply from the opposite digital artery by retrograde perfusion, preoperative assessment of the integrity of the digital arteries was performed by the Allen test.

There were one female and eight male patients and their ages at the time of surgery averaged 28 years. The size of the soft-tissue defects ranged from 12 mm × 12 mm to 20 mm × 13 mm. The soft-tissue defects were at the level of distal inter-phalangeal joint crease or distal to

Table 1: Patient summary

Case sex (M/F)*	Age (Years)	Size of the defect (mm)	Size of the flap (mm)
1M	25	18×15	20×15
2M	22	17×12	20×15
3M	32	12×12	16×15
4M	23	14×10	15×12
5M	29	20×13	20×15
6M	28	18×8	20×10
7M	43	13×9	15×10
8M	32	17×14	18×16
9F	20	20×10	20×10

*Male/Female

Figure 2: The donor site is closed primarily. Brunner incisions and Littler diamond incisions can be used together

it. The size of the flaps ranged from 15 mm × 10 mm to 20 mm × 15 mm.

None of the patients had any injury of contralateral little finger. For patient satisfaction, we asked all the patients two questions (Question 1 and 2) after 6 months postoperatively [Table 2]. We assessed moving two-point discrimination (2 PD) and cold intolerance of all the patients.

RESULTS

The follow-up periods ranged from 10 months to 25 months, with an average of 14 months. All the patients stayed at hospital only for 1 day. All the flaps survived without complications, neither arterial nor venous insufficiency.

All patients expressed satisfaction with the flap procedure and the aesthetic results [Figure 3]. Seven patients answered to Question 1 saying that the result was excellent. Two patients answered to Question 1 saying that the result was good.

Five of the patients answered to Question 2 saying that the result was excellent. Two patients answered to Question 2 saying that the result was good and the other two patients answered to Question 2 saying that the result was fair. Four patients who did not answer to Question 2 said that the result was excellent; however, they showed the longitudinal scar at the donor site and in one of them secondary multiple Z-plasties was required at the follow-up after 6 months because of limited active extension of proximal interphalangeal (PIP) joint of little finger which has 20° loss of active extension. Eight of nine patients had normal active extension of PIP joint at the sixth month, postoperatively.

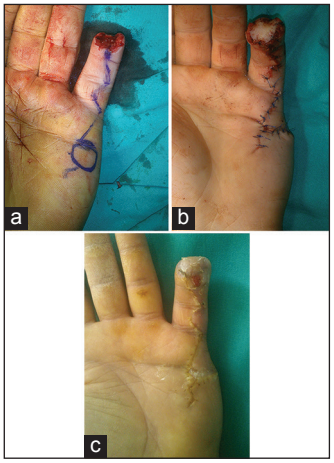

Figure 3: (a) Preoperative view, (b) immediate postoperative view and (c) postoperative view, after 3 months

None of the flaps was neurotized. Flap sensibility showed 7 mm of average 2 PD after 3 months postoperatively. We used the modified American Society for Surgery of the Hand guidelines to stratify the 2 PD measurements (excellent, ≤6 mm; good, 6-10 mm; fair, 11-15 mm; poor, ≥15 mm).[13] We assessed the cold intolerance of all the patients using the self-administered Cold Intolerance Severity Score Questionnaire that was rated into mild, moderate, severe and extreme (0-25, 26-50, 51-75 and 76-100)[14] [Table 3].

DISCUSSION

Digital soft-tissue reconstruction has been developed using the knowledge of the small digital arteries and the different angiosomes located on specific zones of the hand.[15] The reverse hypothenar flap anatomy has been described earlier, including the number of perforants found and the maximal size of the skin island permitted.[1,2,8,9] Primary closure of donor site is an advantage compared to many other homodigital flaps. The Allen test is necessary because the ulnar palmar digital vessel is divided at the proximal end and vascularity of the finger entirely depends on the integrity of radial digital vessel. Pan-Deng Hao *et al*. recommended that

Table 2: Questionnaire of patient satisfaction*

Question 1:	Comparing with the intact other little finger, how is the result, aesthetically? Poor, fair, good and excellent
Question 2:	Comparing with the intact other little finger, how is the result, functionally?** Poor, fair, good and excellent

*This questionnaire is appropriate for those who have no injury to contralateral finger; **In terms of functionally, we asked the patients to do full active extension and flexion of proximal and distal interphalangeal joints

Table 3: Postoperative assessment of the injured finger

Case	Age (Years)	2 PD (mm)	Cold intolerance
1	25	6	0
2	22	7	0
3	32	5	0
4	23	7	0
5	29	8	10
6	28	8	0
7	43	6	0
8	32	7	0
9	20	9	10

using cutaneous perforator flaps is a better option than sacrificing a digital artery.[16] But ulnar palmar perforator flap cannot reach the distal level of the little finger.

Hypothenar island flap which is easy to harvest technically is a safe flap. The procedure is easy when flap dissection is performed in the subfascial plane over the abductor digiti minimi muscle. Omokawa *et al*. recommended that subfascial dissection of the flap should be performed from the dorsal side of the hand.[2] On the contrary, in our study, flap designs did not include the dorsal side of the hand. Donor site stayed in the palmar side.

Wolff *et al*. stated that venous congestion is a disadvantage of hypothenar island flap.[1] Hao *et al*. reported that all the flaps survived without complications.[16] In our study, all the flaps survived without arterial and venous insufficiency. We recommend protecting periarterial adipofascial tissue of digital artery as much as possible. Adipofascial pedicle of the flap seemed bulky at first gaze but patients are satisfied with the result after a few months.

All the patients are satisfied because they do not have a short finger. Like postburn sequel of the fifth finger, nonfunctioning fifth finger is also problematic.[17] Two ulnar fingers are designated for locking grip and supporting grip.[3] This flap provides all reconstructive goals including stable coverage, with colour, texture, sensibility and volume similar to the normal local tissue. Although normal sensation is not completely restored, we believe that this flap provides enough sensation for the little finger without neurotization. However, in this study, the double sensibility phenomenon which is a constant problem of Littler's flap was not seen.[18]

The only absolute contraindication for using this flap is severe injury to the little finger with vascular compromise of the digits. Other relative contraindications are elderly patients or those suffering from vascular diseases or long-standing diabetes.[19] The success of flap survival of our study can be related to the age group of the patients. None of the patients has vascular diseases or diabetes.

Potential disadvantages of the hypothenar flap are contracture and limited extension of little finger because of continuous incisions of palmar side of the hand. Scar massage and range of motion exercises are effective at the postoperative period. Patient compliance with rehabilitation is an important part of the treatment. We recommend Brunner incisions or Littler diamond incisions which we used in seven of them. We preferred slight lazy 'S' incision only in two of the nine patients at the proximal metacarpophalangeal joint crease. One of them was operated for multiple Z-plasties because of limited active extension of the proximal interphalangeal (PIP) joint. Loss of active extension of the PIP joint was measured 20° at the sixth month of the hypothenar island flap operation although scar massage and range of motion exercises were advised. After multiple Z-plasties, the PIP joint gained 15° active extension. Both patient compliance with rehabilitation and choice of appropriate incision technique can overcome the potential disadvantage of this flap which may require secondary procedure of multiple Z-plasties.

Financial support and sponsorship

Nil.

Conflicts of interest

There are no conflicts of interest.

REFERENCES

1. Wolff GA, Patrón AS, Herrera O, Posso C. Reconstruction of volar digital defects: Clinical experience with the hipothenar flap. Tech Hand Up Extrem Surg 2010;14:191-5.
2. Omokawa S, Yajima H, Inada Y, Fukui A, Tamai S. A reverse hypothenar flap for finger reconstruction. Plast Reconstr Surg 2000;106:828-33.
3. Bendz P. The functional significance of the fifth metacarpus and hypothenar in two useful grips of the hand. Am J Phys Med Rehabil 1993;72:210-3.
4. Han SK, Lee BI, Kim WK. The reverse digital artery island flap: Clinical experience in 120 fingers. Plast Reconstr Surg 1998;101:1006-13.
5. Chase RA, Hentz VR, Apfelberg D. A dynamicmyocutaneous flap for hand reconstruction. J Hand Surg Am 1980;5:594-9.
6. Iwasawa M, Ohtsuka Y, Kushima H, Kiyono M. Arterialized venous flaps from the thenar and hypothenarregions for repairing finger pulp tissuelosses. Plast Reconstr Surg 1997;99:1765-70.
7. Gellis M, Pool R. Two-point discrimination distancein the normal hand and forearm: Applicationtovarious methods of fingertip reconstruction. Plast Reconstr Surg 1977;59:57-63.
8. Kojima T, Endo T, Fukumoto K. Reverse vascular pedicle hypothenar island flap. Handchir Mikrochir Plast Chir 1990;22:137-44.
9. Toia F, Marchese M, Boniforti B, Tos P, Delcroix L. The little finger ulnar palmar digital artery peforator flap: Anatomical basis. Surg Radiol Anat 2013;35:737-40.
10. McLean KM, Sacks JM, Kuo YR, Wollstein R, Rubin JP, Lee WP. Anatomical landmarksto the superficial and deep palmar arches. Plast Reconstr Surg 2008;121:181-5.

11. Strauch B, de Moura W. Arterial system of the fingers. J Hand Surg Am 1990;15:148-54.
12. Hwang K, Han JY, Chung IH. Hypothenar flap based on a cutaneous perforator branch of the ulnar artery: An anatomic study. J Reconstr Microsurg 2005;21:297-301.
13. Dellon AL, Kallman CH. Evaluation of functional sensation in the hand. J Hand Surg Am 1983;8:865-70.
14. Irwin MS, Gilbert SE, Terenghi G, Smith RW, Green CJ. Cold intolerance following peripheral nerve injury, Natural history and factors predicting severity of symptoms. J Hand Surg Br 1997;22:308-16.
15. Edwards EA. Organization of the small arteries of the hand and digits. Am J Surg 1960;99:837-46.
16. Hao PD, Zhuang YH, Zheng HP, Yang XD, Lin J, Zhang CL, *et al*. Theulnarpalmarperforatorflap: Anatomical study and clinical application. J Plast Reconstr Aesthet Surg 2014;67:600-6.
17. Groenevelt F. Some aspects of the burned little finger. Br J Plast Surg 1986;39:225-8.
18. Xarchas KC, Tilkeridis KE, PElekas SI, Kazakos KJ, Kakagia DD, Verettas DA. Littler's flap revisited: An anatomic study, literature review, and clinical experience in the reconstruction of large thumb-pulp defects. Med Sci Monit 2008;14:CR568-73.
19. Basu I, Markeson D, Evgeniou E, Iyer S. Revers digital artery flap from radial and ulnar borders of palm. Tech Hand Up Extrem Surg 2012;16:110-3.