

Original Article

Pedicle streaking: A novel and simple aid in pedicle positioning in free tissue transfer

Aditya Aggarwal, Hardeep Singh, Sanjay Mahendru, Vimalendu Brajesh, Sukhdeep Singh, Ashish Khare, Umang Kothari, Rakesh Kumar Khazanchi

Department of Plastic, Reconstructive and Aesthetic Surgery, Medanta - The Medicity, Gurgaon, Haryana, India

Address for correspondence: Dr. Hardeep Singh, Department of Plastic, Reconstructive and Aesthetic Surgery, Medanta - The Medicity, Sector 38, Gurgaon (NCR) - 122 001, Haryana, India. E-mail: drhardeepaulakh@gmail.com

ABSTRACT

Introduction: The pedicle positioning in free tissue transfer is critical to its success. Long thin pedicles are especially prone to this complication where even a slight twist in the perforator can result in flap loss. Pedicles passing through the long tunnels are similarly at risk. Streaking the pedicle with methylene blue is a simple and safe method which increases the safety of free tissue transfer. **Materials and Methods:** Once the flap is islanded on the pedicle and the vascularity of the flap is confirmed, the pedicle is streaked with methylene blue dye at a distance of 6-7 mm. The streaking starts from the origin of the vessels and continued distally on to the under surface of flap to mark the complete course of the pedicle in alignment. The presence of streaking in some parts and not in rest indicates twist in the pedicle. **Observation and Results:** Four hundred and sixty five free flaps have been done at our centre in the last 5 years. The overall success rate of free flaps is 95.3% (22 free flap failures). There has not been a single case of pedicle twist leading to flap congestion and failure. **Conclusion:** This simple and novel method is very reliable for pedicle positioning avoiding any twist necessary for successful free tissue transfer.

KEY WORDS

Free flaps; pedicle; perforator

INTRODUCTION

The art and science of microsurgery has progressed steadily over the past 30 years with advances in technical skills, equipment and discovery of more reliable flaps.

The common causes of flap failure are anastomotic failures, pedicle positioning and hypercoagulable states.^[1]

The pedicle positioning in free tissue transfer is critical to its success. Long thin pedicles are especially prone to this complication where even a slight twist in the perforator can result in flap loss. Pedicles passing through the long tunnels are similarly at risk. Streaking the pedicle

This is an open access article distributed under the terms of the Creative Commons Attribution-NonCommercial-ShareAlike 3.0 License, which allows others to remix, tweak, and build upon the work non-commercially, as long as the author is credited and the new creations are licensed under the identical terms.

For reprints contact: reprints@medknow.com

How to cite this article: Aggarwal A, Singh H, Mahendru S, Brajesh V, Singh S, Khare A, Kothari U, Khazanchi RK. Pedicle streaking: A novel and simple aid in pedicle positioning in free tissue transfer. Indian J Plast Surg 2015;48:274-7.

Access this article online

Quick Response Code:



Website:

www.ijps.org

DOI:

10.4103/0970-0358.173124

with methylene blue is a simple and safe method which increases the safety of free tissue transfer.

With frequent use of microsurgical flaps, the technical problems have reduced but the problems related to pedicle positioning (twists/kinking) still persist. We present here a novel method of avoiding the twist in the pedicle by streaking it with methylene blue.

Procedure details

Once the flap is islanded on the pedicle and the vascularity of the flap is confirmed, the pedicle is streaked with methylene blue dye at a distance of 6-7 mm [Figure 1]. The streaking starts from the origin of the vessels and continued distally on to the under surface of flap to mark the complete course of the pedicle in alignment [Figure 2].

The marking is dabbed with dry gauze to avoid excessive staining on the pedicle. The flap is then divided from the

donor area. Depending on the orientation of the flap at the time of inset the streaking should be either visible or totally not seen all along the pedicle. The presence of streaking in some parts and not in rest indicates twist in the pedicle [Figures 3 and 4].

Even when tunnelling the pedicle the above-mentioned points should be taken care of. We prefer to tunnel the pedicle by passing a haemostat through it and holding the adventitia over the pedicle with it [Figure 5]. The haemostat is gently pulled out along with the pedicle keeping a continuous watch on streaking. The presence of the streaking on parts of the pedicle out of the tunnel (both proximally and distally) confirms the correct orientation [Figure 6]. In the flow through flaps, it is wise to streak the flow through segment of the pedicle and the perforator both to avoid any twist in either of them [Figure 7].

The presence of two or more perforators in the flap reduces the chances of twist as it becomes apparent and easy to identify the twist [Figure 8] because of the crossover of the perforators on each other [Figure 9].

When the need arises for a double paddle flap (as for mucosal lining and skin cover in oral cancer resection

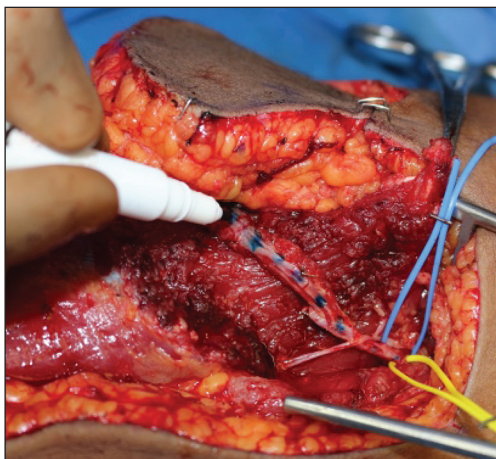


Figure 1: Streaking at a distance of 6-7 mm with methylene blue

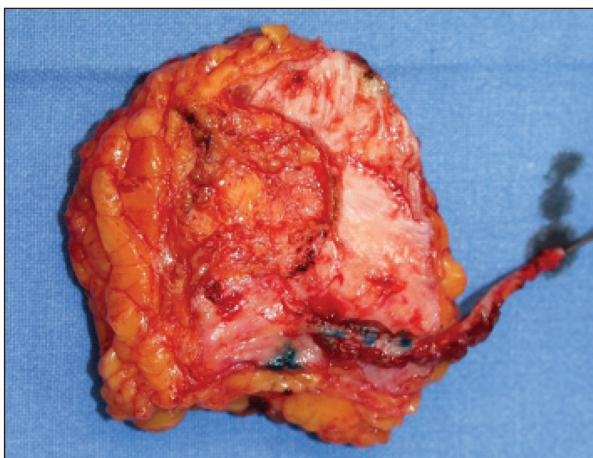

Figure 3: Inability to see the streaking throughout indicates twist

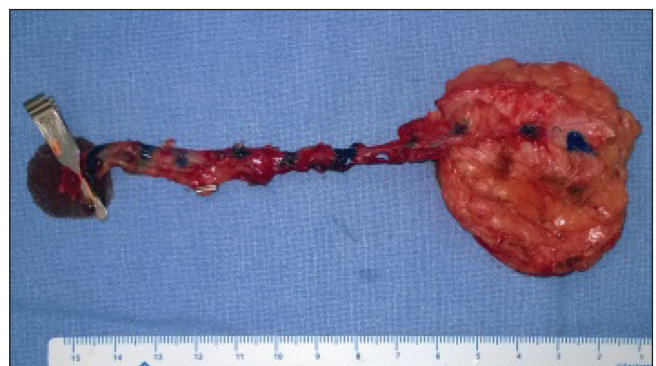


Figure 2: Streaking from the origin of vessels till the under surface of the flap

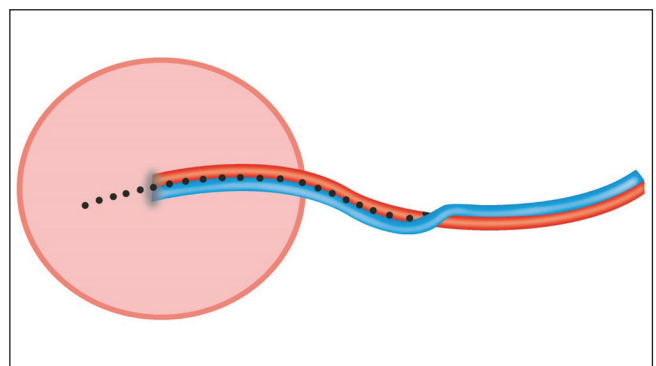


Figure 4: Line diagram to identify the twist by streaking

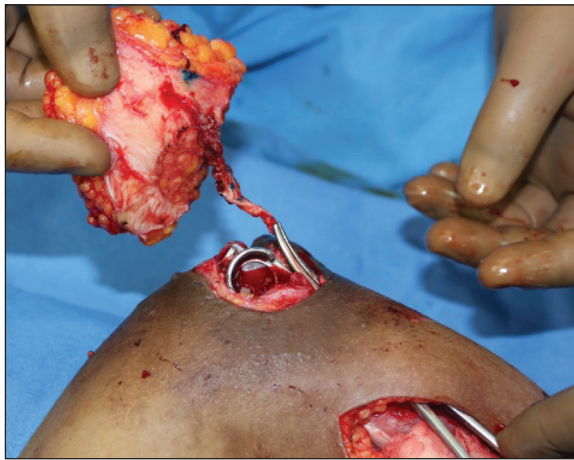

Figure 5: Tunnelling of the pedicle with hemostat

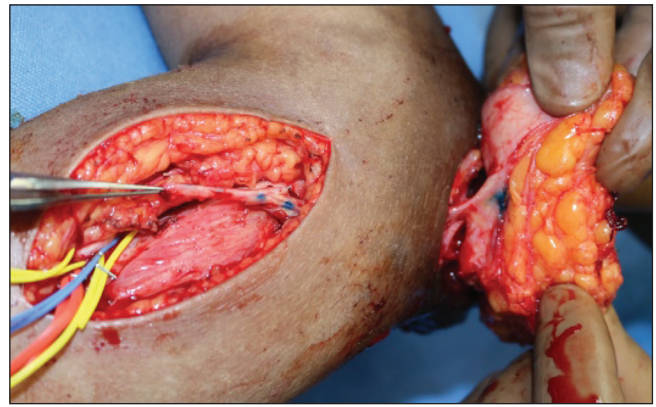


Figure 6: Presence of streaking on both parts indicate alignment

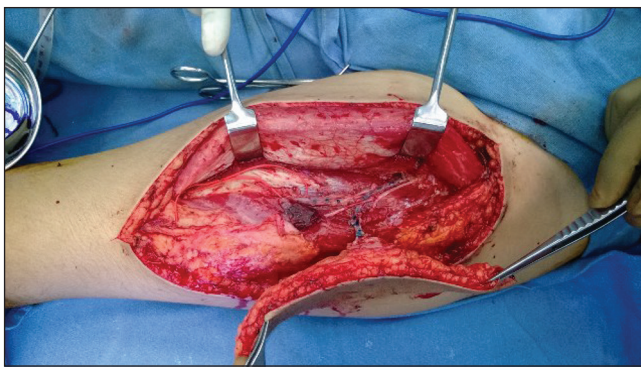


Figure 7: Streaking of flow through segment and perforator in flow through flap

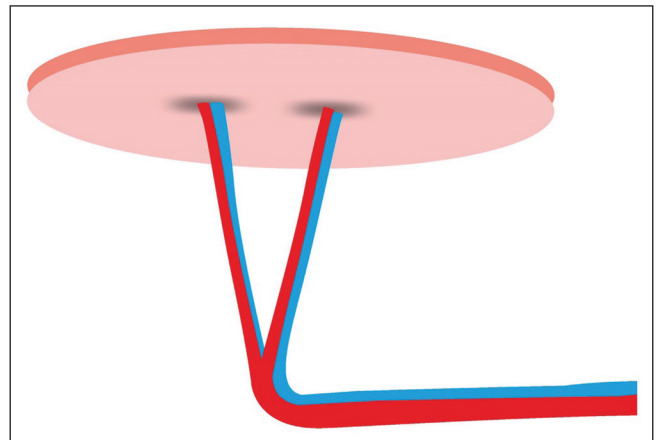


Figure 8: A flap containing two perforators

defects) with separate perforators for each skin paddle but connected to same pedicle, streaking is a great asset.

We are using this method of streaking the pedicle in all free tissue transfers since the last 5 years. During this period, 465 free flaps have been done at our centre. The overall success rate of free flaps is 95.3% (22 free flap failures). There has not been a single case of pedicle twist leading to flap congestion and failure.

DISCUSSION

Microsurgical free tissue transfer has vastly expanded the reconstructive surgeon's repertoire and enabled us to think of a variety of reconstructive possibilities, which would have been impossible to conceive in pre-microsurgical era.^[2]

Microsurgery has modified many traditional methods of reconstruction — A change from the 'Reconstruction Ladder' to a 'Reconstructive Elevator'.^[3,4]

There are three steps where technical problems can arise during free tissue transfer. The first can happen during

harvesting of flaps, secondly during the inseting of flaps and placing the pedicle in correct alignment and finally during microvascular anastomosis. As learning curves go, high volume centres minimize the problems related to flap harvesting and anastomosis. Yet the problems related to pedicle twists and kinking still exist.

The use of perforator flaps has been increasing in reconstruction as they can be tailored to different shapes and size. The pedicle of these flaps is very thin and hence more prone for twisting.^[5]

Moreover, the position of the flap may be changed by the surgeon to achieve the best result, just like painters erase and redraw some parts of the pictures. The pedicle of the free flap can twist during such intraoperative manoeuvres.^[6]

Free flap success rates have increased from 94% to 98.8%.^[1] Williams *et al.* identified kinking as the most common cause of occlusion. Virchow's triad states three conditions for thrombosis-hypercoagulability, stasis

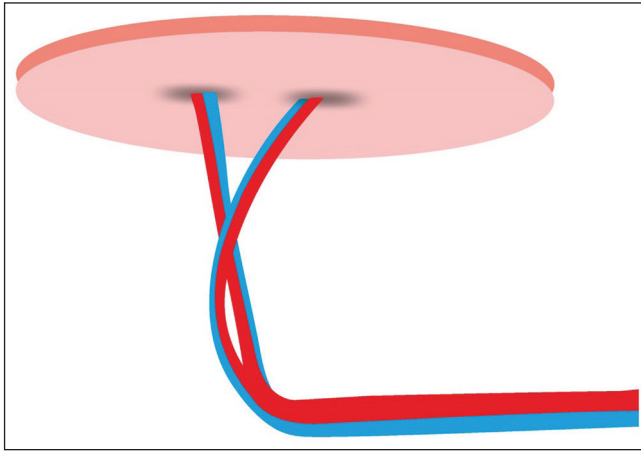


Figure 9: Crossing over of perforators indicates twist

and endothelial damage. A twist in the pedicle causes mechanical obstruction of flow creating stasis^[1] and thus predisposing to thrombosis.

For free flaps specially, Khouri outlined factors suspected of leading to thrombosis as being kinks or twists, tight closure/oedema, hematoma and spasm/inadequate flow.^[7]

With the length of the pedicle the changes of twist also increases. To add to the problem many times the pedicle needs to be tunneled under the bone/soft tissue to reach the site of anastomosis. Passage of pedicle through this tunnel blindly increases the chances of twist.^[8]

Prabha *et al.* have used pedicle wrapped in the glove for transfer in the tunnel as it is passed from inside oral cavity and artery clamp guides it out by holding onto the glove.^[9]

Moschella *et al.* use endotracheal tube for tunnelling the pedicle for maxillary defects.^[10]

Theodorakopoulou *et al.* have reported a case of use of venous coupler to manage a twist in the vein for end to side anastomosis avoiding revision of anastomosis.^[11]

We present a simple and novel method of avoiding twist, which is confirmatory of pedicle alignment whether it is laid through open wound or is tunneled.

CONCLUSION

This simple and novel method is very reliable for pedicle positioning avoiding any twist necessary for successful free tissue transfer.

Financial support and sponsorship

Nil.

Conflicts of interest

There are no conflicts of interest.

REFERENCES

1. Williams JG, French RJ, Lalonde DH. Why do free flap vessels thrombose? Lessons learned from implantable Doppler monitoring. *Can J Plast Surg* 2004;12:23-6.
2. Koul AR, Patil RK, Nahar S. Unfavourable results in free tissue transfer. *Indian J Plast Surg* 2013;46:247-55.
3. Gottlieb LJ, Krieger LM. From the reconstructive ladder to the reconstructive elevator. *Plast Reconstr Surg* 1994;93:1503-4.
4. Bennett N, Choudhary S. Why climb a ladder when you can take the elevator? *Plast Reconstr Surg* 2000;105:2266.
5. Lee HJ, Lim SY, Pyon JK, Bang SI, Oh KS, Shin MS, *et al.* The influence of pedicle tension and twist on perforator flap viability in rats. *J Reconstr Microsurg* 2011;27:433-8.
6. Hamamoto Y, Nagasao T, Ensako T, Tanaka Y. Segmental marking: A new technique to prevent pedicle twisting. *J Plast Reconstr Aesthet Surg* 2015;68:873-4.
7. Khouri RK. Avoiding free flap failure. *Clin Plast Surg* 1992;19:773-81.
8. Panse N, Sahasrabudhe P. The tunneled perforator flap. *Indian J Plast Surg* 2012;45:158-9.
9. Yadav PS, Ahmad QG, Shankhdhar VK, Nambalindian GI. Pedicle transfer in oral cavity reconstruction. *J Plast Surg* 2010;43:79-80.
10. Moschella F, D'Arpa S, Di Lorenzo S, Cordova A. Safe pedicle tunnelling in maxillary reconstruction. *J Plast Reconstr Aesthet Surg* 2010;63:e289.
11. Theodorakopoulou M, Morrith AN, Jallali N. Salvage of a twisted end to side anastomosis with microvascular coupler. *J Plast Reconstr Aesthet Surg* 2014;67:e252-3.