

## Original Article

# Surgical revirgination: Four vaginal mucosal flaps for reconstruction of a hymen

**Hemant A. Saraiya**

Department of Plastic Surgery, Sushrut Plastic Surgery Research Center, Gujarat Cancer and Research Institute, Ahmedabad, Gujarat, India.

**Address for correspondence:** Dr. Hemant A. Saraiya, 10, Avanti Apartments, Bhagvan Nagar No Tekro, Paldi, Ahmedabad - 380 007, Gujarat, India. E-mail: drhemantsaraiya@hotmail.com

### ABSTRACT

**Introduction:** Over centuries, virginity has been given social, religious and moral importance. It is widely believed as a state of a female who has never engaged in sexual intercourse, and her hymen is intact. Hymenoplasty for torn hymen is carried out not only for the sake of cultural and religious traditions but also for the social status and interpersonal relationships. **Materials and Methods:** 2.5 cm long and 1 cm wide four vaginal mucosal flaps were raised from the anterior vaginal wall just behind labia minora. Two flaps were based proximally, and their two opposing flaps were based distally. These flaps were overlapped in a crisscross fashion and were sutured with 5/0 Polyglactin (Vicryl®) sutures leaving no area raw. The donor area was closed primarily. When some remains of a torn hymen were found, one to three vaginal mucosal flaps were added to its remains as per the need for reconstruction. **Results:** We operated upon 11 patients. In nine cases, the hymen was reconstructed with four flaps. In remaining two, it was reconstructed from the remains using vaginal mucosal flaps. All flaps healed without any infection or disruption. Sutures got absorbed in 25-35 days. In all cases, this newly constructed barrier broke with only moderate pressure at the time of penetrative sex serving the purpose of the surgery completely. **Conclusion:** Erasing evidence of the sexual history simply by 'Surgical Revirgination' is extremely important to women contemplating marriage in cultures where a high value is placed on virginity.

### KEY WORDS

Hymen; hymenoplasty; revirgination; vagina; vaginal mucosal flaps; virginity

### INTRODUCTION

According to English dictionaries, the term 'virgin' means 'a person who has never had sexual intercourse'. Virginity is a term that refers to

This is an open access article distributed under the terms of the Creative Commons Attribution-NonCommercial-ShareAlike 3.0 License, which allows others to remix, tweak, and build upon the work non-commercially, as long as the author is credited and the new creations are licensed under the identical terms.

**For reprints contact:** reprints@medknow.com

**How to cite this article:** Saraiya HA. Surgical revirgination: Four vaginal mucosal flaps for reconstruction of a hymen. Indian J Plast Surg 2015;48:192-5.

Access this article online	
Quick Response Code:	Website: www.ijps.org
	DOI: 10.4103/0970-0358.163060

something being pure, untouched and unexposed. The term hymen comes from the Greek god of marriage and weddings 'Hymenaeus'. According to societal norms, tearing of the hymen during intercourse is an indicator that the woman has never indulged in sexual activity and is termed as a virgin. In many cultures around the world, an unmarried female who is found not to be a virgin is a subject of shame and ostracism. In such societies, many a times women are imprisoned or executed (honour killing) for premarital sex.

The integrity of the hymen is tested either by physical examination before marriage or confirmed by the occurrence of vaginal bleeding resulting from tearing of hymen at the time of first sanctioned sexual contact. In some cultures, where displaying proof of a bride's virginity is customary, the nuptial blood-spotted bed sheet has to be exhibited as proof.

The term hymenorrhaphy or hymenoplasty is used for surgical restoration of the hymen.<sup>[1]</sup> In the present era apart from traditional requirements, women have various reasons for restoring their so-called 'virginity'.<sup>[2]</sup> Even though it is a controversial issue in many countries around the world, hymen reconstruction is now becoming a popular trend.

## MATERIAL AND METHODS

This was a prospective evaluation of eleven patients who underwent this procedure. All patients were explained the basic nature of the procedure and the implications.

### Procedure

The patient is placed in a lithotomy position. The procedure is carried out under spinal anaesthesia. 2.5 cm long and 1 cm wide rectangular flaps are marked at 2,

5, 8 and 11 o'clock position on the anterior vaginal wall. Flaps at 2 and 5 o'clock position are kept proximally based, and flaps at 8 and 11 o'clock positions are kept distally based or vice versa. Flaps are raised at the level of loose connective tissue below the mucosa. Donor areas are closed primarily. Opposing flaps are overlapped in a crisscross manner and sutured with 5/0 Polyglactin (Vicryl®) sutures leaving no raw area [Figures 1-4].

When some remains of a torn hymen are found, one to three vaginal mucosal flaps are added to its remains for reconstruction [Figure 5].

The patient is discharged on the same day. Antibiotic is given for 5 days. The patient is instructed to refrain from penetrative sex or not to carry out activities that can break her newly constructed hymen till her purpose of reconstruction is served.

## RESULTS

We operated upon 11 patients. In nine cases, the hymen was reconstructed with four flaps. In remaining two, it was reconstructed from the remains using vaginal mucosal flaps. All flaps healed without any infection or disruption. Sutures got absorbed in 25-35 days. In all cases, this newly constructed barrier broke with only moderate pressure at the time of penetrative sex serving the purpose of the surgery completely.

## DISCUSSION

The hymen, despite its etymological derivative, is a Mullerian duct remnant that is variable in shape.<sup>[3]</sup> The appearance can and will change with hormonal changes

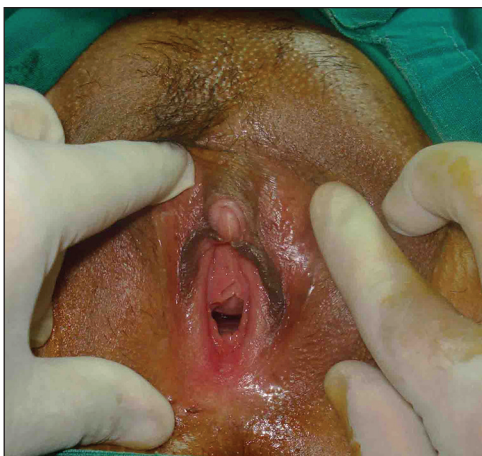


Figure 1: Vagina with torn hymen

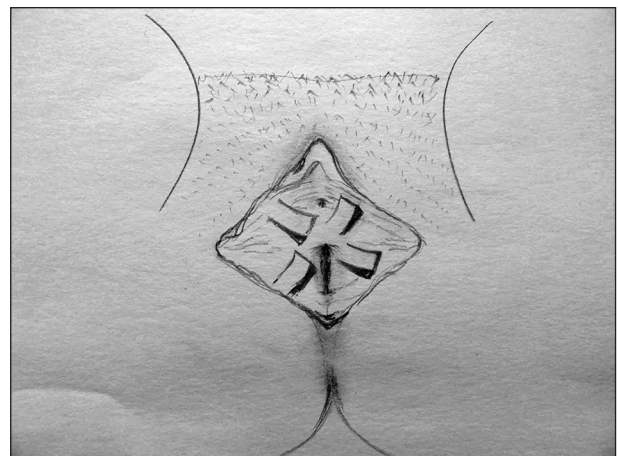


Figure 2: Flap planning sketch

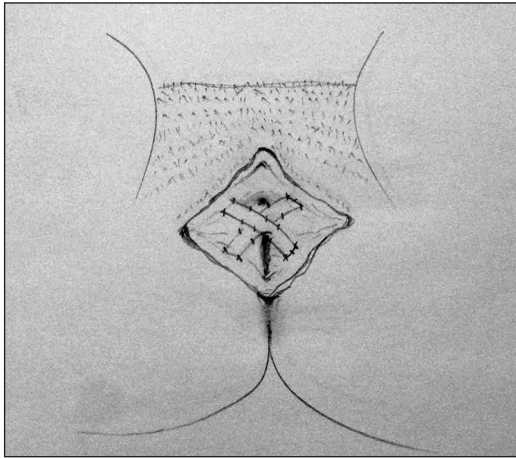


Figure 3: Flap execution sketch

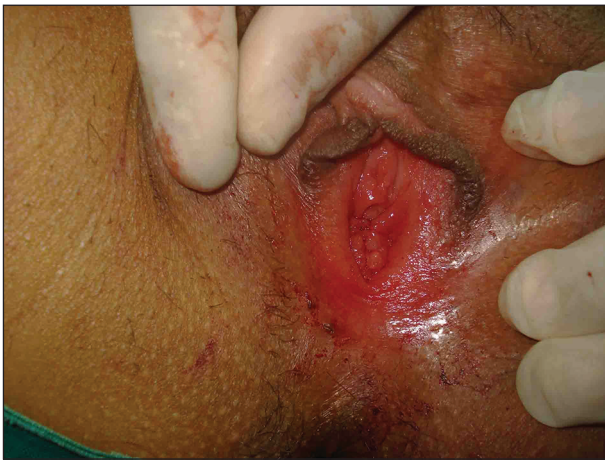

Figure 4: Hymenoplasty — post-operative

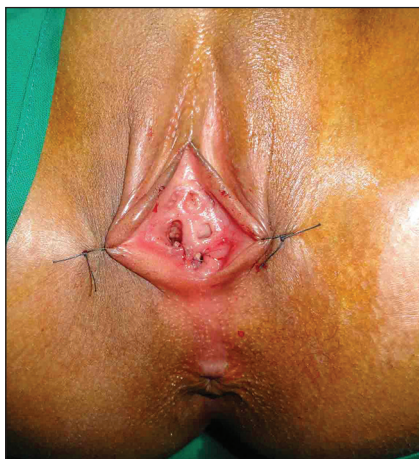

Figure 5: Hymenoplasty from remains — post-operative

and age; the hymen can become thin and in some instances, near transparent.

The hymen is a tissue that covers the external vaginal opening; it gets torn during penetrating sex. Apart from

penetrative sex, the hymen can get torn while carrying out activities such as gymnastics, horse riding, cycling or wearing a tampon. The absence of the hymen is associated with agenesis of vagina<sup>[4]</sup> whereas isolated total absence of the hymen is practically non-existent.<sup>[5]</sup>

Nonsurgical methods like creams containing herbal extracts and hydroxyethyl cellulose substances have been tried. On application to the vaginal walls, they allegedly cause swelling and tighten the vagina for the time being. Rupture of the hymen is mimicked by bleeding from the vaginal mucosa because of the friction. In another procedure, a small piece of plastic, embedded with red dye or a gelatin capsule of an artificial blood like substance is inserted into the vagina before sex. During intercourse discharge of this red fluid imitates rupture of hymen. Surgically hymen can be restored by suturing it back immediately after the rupture, or a new hymen can be recreated with the remains of the torn hymen at a later date.<sup>[6,7]</sup> Unfortunately, it is difficult to find the remains of hymen if it is not recently torn. The secondary repair tends to stay messy, weak and prone to give way prematurely. However, one to three vaginal mucosal flaps based on the design described above may be added to the remains of the hymen for reconstruction. This reconstructed hymen looks more natural, aesthetically.

The procedure described here is based on sound plastic surgery principles. It fulfils the basic aim of replacing 'like with like tissue'. Colour, texture and thickness practically match the original hymen. These random flaps are robust and reliable because of excellent vaginal mucosal blood supply. No incidence of necrosis or disruption was reported in our series. Mucosal flaps don't turn into a tube-like structure as opposing flaps are precisely overlapped and sutured, leaving no area raw on the flaps.

Vaginal mucosal laxity allows the donor areas to be closed primarily without any donor site morbidity. Although the procedure can be carried out under local anaesthesia with sedation, we prefer spinal anaesthesia as it provides better muscle relaxation and good comfort to the patient. We prefer Polyglactin (Vicryl®) sutures over chromic catgut sutures because of the unpredictability of absorption of chromic catgut. This technique is useful even for congenitally absent hymen.

Since the morphology of hymen, in practice, is extremely variable, it is presumptuous to say that the described hymen must assume a reticular morphology, an alleged norm of this structure. However, the procedure described

here creates a network-like thickened mucosal structure in and around the introitus. In our series, the purpose of the surgery was well served as the newly reconstructed hymen tore during the first sexual penetration in all operated patients. None of the patients complained of dyspareunia.

Over and above, the method is consistent, reproducible and repeatable if required. The newly reconstructed hymen is strong enough to sustain daily activities, but at the same time weak enough to get ruptured at the time of sexual penetration.

## CONCLUSION

Though some may term this as pseudo virgination or vaginal frauds, hymenoplasty is still an interesting, useful and rewarding procedure that saves women from social embarrassment and gives them a chance to enjoy the conformation of being a virgin all over again.

## Financial support and sponsorship

Nil.

## Conflicts of interest

There are no conflicts of interest.

## REFERENCES

1. Ahmadi A. Ethical issues in hymenoplasty: Views from Tehran's physicians. *J Med Ethics* 2014;40:429-30.
2. Goodman MP. Female cosmetic genital surgery. *Obstet Gynecol* 2009;113:154-9.
3. Heger A, Jean ES, David M. Evaluation of the Sexually Abused Child: A Medical Textbook and Photographic Atlas. 2<sup>nd</sup> ed. New York: Oxford University Press; 2000. p. 116.
4. Kimberley N, Hutson JM, Southwell BR, Grover SR. Vaginal agenesis, the hymen, and associated anomalies. *J Pediatr Adolesc Gynecol* 2012;25:54-8.
5. Mor N, Merlob P. Congenital absence of the hymen only a rumor? *Pediatrics* 1988;82:679-80.
6. Ou MC, Lin CC, Pang CC, Ou D. A cerclage method for hymenoplasty. *Taiwan J Obstet Gynecol* 2008;47:355-6.
7. Prakash V. Hymenoplasty — How to do. *Indian J Surg* 2009;71:221-3.