

Original Article

Objective analysis of microtia reconstruction in Indian patients and modifications in management protocol

Mohit Sharma, Raghuvveer Reddy Dudipala, Jimmy Mathew, Abhijeet Wakure, Krishnakumar Thankappan¹, Deepak Balasubramaniam¹, Subramania Iyer²

Departments of Plastic and Reconstructive Surgery, ¹Head and Neck Surgery and Oncology and ²Plastic and Reconstructive Surgery and Head and Neck Surgery and Oncology and Cranio-Maxillofacial Surgery, Amrita Institute of Medical Sciences, Kochi, Kerala, India

Address for correspondence: Dr. Mohit Sharma, Department of Plastic and Reconstructive Surgery, Tower 1, Floor no. 4, Amrita Institute of Medical Sciences, AIMS Ponekkara P.O., Kochi - 682 041, Kerala, India. E-mail: ammasmohit@gmail.com

ABSTRACT

Introduction: An ideal ear, with representation of all anatomic landmarks, is the aim of any reconstructive surgeon embarking on reconstructing the ear in a microtia patient. The literature is abundant with the description of techniques, but these have been reported mainly in Caucasian and Oriental population. There have been very few publications on results in the population belonging to the Indian subcontinent. In spite of strictly adhering to the recommended techniques of reconstruction, the results obtained in these patients have often been marred by problems that are not reported with the Oriental or Caucasian populations. This may necessitate a relook into the management strategy of these cases. Hindering the assessment of the results, their reporting and auditing the improvement obtained by such change in the management strategy, is the lack of a standardized method for assessment of the outcome. Hence, an attempt was made in a series of patients who underwent microtia reconstruction to assess the outcome using a new tool based on the attained definition of anatomical components of the reconstructed pinna. Further effort was made to document the modifications in the technical execution of the reconstruction during the period of the study. **Materials and Methods:** A retrospective review of 44 patients and a prospective analysis of 11 patients, who underwent ear reconstruction for microtia from December 2003 to September 2014 at a tertiary care teaching hospital, was undertaken. Taking a cue from Nagata's description of an 'ideal reconstructed ear' which should show all the anatomical components, we developed an objective grading system to assess our results. The technique had undergone several changes during these years combining the principles of three universally accepted methods, that is, those described by Nagata, Brent, and Firmin. These changes, as well as the reasons behind them, were documented. **Results:** On objectively measuring and analysing the replication of normal morphologic characteristics of the reconstructed ears, we documented progressive improvement of our results. Good or excellent results could be achieved in 70% of cases in the second group compared

This is an open access article distributed under the terms of the Creative Commons Attribution-NonCommercial-ShareAlike 3.0 License, which allows others to remix, tweak, and build upon the work non-commercially, as long as the author is credited and the new creations are licensed under the identical terms.

For reprints contact: reprints@medknow.com

How to cite this article: Sharma M, Dudipala RR, Mathew J, Wakure A, Thankappan K, Balasubramaniam D, *et al.* Objective analysis of microtia reconstruction in Indian patients and modifications in management protocol. *Indian J Plast Surg* 2015;48:144-52.

Access this article online	
Quick Response Code:	Website: www.ijps.org
	DOI: 10.4103/0970-0358.163050

to a poor outcome in more than 2/3rd of the cases carried out during the initial period. Based on these results and the changes adopted in our practice we propose suggestions for management of microtia cases in the Indian population. **Conclusions:** An objective, weighted grading system has further enabled us to critically evaluate the outcomes and to further improve upon the existing results. Our amalgamation of the salient features of the established techniques as well as changes made based on our experience has enabled us to get good results more consistently in our attempts at microtia reconstruction. We believe that the adoption of such amalgamated methods will be more suitable in Indian patients.

KEY WORDS

Grading system for microtia reconstruction; microtia; microtia in subcontinent population; objective grading of microtia

INTRODUCTION

An ideal ear^[1] representing all the anatomic landmarks is the desired result every reconstructive surgeon strives to achieve in cases of microtia. This relatively common deformity is a reconstructive challenge as it is difficult to replicate the complex three-dimensional anatomy of the ear and produce lasting results. The technique of microtia correction has evolved over the years with Tanzer^[2] introducing the reconstruction with autologous costal cartilage, followed by the pioneering efforts of Brent,^[3,4] Nagata^[5-13] and subsequently Firmin and Marchac.^[14] The nature of the skin definitely plays a key role in determining the outcome of these reconstructions and as such, results may be subject to racial variations.^[15,16] The description of techniques has been mainly in Caucasian and Oriental population. There have been very few publications depicting the results in the population of the Indian subcontinent.^[17,18] In spite of strictly adhering to the recommended techniques of reconstruction, the results have often been marred by problems that are not reported with the Oriental or Caucasian populations. Hence, it may be prudent to tailor these techniques to suit the Indian patients. Furthermore, there is a need for objective assessment of the outcome of treatment to analyse and report the efficacy of different techniques from different centres. Such an analytical tool has been lacking in literature.

Aims and objectives

- To discuss the issues leading to suboptimal results of reconstruction of microtia in a cohort of Indian patients.
- To describe the measures to overcome such issues.
- To develop an objective grading system for outcome assessment.

MATERIALS AND METHODS

Taking a cue from Nagata's description of an 'ideal reconstructed ear' which should show all the anatomical components, we developed an objective grading system to assess our results of microtia reconstruction [Table 1]. A retrospective review of 44 patients, who underwent ear reconstruction for microtia from December 2003 to September 2012, was undertaken using the assessment tool. During this time the technique changed to a combination of the three universally accepted methods, that is, Nagata, Brent and Firmin techniques. The suboptimal results in a large majority of our cases prompted us to have a relook into our strategy of reconstruction of microtia. We believed that the behaviour of the Indian patients to the techniques described was different from those of the Caucasian or Asian patients in whom these were carried out. We made some changes in our approach towards reconstruction, which yielded better results in the subsequent series of 11 patients operated from September 2012 to September 2014.

RESULTS

By the time, we formulated our grading system we had already performed 44 ear reconstructions, which we analysed retrospectively, and the subsequent 11 were evaluated prospectively.

Of the 44 initial cases, 28 (63%) had poor to average outcomes. The main issue was resorption of the framework in varying proportions. At times, a framework which had been otherwise very good, had resorbed significantly with the passage of time [Figure 1]. The technique of primary lobule transposition did not have a consistently good outcome in our series. Use of different suture materials

Table 1: Weighted grading system for microtia reconstruction

Anatomical attribute	Score
Helix	
a. Crus of helix	1
b. Upper 1/3 rd	1
c. Middle 1/3 rd	1
d. Lower 1/3 rd	1
Anti-helix	
a. Superior and inferior crus	1
b. Middle part	1
c. Anti-tragus	1
Tragus	1
Lobule	1
Scaphoid fossa	1
Triangular fossa	1
Cymba concha	1
Cavum concha	1
Total (maximum) score	13

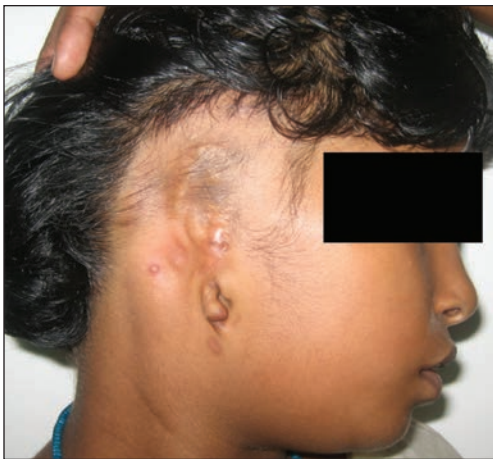

Figure 1: Framework resorption

for the cartilage framework yielded inconsistent results. However, after we brought in the modifications to the established techniques to cater to the native needs we were able to achieve excellent outcomes in about 70% (8 out of 11) of our patients. These steps included delaying the reconstruction, allowing for cartilage maturation, combining some aspects of all the three methods that is, Nagata, Firmin and Brent, and the use of additional techniques like triamcinolone injections and cartilage augmentation. Based on our experience we propose the optimal steps and guidelines for microtia reconstruction in Indian patients.

DISCUSSION

Microtia reconstruction is one of the surgical procedures that has undergone vast changes preserving the primary concept evolved by Tanzer^[2] and later on expounded by

Brent.^[3,4] Using costal cartilage framework and staging the reconstruction remains the best method available giving consistent and long lasting good outcomes compared to other methods like the use of synthetic implants and rehabilitation based on osseo-integrated implants. This method has been modified several times over the last few decades based on personal experiences. The contributions that have significantly influenced the way microtia reconstructions are practiced currently have been from Nagata^[5-13] and Firmin and Marchac.^[14] Nagata's method is unique because it is through his work that the concept of getting all the anatomical parts of the ear was given importance in the final definition of the reconstructed pinna. He also introduced the concept of single stage transfer of the lobule of the ear. Firmin and Marchac^[14] on the other hand combined the principles expounded by both Nagata and Firmin^[19] added their own contributions like the use of Sure elevation technique to enhance the tragal projection in which the cartilage strut used for tragal reconstruction is attached on the under-surface of the root of the helix making the framework inherently more stable and conspicuous.

Addition of a third layer under the framework enhances the definition of the conchal bowl and tragus. The timing of the surgery has been generally reported to be between 8 and 10 years or attaining a chest circumference of 60 cm at the Xiphisternum.^[19,20]

The technique adopted at our centre has also been undergoing refinements and changes periodically, with the gain of more experience and knowledge from published literature as well as surgical workshops. However, we thought of systematically analysing our results and grading them as an internal audit. Since we could not find a method in the published literature to do such an analysis we devised a simple score, based on points being attributed to each of the anatomical landmarks that have to be visible in a reconstructed ear. Depending on the importance of this anatomical landmark, weighted scores were assigned. The salient steps adopted at our centre along with the logic behind few of the changes are discussed further.

Stages of reconstruction

Combining the Nagata and Brent techniques we have formulated a three-stage reconstruction protocol:

- Stage I: Framework fabrication and placement
- Stage II: Lobule transposition
- Stage III: Framework elevation.

Lobule transfer

Initially, we had been adopting a staged lobule transposition. But, for some period, we adopted the primary lobule transfer as described by Nagata. However, the number of cases having necrosis of the skin edges was high (three out of four) [Figure 2]. The reason could be increased tension along the suture line that occurs in a primary lobule transposition and inadequate vascular supply to the conchal skin flap on account of a small subcutaneous tissue pedicle. This was carried out at the time when we were adding more layers to the framework for better definition, which may have added to the ischemic stress on the wound edges.

Age of reconstruction

Initially, we started the first stage of reconstruction by the age of 8 years (as recommended by Brent). But in our analysis, we found that a large number of these young children lost the definition of the framework (18).

This higher tendency for resorption may be attributed to the racial variations in the quality and sturdiness of the cartilage in our children. The increased thickness of the Indian skin may also play a role in this, as the pressure exerted on the framework may be higher. Hence, we delayed the reconstruction in a few patients to a later age of 10 years. Although it gave excellent on-table results, within 6 months, the frameworks showed signs of resorption. At present, we achieve better results when we initiate the reconstruction at the age of 12-13 years. It is difficult to convince the anxious parents for this longer waiting period, but we strongly feel that delaying the reconstruction in our patients gives better long-term outcomes [Figure 3]. We have encountered ossification of the cartilage while doing it in adults. In these cases, we had to resort to the use of a powered burr in areas of

ossification while carving the framework. To prevent heat damage to the cartilage, the carving was done by keeping the framework submerged in a saline bath.

Harvesting the costal cartilage

Brent harvests the cartilage extra-perichondrially and retains the margin of the 6th costal cartilage to prevent chest wall deformity.^[19] Nagata on the other hand, harvests the cartilage sub-perichondrially and reposes the chunks of the extra cartilage using a funnel.^[20] We harvest the ipsilateral 6th, 7th, 8th and 9th costal cartilages, leaving only the posterior layer of peri-chondrium behind. This perichondrial tethering prevents splaying of the ribs, helps in regeneration of the costal cartilage to some extent and prevents chest wall deformity [Figures 4 and 5]. This method is technically easier and by not breaching the posterior perichondrial layer, we were able to avoid pleural tears in all our patients.

Fabrication of framework

Without creating the third layer of the framework underneath, it is not possible to create a conchal bowl. So, we create a minimum of a three-layered construct to enhance the definition as originally described by Firmin.^[21] We have also made an alteration to the framework creation technique by carving the tragus from a single long piece of cartilage and fixing it at two points. This gives a more definitive projection and conspicuous position to the tragus [Figures 6 and 7]. This forms a closed ring structure, which is inherently more stable, allows easier draping of the skin to accentuate the conchal bowl.

Choice of sutures for creating the framework

Even though stainless steel wires had been used by Nagata and Firmin for a long time, we had resorted

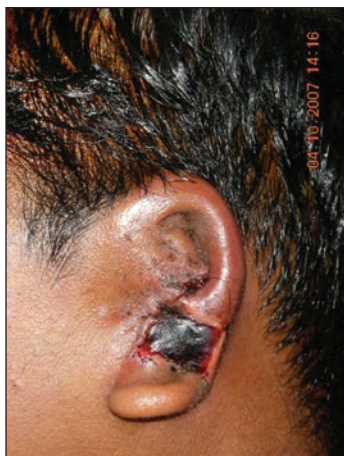

Figure 2: Skin necrosis in primary lobule transfer

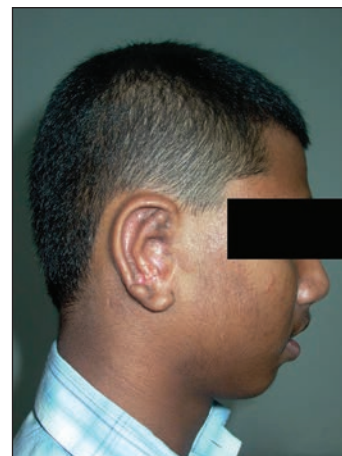

Figure 3: Delayed reconstruction providing stable and lasting results

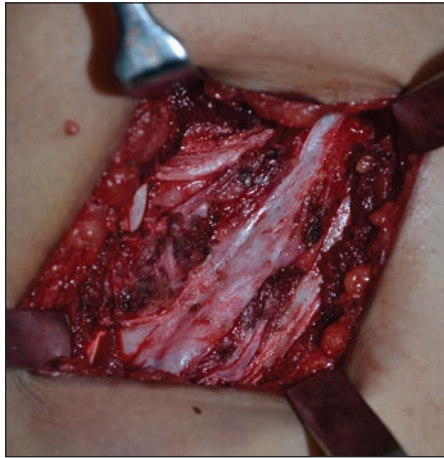


Figure 4: Cartilage harvest

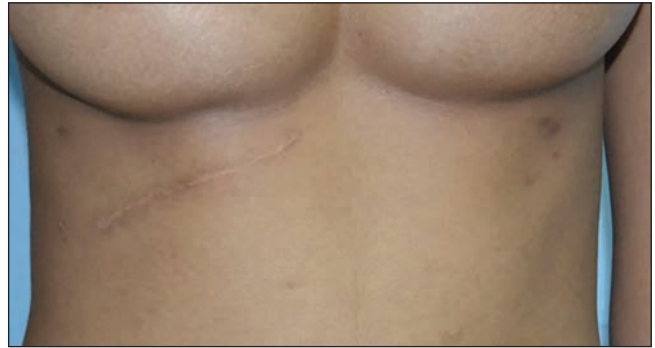

Figure 5: Good chest wall contour

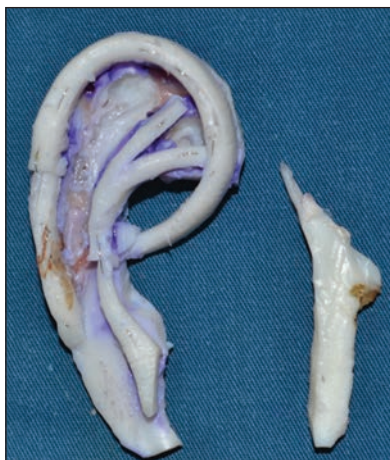

Figure 6: Creation of tragus from a single piece of cartilage

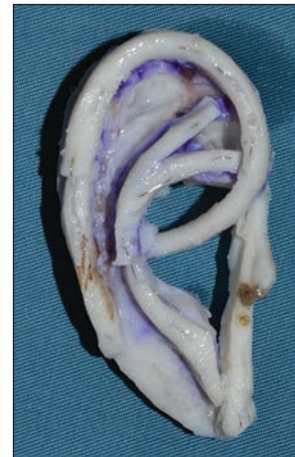


Figure 7: Two point tragal fixation

to the use of 4-0 polypropylene, 3-0 polydioxanone for suturing the framework components. This was necessitated by the lack of availability and the prohibitive cost of the stainless steel wire sutures. We also tried to use thin dental wires looped onto eyed needles in few cases, but we found that the larger needle of suture materials cuts through the delicate framework components. There have been instances of a shift in the position of the framework components after placement in the pocket while using polypropylene and polydioxanone. The self-fabricated steel wires were difficult to manage and had inherent problems of undue thickness of the wires as well as needles. The commercially available stainless steel wires provide excellent stabilization of the components of the cartilage framework. The protruding wires on the under-surface of the framework act like barbs and help in preventing the movement of the construct by anchoring it to the underlying soft tissues. It also allows us to join even the small components in

a reliable fashion enabling us to achieve a superior quality framework.

Enhancing the definition of framework in patients with thicker skin

We found that the Brent type framework did not show a good definition (probably due to the thicker Indian skin). Hence, we shifted to the Nagata type framework, which is sturdier (3-4 layers). Even then, the details become less apparent after the elevation of the framework. To overcome this problem we created uniformly thin pockets ascertained by trans-illumination of the skin [Figure 8]. In two patients where the desired definition was not achieved even after using a three-layered construct, we injected 10 mg of triamcinolone acetonide subdermally after 3 months of Stage I of the reconstruction.^[22]

We routinely bank excess cartilage subcutaneously in the chest. This is utilised for framework elevation during the second stage of reconstruction. This may also be used to augment some portion of the framework if there is a loss of definition, by tunnelling a separate piece of cartilage over the existing framework [Figures 9-11].

Maintaining suction in the immediate post-operative period

We were using routine closed vacuum suction tubes. The issues of periodic loss of suction and subsequent hematoma/seroma collection were high due to the

incessant clogging. This could be mitigated to a great extent by the use of flat silicone suction drains [Figures 12 and 13]. These are brought out through a long subcutaneous tunnel, which created a natural tissue seal. Use of cyanoacrylate tissue adhesive to seal off the suture line also helps as a good adjunct [Figure 14].

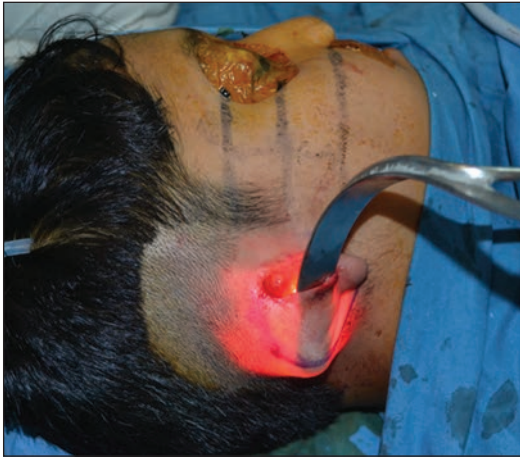

Figure 8: Uniformly thin pockets ascertained by trans-illumination

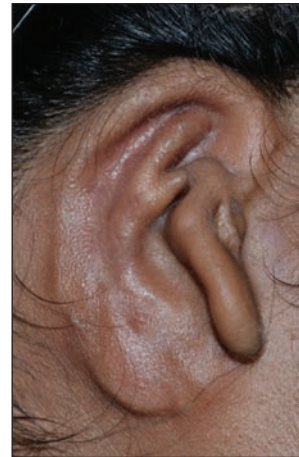

Figure 9: Framework after Stage I necessitating augmentation

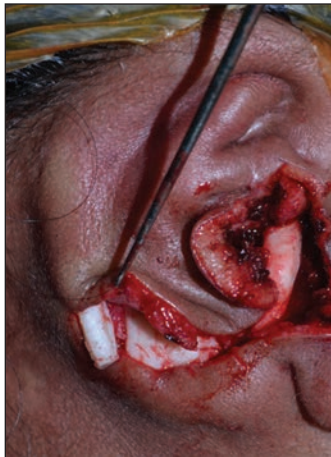

Figure 10: Augmentation of framework by banked cartilage

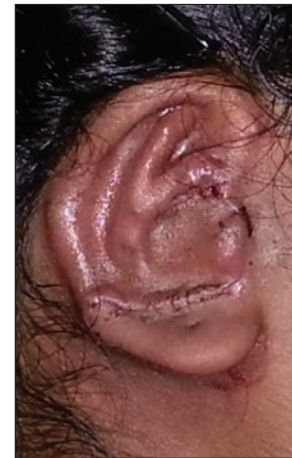

Figure 11(a): Augmented framework

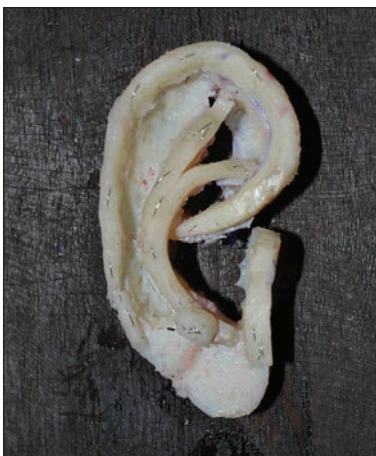

Figure 11(b): Completed framework

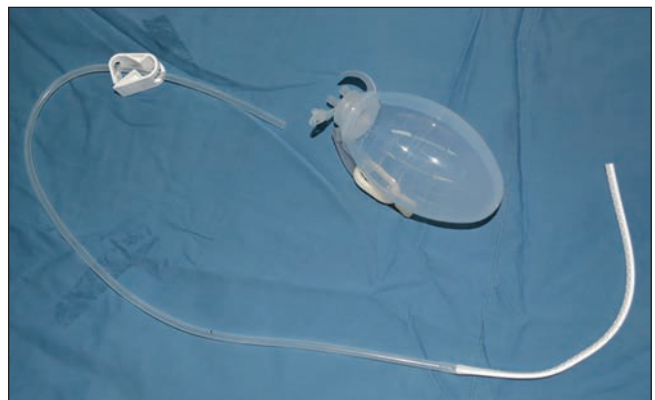

Figure 12: Silicone suction drain

Framework elevation

We support the elevated framework with a cartilage piece, which has been previously banked subcutaneously in the chest wall and cover it with a post auricular galeal turnover flap, over which a contralateral post auricular or groin full thickness skin graft is placed and secured with a tie over dressing [Figures 15 and 16].

Management of low hairline

We had tried using different techniques for managing the low hairline. This included LASER therapy or excision of the hair-bearing area during the framework elevation and extending the skin graft to cover this area. At present, we use LASERS either during the pre-reconstruction phase or after framework implantation [Figures 17 and 18].

Objective assessment of the outcomes

To the best of our knowledge, there is no scoring system to objectively assess the outcomes of different techniques of ear reconstruction amongst various ethnic groups.

So, taking a cue from Nagata's concept of an 'ideal' reconstructed ear, which should show all the anatomic landmarks, we developed a 'weighted — grading' system. The helix is given the maximum weightage with 4 points on account of its four anatomical subdivisions, the antihelix 3 points and the other attributes 1 point each to attain a total score of 13 points [Table 1]. Further on, we graded the results as poor, average, good and excellent based on the total score [Table 2]. Based on these criteria, we were able to objectively assess our outcomes [Figures 19-23].

This system can be criticised due to the perceptible subjective variability that can occur between different observers. Still, we believe that such a system will allow a better analysis of the reconstruction outcomes across different centres.

CONCLUSIONS

An objective, weighted grading system has further enabled us to critically evaluate the outcomes and to

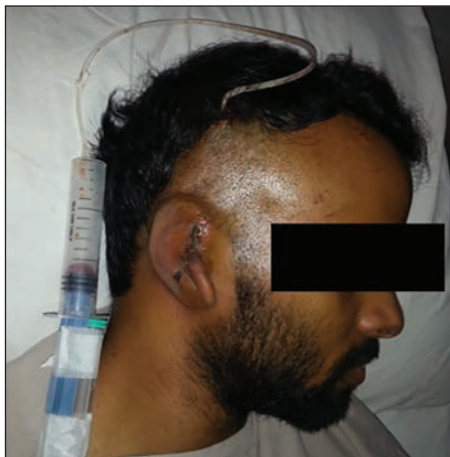

Figure 13: Suction drain brought out through a long subcutaneous tunnel

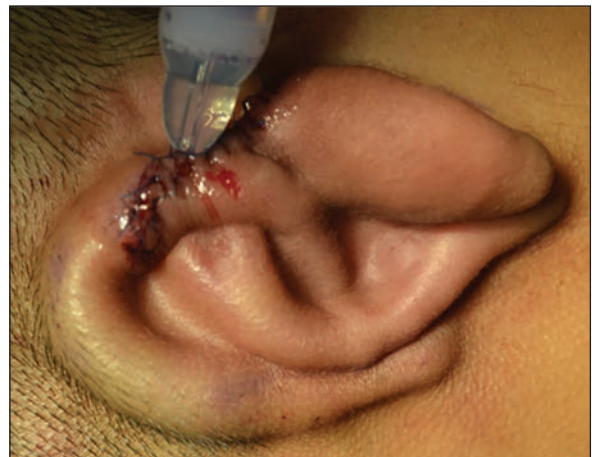

Figure 14: Cyanoacrylate tissue adhesive to seal off the suture line

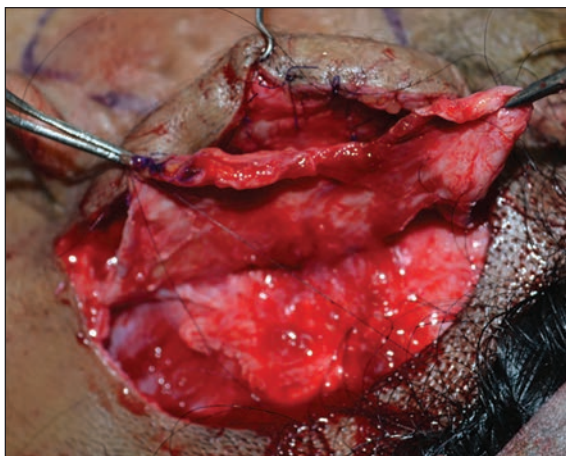


Figure 15: Post auricular galeal turnover flap

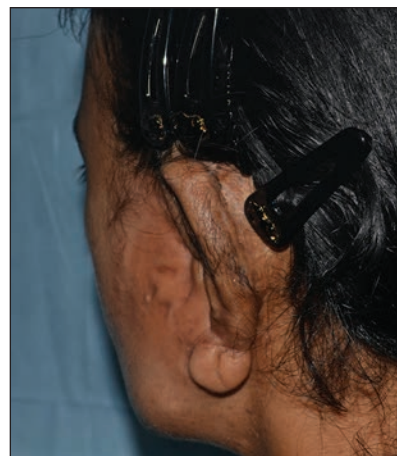

Figure 16: Contralateral post auricular full thickness skin graft

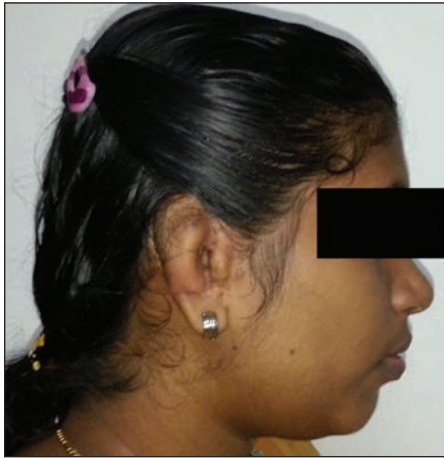

Figure 17: Low hairline - prior to LASER therapy

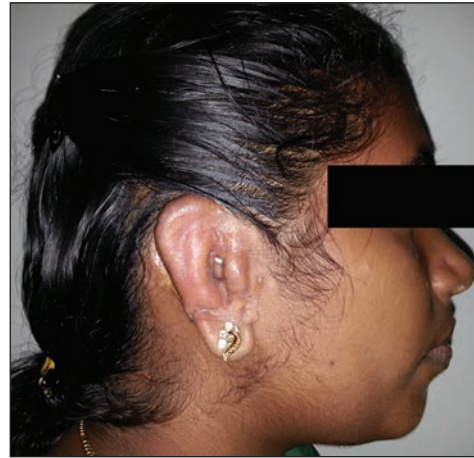

Figure 18: Low hairline — post LASER therapy

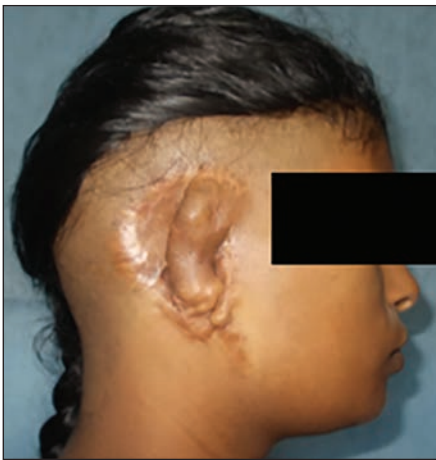

Figure 19: Poor result

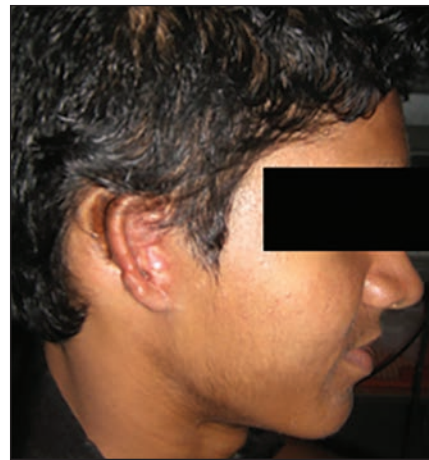

Figure 20: Average result

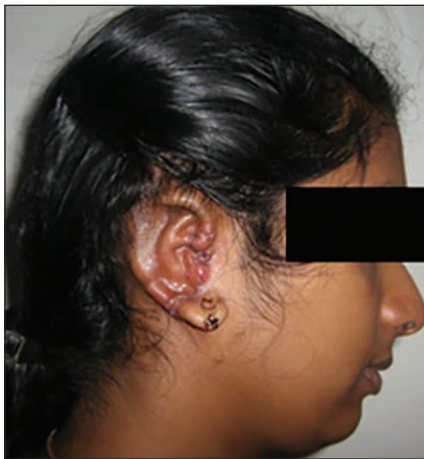

Figure 21: Good result

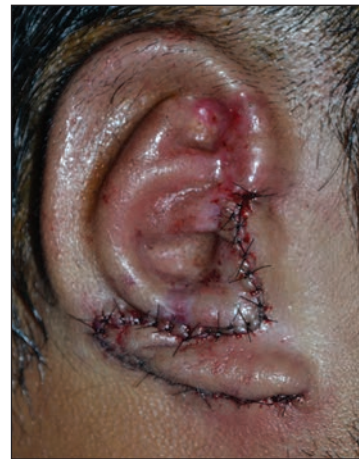

Figure 22: Excellent result

improve upon the existing results. Our adoption of different techniques and modifying them to suit the needs of Indian patients has started to give us more acceptable outcomes. Resorption of the cartilage, skin necrosis in single stage lobule transposition, difficulty to

attain good definition due to increased thickness of the skin have been few of the issues facing us in microtia reconstruction. Few of the notable changes that we have adopted to get better outcomes include delaying the initiation of reconstruction, transferring the lobule in

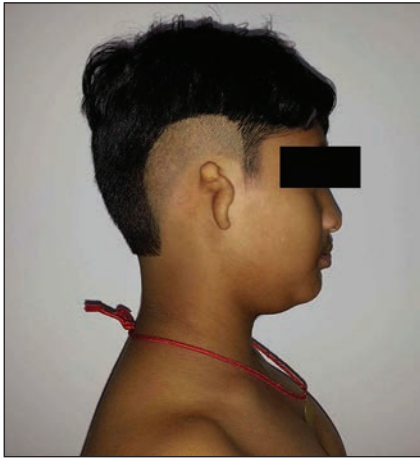

Figure 23(a): Excellent result — Pre-op

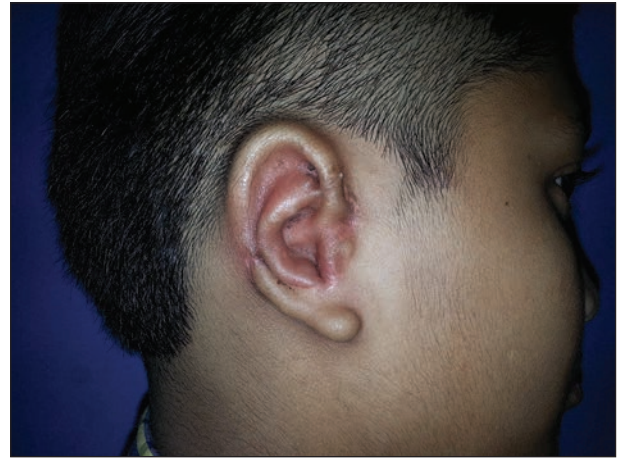

Figure 23(b): Excellent result — Post op

Table 2: Grading system for microtia reconstruction

Total score	Grade
1-5	Poor
6-8	Average
9-11	Good
12-13	Excellent

the second stage, using a three-dimensional closed loop framework.

Financial support and sponsorship

Nil.

Conflicts of interest

There are no conflicts of interest.

REFERENCES

1. Tolleth H. Artistic anatomy, dimensions, and proportions of the external ear. *Clin Plast Surg* 1978;5:337-45.
2. Tanzer RC. Total reconstruction of the external ear. *Plast Reconstr Surg Transplant Bull* 1959;23:1-15.
3. Brent B. The correction of mi-rotia with autogenous cartilage grafts: I. The classic deformity? *Plast Reconstr Surg* 1980;66:1-12.
4. Brent B. The correction of microtia with autogenous cartilage grafts: II. Atypical and complex deformities. *Plast Reconstr Surg* 1980;66:13-21.
5. Nagata S. A new reconstruction for microtia of the lobule. *Jpn Plast Reconstr Surg* 1989;32:931.
6. Nagata S. A new method of total reconstruction of the auricle for microtia. *Plast Reconstr Surg* 1993;92:187-201.
7. Nagata S. Modification of the stages in total reconstruction of the auricle: Part I. Grafting the three-dimensional costal cartilage framework for lobule-type microtia. *Plast Reconstr Surg* 1994;93:221-30, 267.
8. Nagata S. Modification of the stages in total reconstruction of the auricle: Part II. Grafting the three-dimensional costal cartilage framework for concha-type microtia. *Plast Reconstr Surg* 1994;93:231-42.
9. Nagata S. Modification of the stages in total reconstruction of the auricle: Part III. Grafting the three-dimensional costal cartilage framework for small concha-type microtia. *Plast Reconstr Surg* 1994;93:243-53, 267.
10. Nagata S. Modification of the stages in total reconstruction of the auricle: Part IV. Ear elevation for the constructed auricle. *Plast Reconstr Surg* 1994;93:254-66.
11. Nagata S. Secondary reconstruction for unfavorable microtia results utilizing temporoparietal and innominate fascia flaps. *Plast Reconstr Surg* 1994;94:254-65.
12. Nagata S. Total auricular reconstruction with a three-dimensional costal cartilage framework. *Ann Chir Plast Esthet* 1995;40:371-99.
13. Rohrich RJ, Hoxworth RE. Auricular reconstruction: Congenital auricular defects-Microtis. In: Guyuron B, Eriksson E, Persing JA, *et al.* editors. *Plastic Surgery Indications and Practice*. Philadelphia: Saunders Elsevier; 2009. p. 671-99.
14. Firmin F, Marchac A. A novel algorithm for autologous ear reconstruction. *Semin Plast Surg* 2011;25:257-64.
15. Kim MM, Byrne PJ. Facial skin rejuvenation in the Asian patient. *Facial Plast Surg Clin North Am* 2007;15:381-6, vii.
16. Rawlings AV. Ethnic skin types: Are there differences in skin structure and function? *Int J Cosmet Sci* 2006;28:79-93.
17. Jain S, Kumar P, Bariar LM. Total auricular reconstruction with autogenous costal cartilage framework for congenital microtia (grade-III). *Indian J Otolaryngol Head Neck Surg* 2002;54:188-92.
18. Chauhan DS, Guruprasad Y. Auricular reconstruction of congenital microtia using autogenous costal cartilage: Report of 27 cases. *J Maxillofac Oral Surg* 2012;11:47-52.
19. Firmin F. State of the art autogenous ear reconstruction in cases of microtia. In: Staudenmaier R (Ed), editor. *Aesthetics and functionality in ear reconstruction*. Basel, Karger 2010;68:25-52.
20. Nagata S. Auricular reconstruction: Congenital auricular defects — Microtia. In: Guyuron B, Eriksson E, Persing J, editors. *Plastic Surgery: Indications and Practice*. Philadelphia: Saunders Elsevier; 2008.
21. Thorne CH. Ear reconstruction. In: Thorne CH, editor. *Grabb & Smith's Plastic Surgery*. 7th ed. Philadelphia: Lippincott, Williams & Wilkins; 2014.
22. Bhandari PS. Use of triamcinolone acetone injection in ear reconstruction. *Ann Plast Surg* 2000;45:458-61.